Subject: General Histology for Second year Students of Dentistry Department

Credits Units: 4

Theory Lecture: 2hrs

Practical Lab: 2 hrs

Dr. Ibtesam Radhi Thammer

PhD in Applied Embryology

From Aston University in UK

Course Overview

The principal objective of this course is to provide students with an understanding of the structural and functional organization of the human body at the cellular and subcellular levels.

Histology: is the study of the tissues of the body and how these tissues are arranged to constitute organs.

Tissues and Cells

Tissues have two interacting components: cells and extracellular matrix (ECM).

The ECM consists of many kinds of macromolecules, most of which form complex structures, such as collagen fibrils.

Function of ECM

1- The ECM supports the cells and contains the fluid transporting nutrients to the cells,

2- Carrying away cells wastes and secretory products. During development, cells and their associated matrix become functionally specialized and give rise to fundamental types of tissues with characteristic structural features. Organs are formed by an orderly

combination of these tissues, and their precise arrangement allows the functioning of each organ and of the organism as a whole.

Preparation of Tissues for Study

The most common procedure used in histologic research is the preparation of tissue slices or "sections" that can be examined visually with transmitted light.

Types of

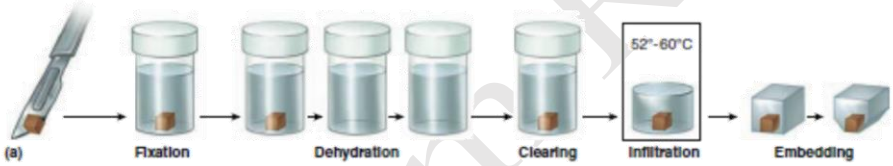

Microscopes to observe histological tissue slides

1- Light Microscopy

2- Fluorescence Microscopy

3- Phase-Contrast Microscopy (Inverted Microscopy)

4- Confocal Microscopy

5- Electronic Microscopy



Figure 1: Light Microscope.

Figure 2: Electron Microscope

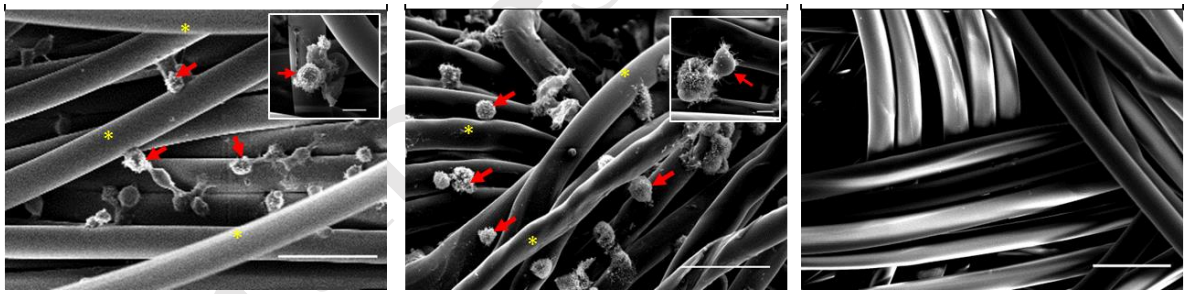

Figure 3: Scanning Electron Microscope.

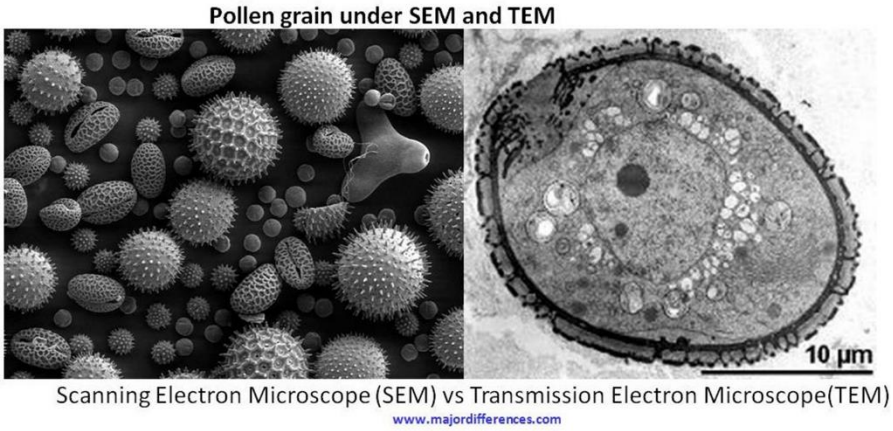

Figure 4: Scanning Electron Microscope.

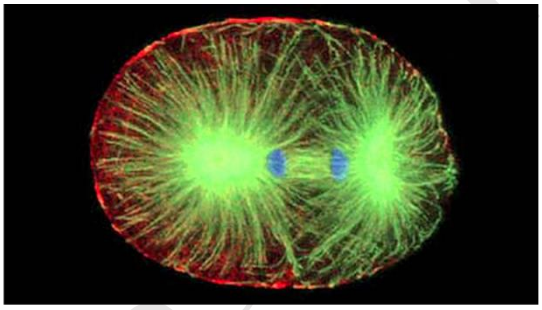

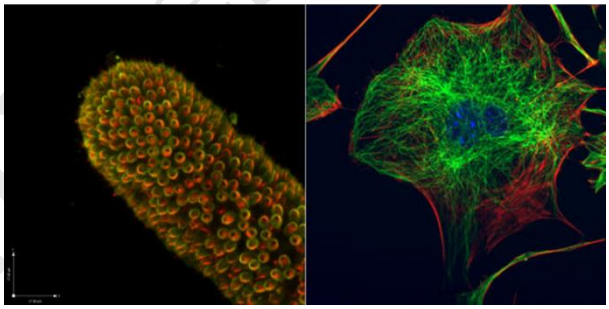

Figure 5: Confocal Microscope.

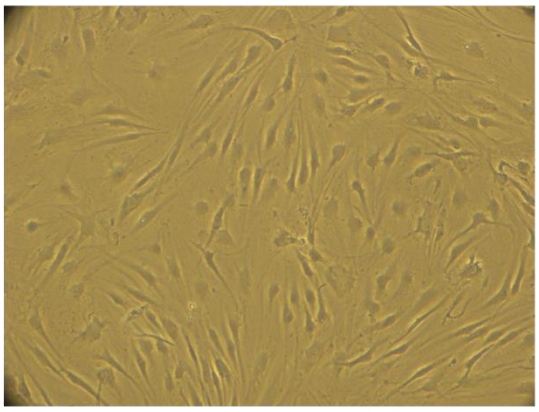

Figure 6: Inverted Microscope

Types of Tissues

Despite its complexity, the organs of the human body are composed of only four basic tissue types:

1- Epithelial Tissue

2- Connective Tissue

3- Muscular Tissue

5- Nervous Tissue.

Epithelial Tissues

The principal functions of epithelial tissues include the following:

■ Covering, lining, and protecting surfaces (eg, epidermis)

■ Absorption (eg, the intestinal lining)

■ Secretion (eg, parenchymal cells of glands)

Types of Epithelial Tissues

Epithelial tissues can be classified based on two criteria:

1- Based on function

A- Covering (or lining) epithelia

B- Secretory (glandular) epithelia

2- Based on cell layers and the cell morphology in the outer layer.

1- Simple epithelium

A- Simple sequamous epithelium

B- Simple Cuboidal epithelium

C- Simple columnar epithelium

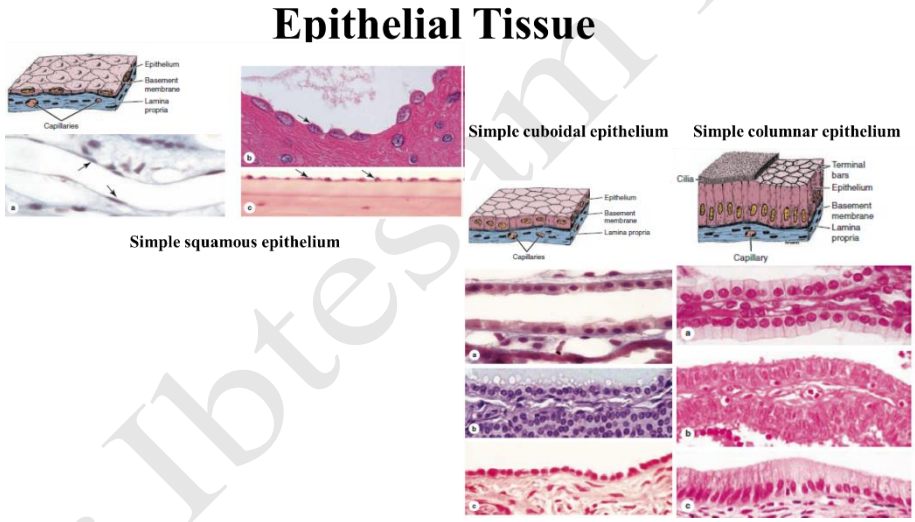

2- Stratified epithelium

A- Stratified sequamous epithelium

1- Keratinized sequamous epithelium

2- Non-keratinized sequamous epithelium

B- Stratified Cuboidal epithelium

C- Stratified columnar epithelium

D- Transitional epithelium

E- Pseudostratified columnar epithelium

Epithelial Tissue

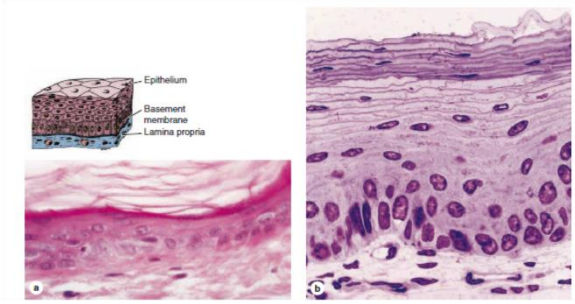

Stratified squamous epithelium

Epithelial Tissue

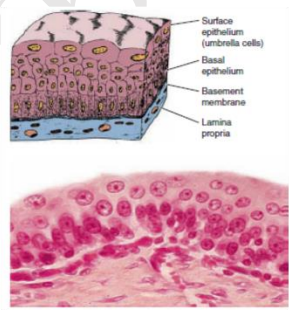

Transitional epithelium

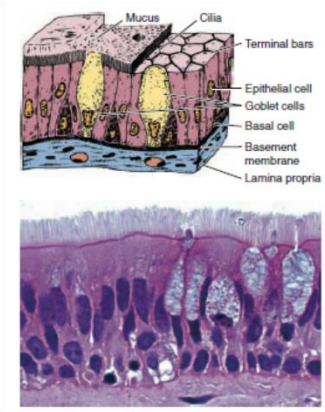

Pseudostratified columnar epithelium

Connective Tissues

Connective tissue provides a matrix that supports and physically connects other tissues and cells together to form the organs of the body. Connective tissue provides support, binds together, and protects tissues and organs of the body.

Connective tissue consists of three main components: cells, protein fibers, and an amorphous ground substance. Together the fibers and ground substance make up the extracellular matrix.

The three types of connective tissue fibers are:

1- Collagen fibers - most are type I collagen (most abundant protein in the body)

2- Elastic fibers - contain elastin and fibrillin Elasticity - can be stretched, yet still, return to its original length

3- Reticular fibers - contain type III collagen Support - network of thin fibers

Connective tissue is classified based on the characteristics of its cellular and extracellular components. The main criteria are the type of cells, arrangement and type of fibers, and composition of the extracellular matrix.

A- Connective Tissue Proper

1- Loose Connective Tissue also called areolar tissue

2- Dense connective tissues

A- Dense Regular Connective Tissue

B- Dense Irregular Connective Tissue

4- Adipose tissue

5- Bone and cartilage

6- Blood

Lecture tittle: The circulatory system for Second year Students of Dentistry Department

Credits Units: 4

Theory Lecture: 2hrs

Practical Lab: 2 hrs

Dr. Ibtesam Radhi Thammer

PhD in Applied Embryology

From Aston University in UK

Lecture tittle: The circulatory system

Aims of this lecture:

1- Recognize features in the heart (such as cardiac muscle, valves, cardiac skeleton) that allow it to serve as a pump.

2- Be able to distinguish successive parts of the circulatory pathway, and explain how the structure of the vessel wall meets the functional needs that are present in each of the parts.

3-Be able to distinguish the structural layers of each part of circulatory system.

The circulatory system

The circulatory system includes both the blood and lymphatic vascular Systems. The circulatory system pumps and directs blood cells and substances carried in blood to all tissues of the body. The blood vascular system, or cardiovascular system, consists of the following structures (Figure 1):

1- The heart

2- Arteries

3- Veins

4- Capillaries

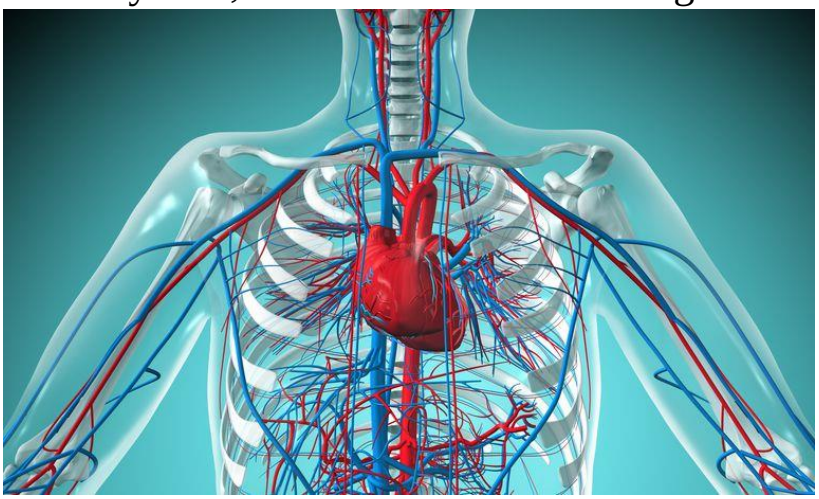

Figure 1: Image shown the heart and blood vessels

Structures and function of the heart

The heart is located in the mediastinum; about two-thirds of its mass is to the left of the midline. It is shaped like a cone lying on its side. Its apex is the pointed, inferior part. While, its base is the broad, superior part. The heart has four chambers. The two superior receiving chambers are the atria, and the two inferior pumping chambers are the ventricles. Main function of the heart is to pump blood throughout the body (Figure 1&2).

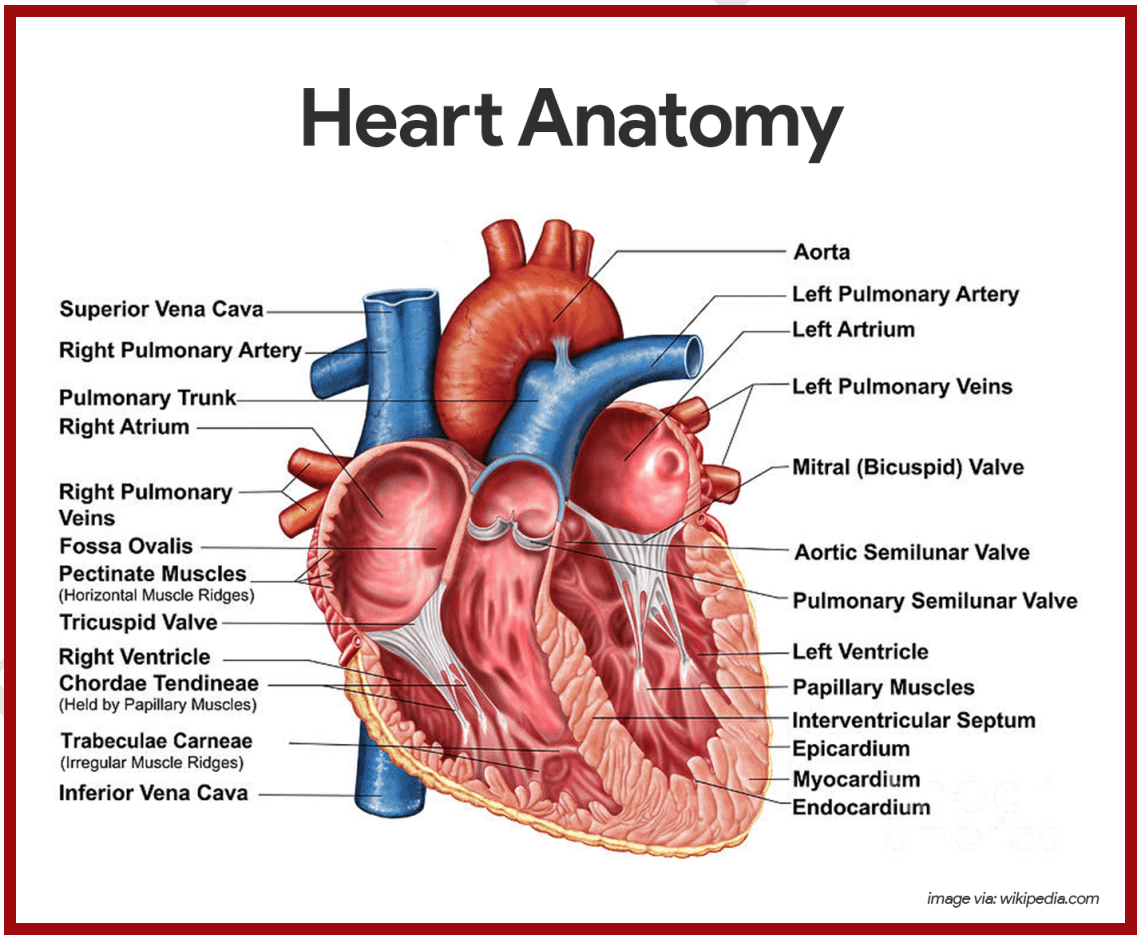

Figure 2: Image shown the anatomy of heart

The walls of all four heart chambers consist of three major layers: the internal endocardium; the middle myocardium; and the external epicardium. The main function of blood vessels is to conduct blood away and to the heart (Figure 3).

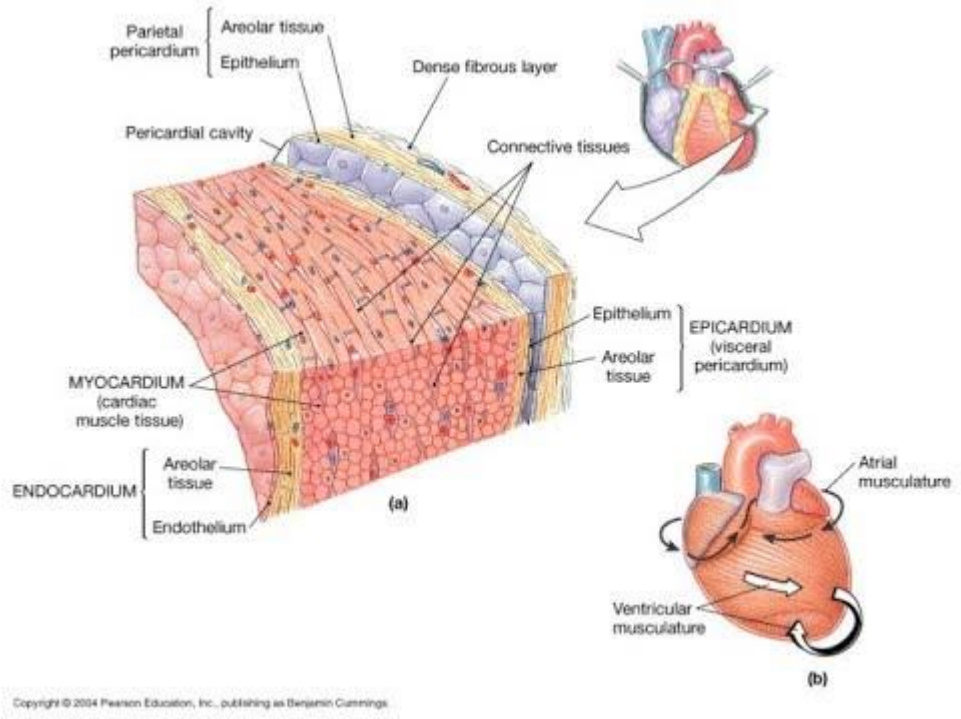

Figure 3: The image shown the layers of the heart.

1- The endocardium consists of:-

A- Thin inner layer of endothelium and supporting connective tissue,

B- Deep layer of connective tissue called the subendocardial layer that merges with the myocardium (Figure 3).

2- The myocardium, the thickest layer, consists mainly of cardiac muscle with its fibers arranged spirally around each heart chamber. The myocardium is much thicker in the walls of the ventricles, particularly the left, than in the atrial walls (Figure 1 & 3).

3- The epicardium is a simple squamous mesothelium supported by a layer of loose connective tissue containing blood vessels and nerves (Figure 3).

The Blood Vessels

There are three main types of blood vessels:

1- Arteries 2- Veins 3- Capillaries

This vast system of blood vessels (arteries, veins, and capillaries) is over 60,000 miles long. That's long enough to go around the world more than twice!

Blood flows continuously through your body's blood vessels. Your heart is the pump that makes it all possible.

1- Arteries: Arteries carry oxygen-rich blood away from the heart to all of the body's tissues. They branch several times, becoming smaller and smaller as they carry blood farther from the heart and into organs.

2- Capillaries: These are small, thin blood vessels that connect the arteries and the veins. Their thin walls allow oxygen, nutrients, carbon dioxide, and other waste products to pass to and from cells.

3- Veins: These are blood vessels that take blood back to the heart; this blood contains less oxygen and is rich in waste products that are to be excreted or removed from the body. Veins become larger as they get closer to the heart. The superior vena cava is the large vein that brings blood from the head and arms to the heart, and the inferior vena cava brings blood from the abdomen and legs into the heart.

Histological Structure of Blood Vessels

The tissue layers that compos the vascular wall are:

1- **The tunica intima** it is the innermost layer of blood vessels consist of the endothelium and a thin subendothelial layer of loose connective tissue.

The endothelium is a specialized epithelium that acts as a semipermeable barrier between two major internal compartments: the blood and the interstitial tissue fluid. Vascular endothelial cells are squamous, polygonal, and elongated with the long axis in the direction of blood flow (Figure 4).

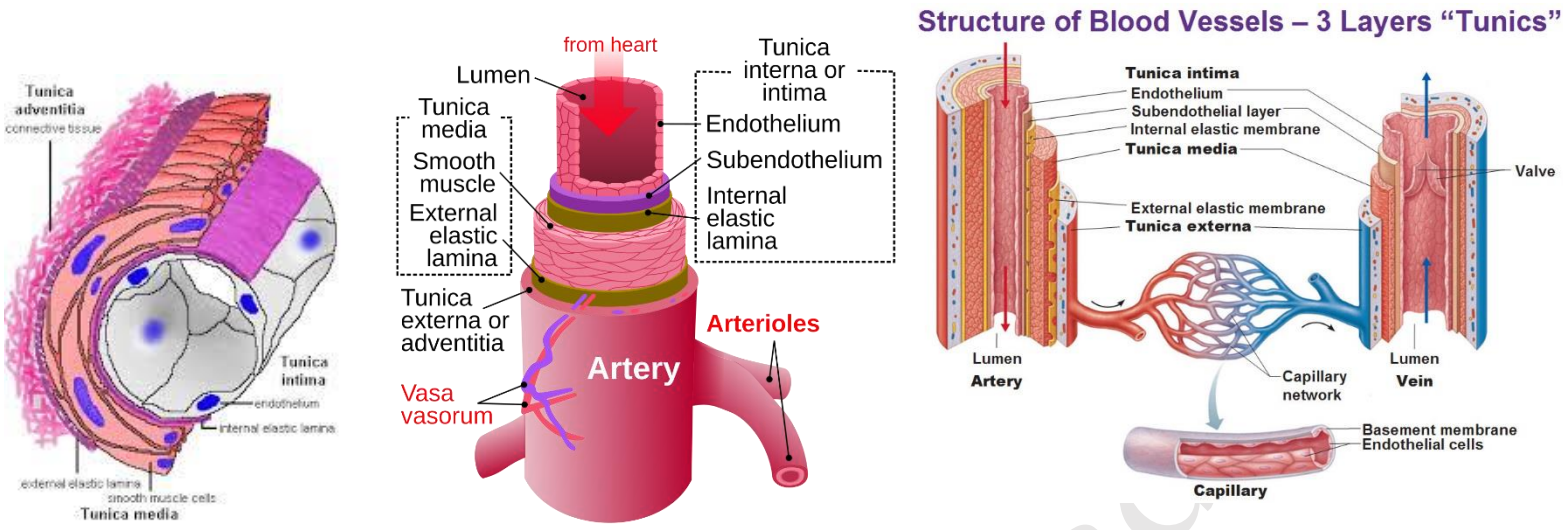

Figure 4: Image shown the layers of blood vessels.

2- The tunica media: the middle layer, consists chiefly of concentric layers of helically arranged smooth muscle cells Smooth muscle fibers occur in the walls of all vessels larger than capillaries (Figure 4).

3- The tunica externa or adventitia: is connective tissue consisting principally of type I collagen and elastic fibers. The adventitia is continuous with and bound to the stroma of the organ through which the blood vessel runs. Connective tissue components are present in vascular walls in variable amounts and proportions based on local functional requirements (Figure 4).

Large vessels usually have vasa vasorum (vessels of the vessel). The vasa vasorum are required to provide metabolites to cells in those tunics in larger vessels because the wall is too thick to be nourished solely by diffusion from the blood in the lumen.

Large veins commonly have more vasa vasorum than arteries, because they carry deoxygenated blood (Figure 5).

Types of Arteries

Types of the arteries:

1- Large elastic arteries

2- Medium muscular arteries

3- Small arteries and arterioles

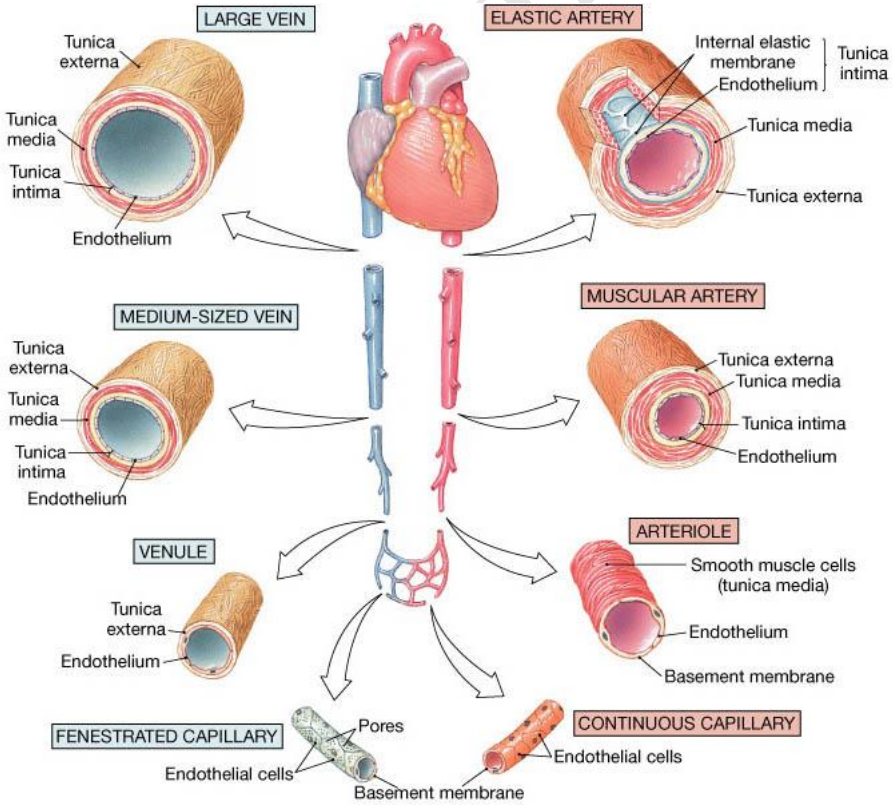

Figure 5: Image shown types of arteries.

1- Elastic arteries: Elastic arteries are the arteries that transport large volumes of blood from the heart and help to stabilize the blood flow. They include the aorta and pulmonary trunk and their major branches. These large vessels are also called conducting arteries because their major role is to carry blood to smaller arteries.

The tunica intima is well developed, with many smooth muscle cells in the subendothelial connective tissue.

Between the intima and the media is the internal elastic lamina. Elastic arteries have yellowish colour from the accumulation of elastin in the media. The adventitia is much thinner than the media.

The numerous elastic laminae of these arteries contribute to their important function of making the blood flow more uniform.

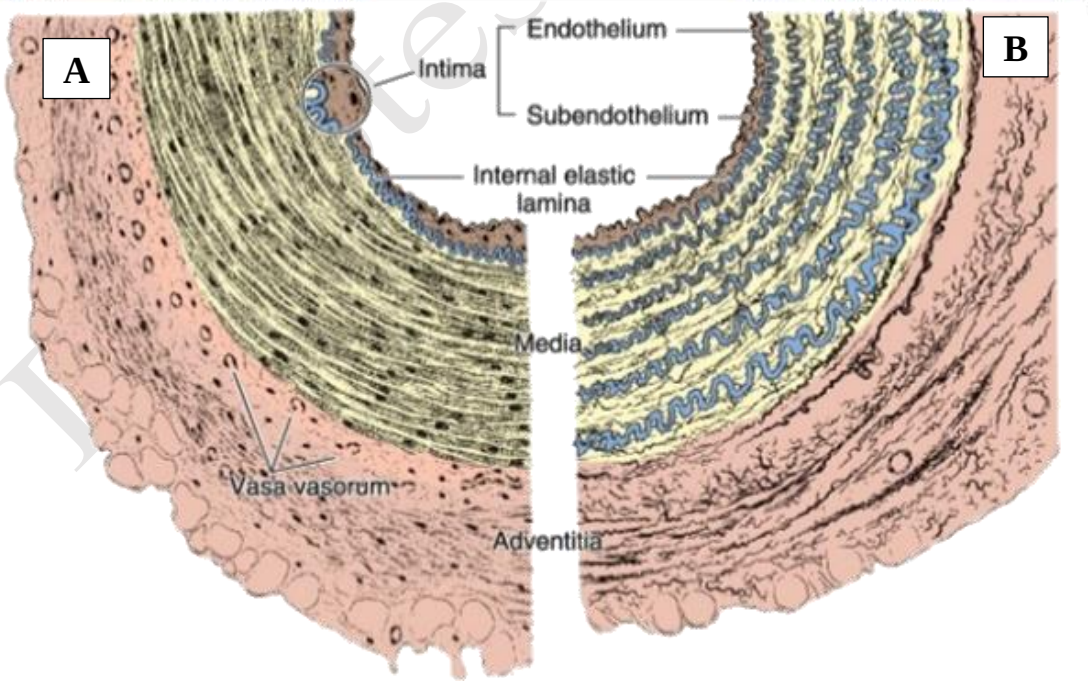

Figure 6: Image shown types of arteries **A)** Muscular artery **B)** Elastic artery.

2- Muscular Arteries: The muscular arteries, also called distributing arteries, distribute blood to the organs and help regulate blood pressure by contracting or relaxing the smooth muscle in the tunica media.

The intima has a thin subendothelial layer and a prominent internal elastic lamina (Figure 6 & 7).

The media may contain up to 40 layers of large smooth muscle cells. An external elastic lamina is present only in the larger muscular arteries. The adventitial connective tissue contains lymphatic capillaries, vasa vasorum, and nerves, all of which may penetrate to the outer part of the media. Examples of these arteries include the external carotid arteries of the neck, the brachial arteries of the arms, the femoral arteries of the thigh and the mesenteric arteries of the abdomen.

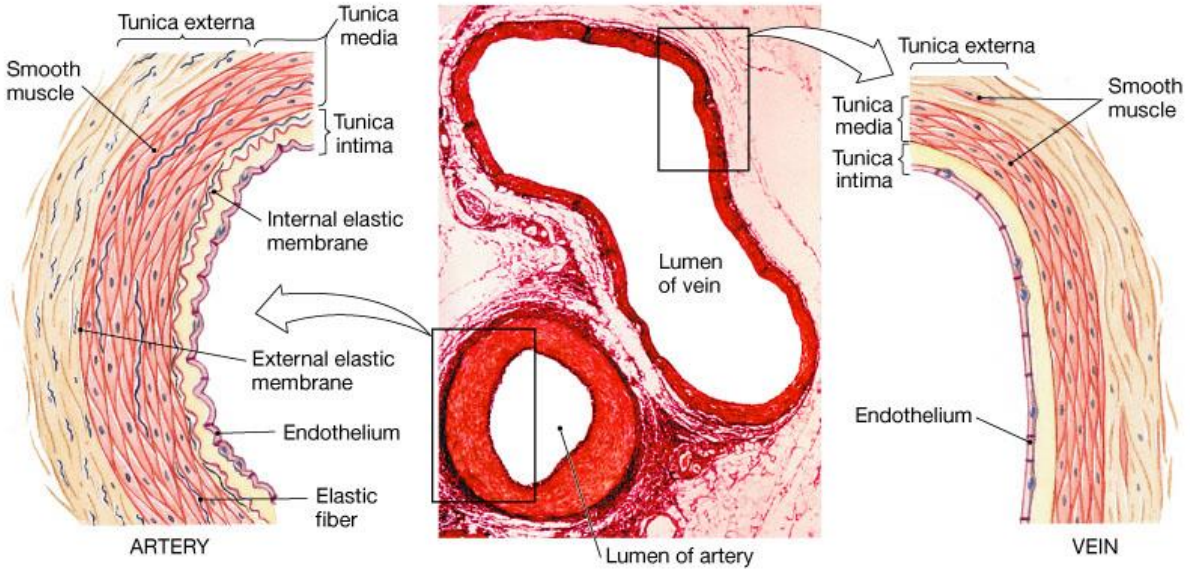

Figure 7: Image shown the structure of muscular artery and vein.

3- Arterioles

Arterioles have only one or two smooth muscle layers; these indicate the beginning of an organ's microvasculature where exchanges between blood and tissue fluid occur. The subendothelial layer is very thin, elastic laminae are absent, and the media consists of the circularly arranged smooth muscle cells. In both small arteries and arterioles the adventitia is very thin.

Type of Artery	Outer Diameter (Approx. Range)	Intima	Media	Adventitia	Roles in Circulatory System
Elastic arteries	> 10 mm	Endothelium; connective tissue with smooth muscle	Many elastic lamellae alternating with smooth muscle	Connective tissue, thinner than media, with vasa vasorum	Conduct blood from heart and with elastic recoil help move blood forward under steady pressure
Muscular arteries	10-1 mm	Endothelium; connective tissue with smooth muscle, internal elastic lamina prominent	Many smooth muscle layers, with much less elastic material	Connective tissue, thinner than media; vasa vasorum maybe present	organs and maintain steady blood pressure and flow with vasodilation and constriction
Small arteries	1-0.1 mm	Endothelium; connective tissue less smooth muscle	3-10 layers of smooth muscle	Connective tissue, thinner than media; no vasa vasorum	Distribute blood to arterioles, adjusting flow with vasodilation and constriction

Arterioles	100-10 µm	Endothelium; no connective tissue or smooth muscle	1-3 layers of smooth muscle	Very thin connective tissue layer	Resist and control blood flow to capillaries; major determinant of systemic blood pressure
Capillaries	10-4 µm	Endothelium only	A few pericytes only	None	Exchange metabolites by diffusion to and from cells
Venules (postcapillary, collecting, and muscular)	10-100 µm	Endothelium; no valves	Pericytes and scattered smooth muscle cells	None	Drain capillary beds; site of leukocyte exit from vasculature
Small veins	0.1-1 mm	Endothelium; connective tissue with scattered smooth muscle fibers	Thin, 2-3 loose layers of smooth muscle cells	Connective tissue, thicker than media	Collect blood from venules
Medium veins	1-10 mm	Endothelium; connective tissue, with valves	3-5 more distinct layers of smooth muscle	Thicker than media; longitudinal smooth muscle may be present	Carry blood to larger veins, with no backflow
Large veins	> 10 mm	Endothelium; connective tissue, smooth muscle cells; prominent valves	> 5 layers of smooth muscle, with much collagen	Thickest layer, with bundled longitudinal smooth muscle	Return blood to heart