THE BRAIN

PREPARED BY:
Dr. REYADH AL-RASHIDI

Functions of the Nervous System

- **Sensory input:** Monitor internal and external stimuli
  - Touch, odor, sound, vision, taste and body temp.

- **Integration:** CNS(Brain and spinal cord) process sensory input and initiate responses

- **Motor output:** Controls of contraction of muscles and secretion of glands

The Nervous System

- The nervous system is the body's primary communication and control system.

- The nervous system can be divided according to structural and functional classification.

Structural (Anatomical) Divisions of the Nervous System

Two Structural (Anatomical) Divisions

- **Central nervous system** (CNS)
  - Brain
  - Spinal cord
- **Peripheral nervous system** (PNS)
  - Cranial nerves (nerves that extend from the brain)
  - Spinal nerves (nerves that extend from the spinal cord)
  - Ganglia (clusters of neuron cell bodies located outside the CNS)

Functional (physiological) Divisions of the Nervous System

Functional (physiological) divisions of the Nervous system:

- **Sensory (or afferent) division** — receives sensory information (input) from receptors and transmits this information to the CNS.

- **Motor (or efferent) division** — transmits motor impulses (output) from the CNS to muscles or glands.

Meninges

- **Dura mater** -- outermost, tough membrane
  - outer periosteal layer
  - inner meningeal layer
- **Arachnoid mater** is spider web filamentous layer
- **Pia mater** is a thin vascular layer

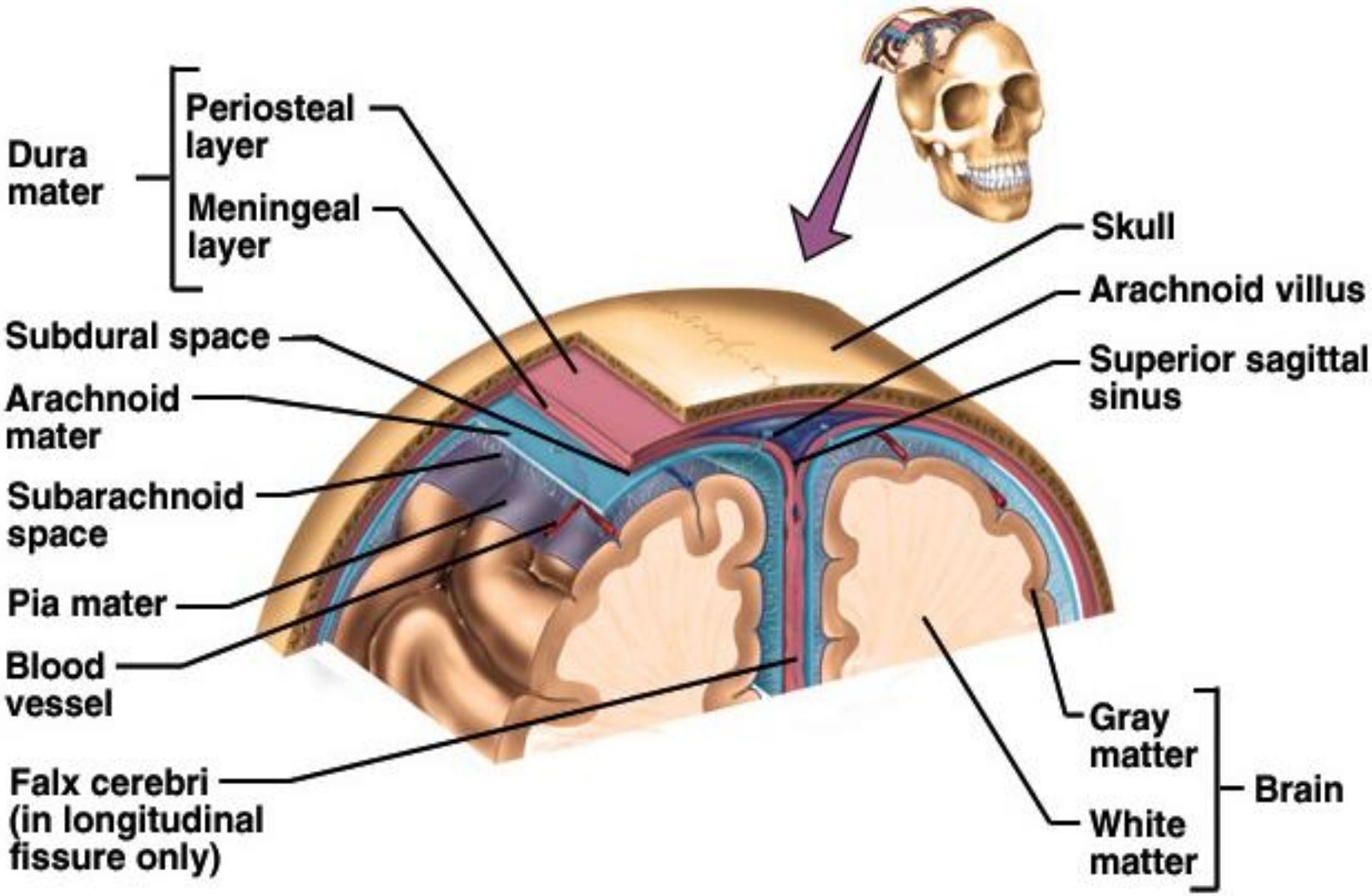
Dura mater
Periosteal layer
Meningeal layer
Subdural space
Arachnoid mater
Subarachnoid space
Pia mater
Blood vessel
Falx cerebri (in longitudinal fissure only)
Skull
Arachnoid villus
Superior sagittal sinus
Gray matter
White matter
Brain

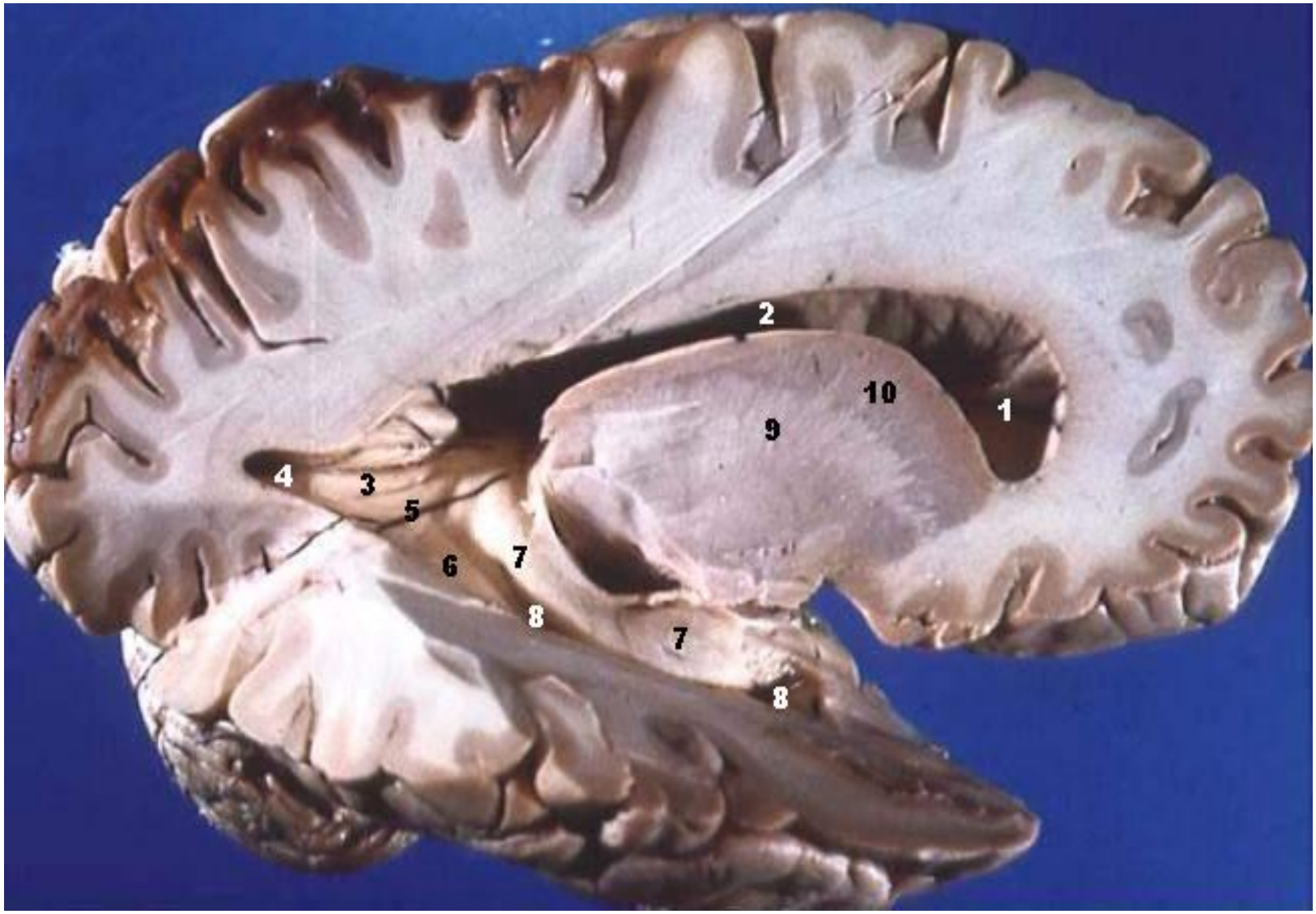
2
10
1
9
4
3
5
6
7
8
7
8

Anatomy of the Brain

There are three major divisions of the brain:

- Forebrain
- midbrain
- Hindbrain

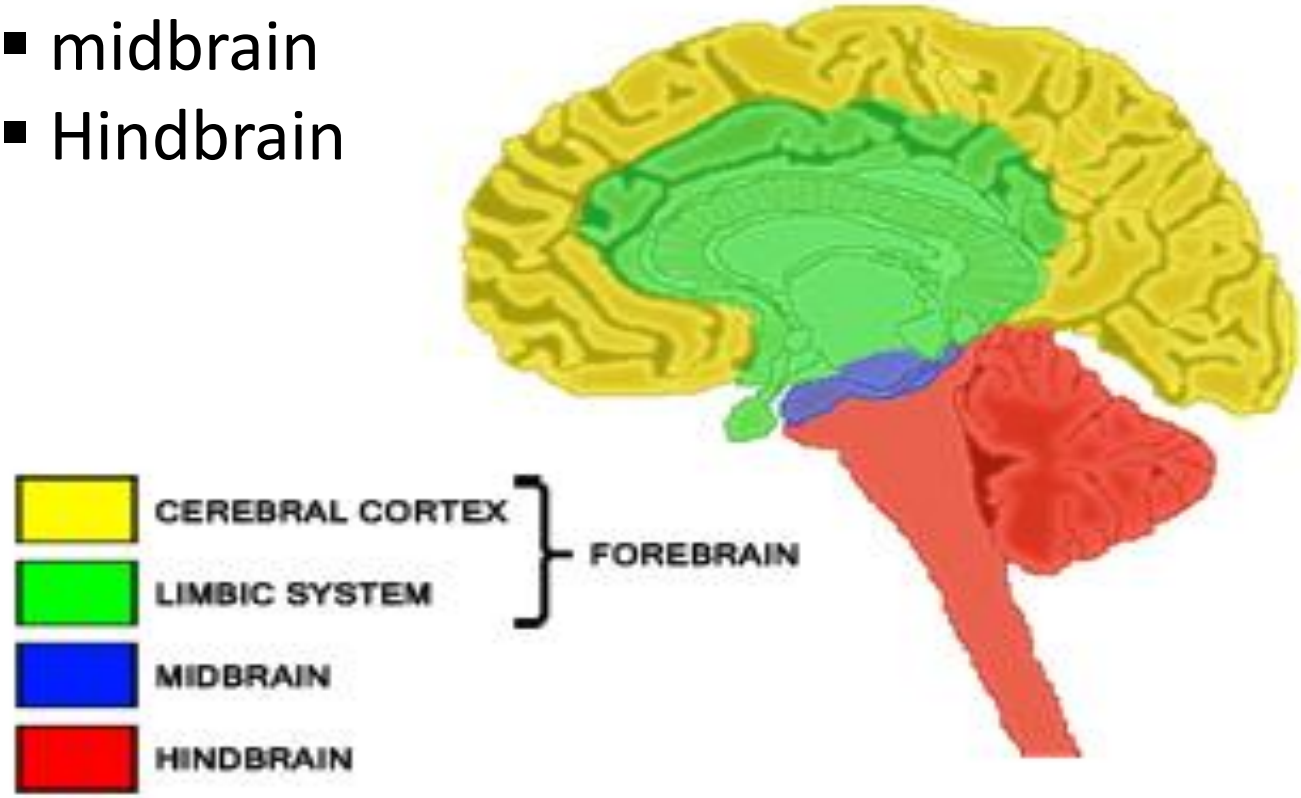

1- Forebrain

There are two major divisions of forebrain:

- Diencephalon
- Telencephalon

➢The diencephalon contains structures such as the thalamus, hypothalamus and epithalamus.

➢ The telencephalon contains the cerebrum.

The cerebrum is composed of the following sub-regions:

- Cerebral cortex
- Basal nuclei
- Limbic System

Hypothalamus

- Control of the ANS.
- control endocrine system
- Regulation of behavioral patterns, eating and drinking and body temperature

Epithalamus

- Melatonin induces sleep.(pineal gland)
- Work together with limbic system (emotion)

Thalamus

- Major relay station for most sensory impulses.

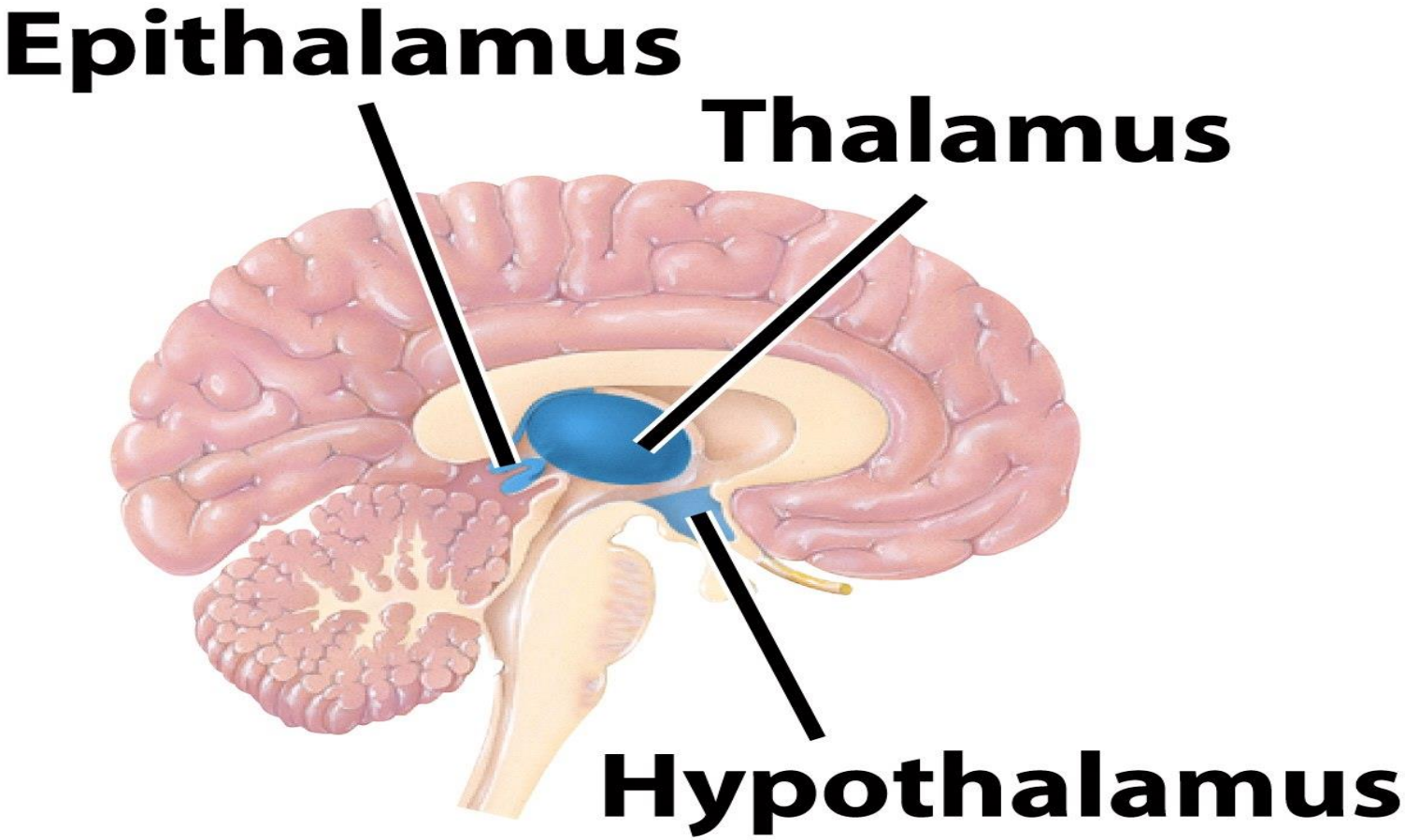
Epithalamus
Thalamus
Hypothalamus

Functional Organization of the Cerebral Cortex:

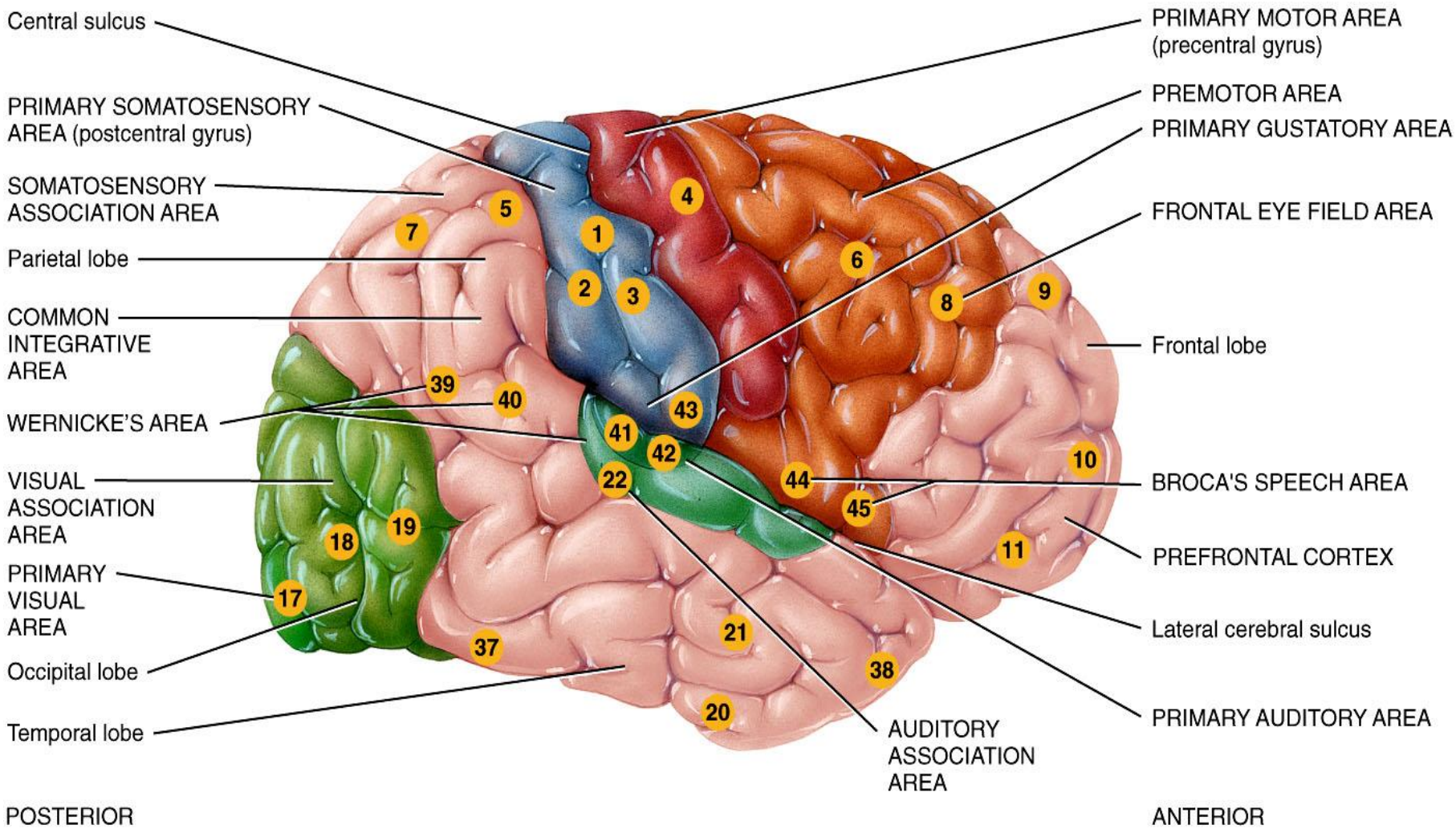

Lateral view of right cerebral hemisphere

Basal Nuclei

- Three nuclei, globus pallidus, putamen, and caudate nucleus.
- Help initiate and terminate movements
- suppress unwanted movements
- regulate muscle tone.

Basal Nuclei

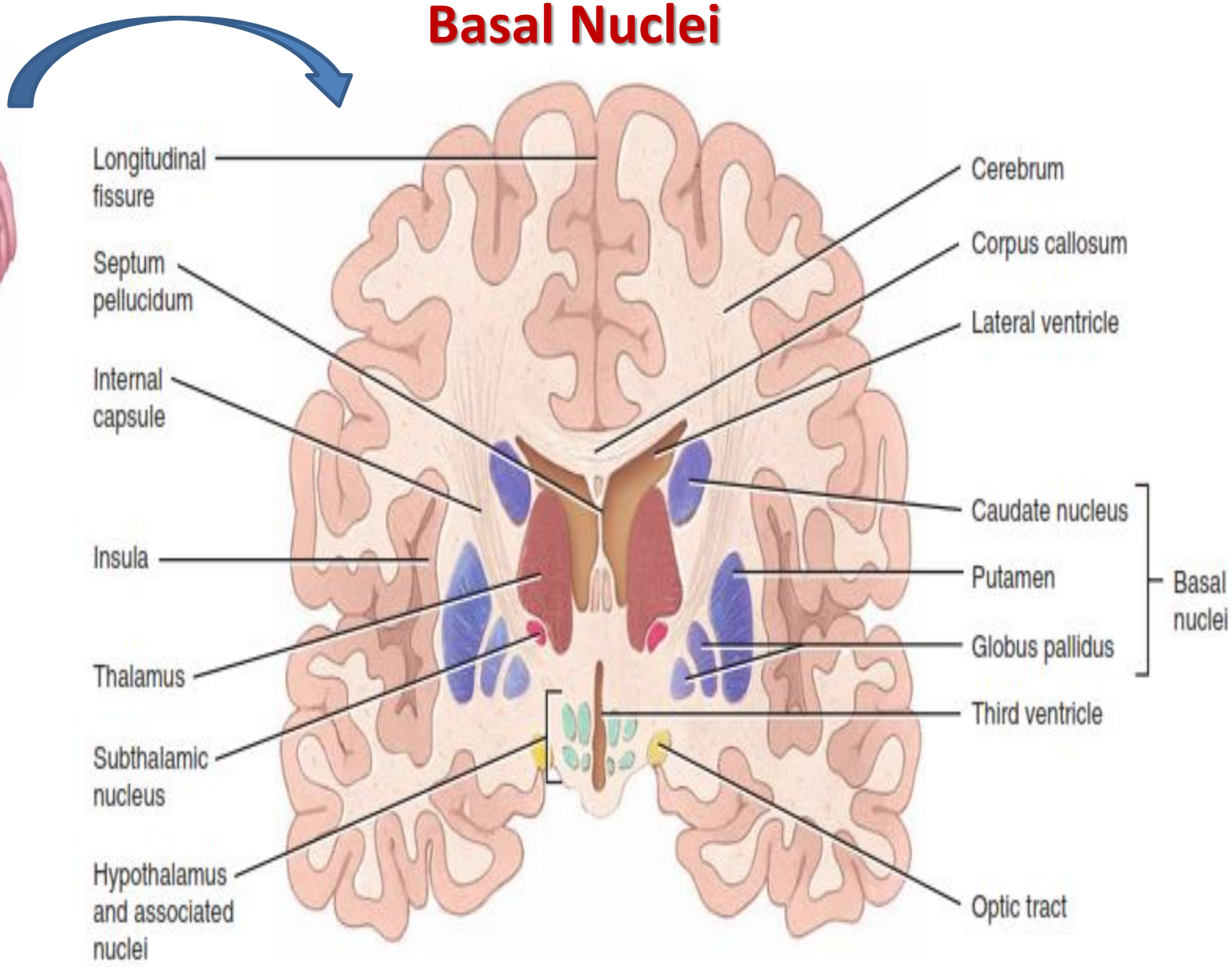

The Limbic System

- Includes cingulate gyrus, hippocampus, dentate gyrus, amygdala, mammillary bodies, thalamus, and the olfactory bulb.
- “emotional brain” as it governs emotional aspects of behavior.

Limbic System

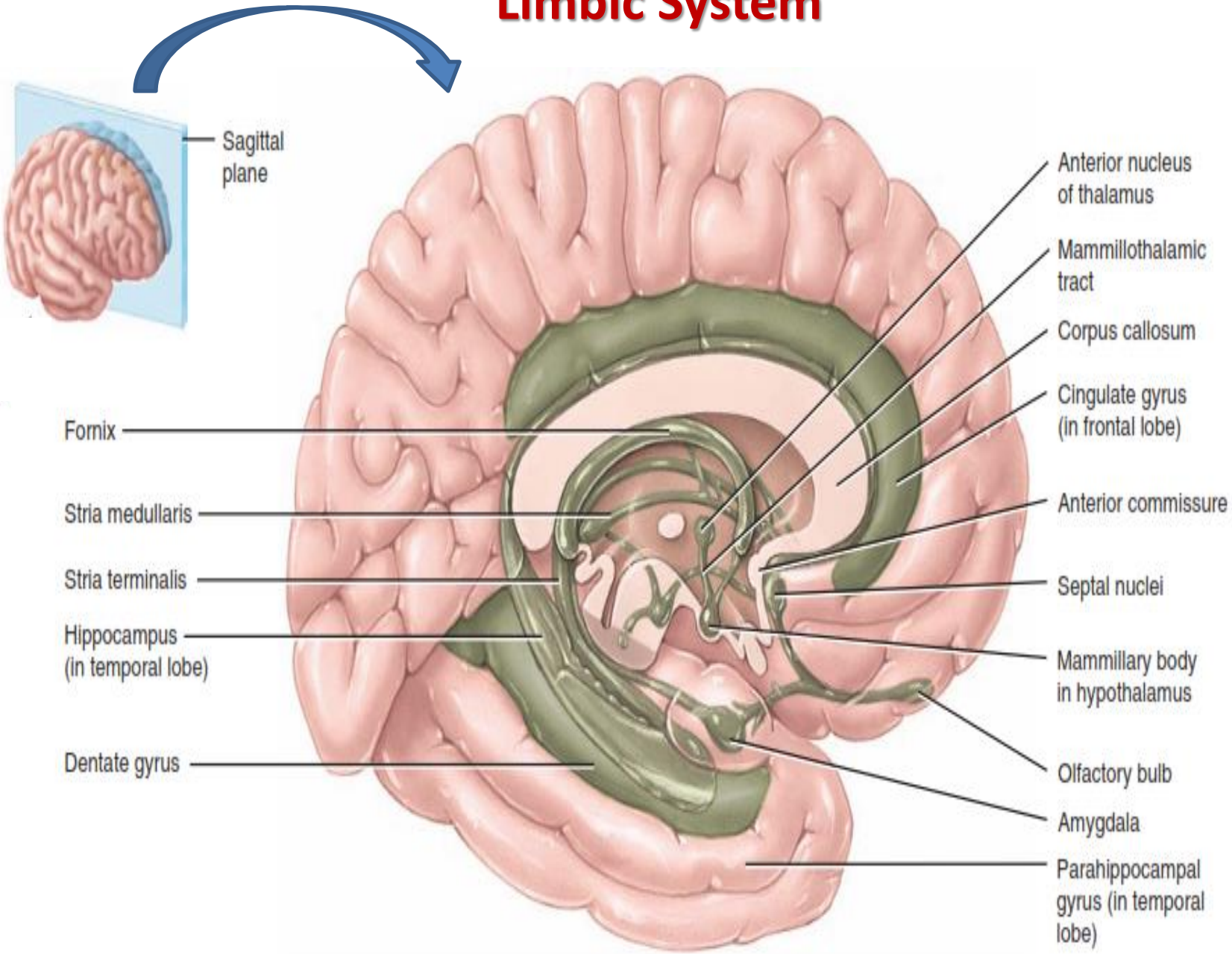

2- Midbrain

The midbrain or **mesencephalon** is a portion of the central nervous system associated with vision, hearing, motor control and sleep/wake pattern.

Anatomically, it comprises of:

- Tectum
- Tegmentum
  - Red nucleus
  - Substantia nigra
  - Reticular formation
- Cerebral peduncles

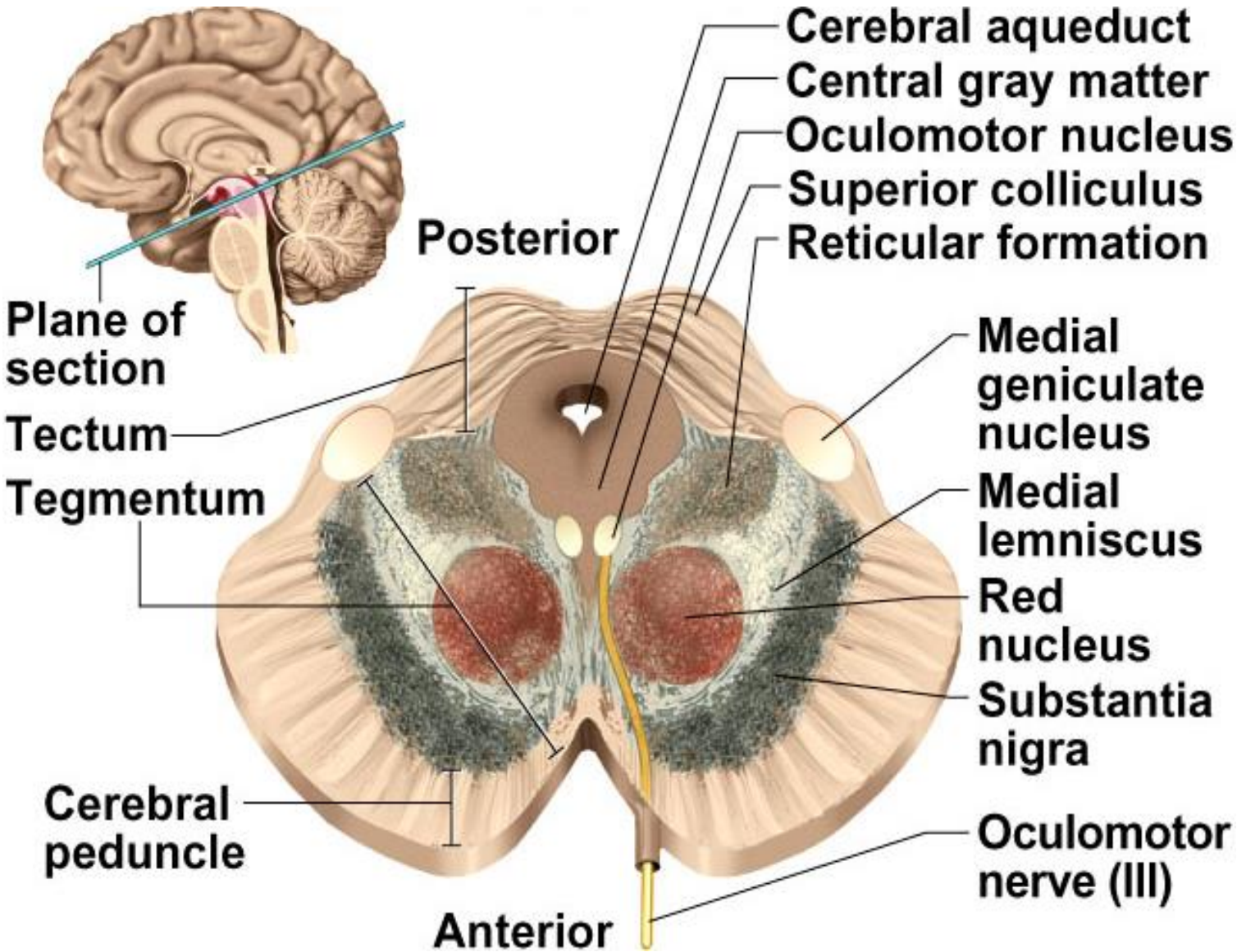
Cerebral aqueduct
Central gray matter
Oculomotor nucleus
Superior colliculus
Reticular formation
Posterior
Plane of section
Tectum
Tegmentum
Medial geniculate nucleus
Medial lemniscus
Red nucleus
Substantia nigra
Cerebral peduncle
Oculomotor nerve (III)
Anterior

3- Hindbrain

It consist of:

- **Myelencephalon**
- **Metencephalon**

- Myelencephalon → medulla oblongata.

- Metencephalon → the pons and the cerebellum

Pons:

- Contains sensory and motor tracts.
- relay nerve impulses from motor areas of cerebral cortex to cerebellum.
- Pneumotaxic area and apneustic area (together with the medulla) help control breathing.

The Medulla Oblongata

- Vital centers:

  Cardiovascular center-

  Respiratory center-
- Also includes centers for vomiting, swallowing, sneezing and coughing.

The Cerebellum

Functions- coordinate movements, regulate posture and balance.

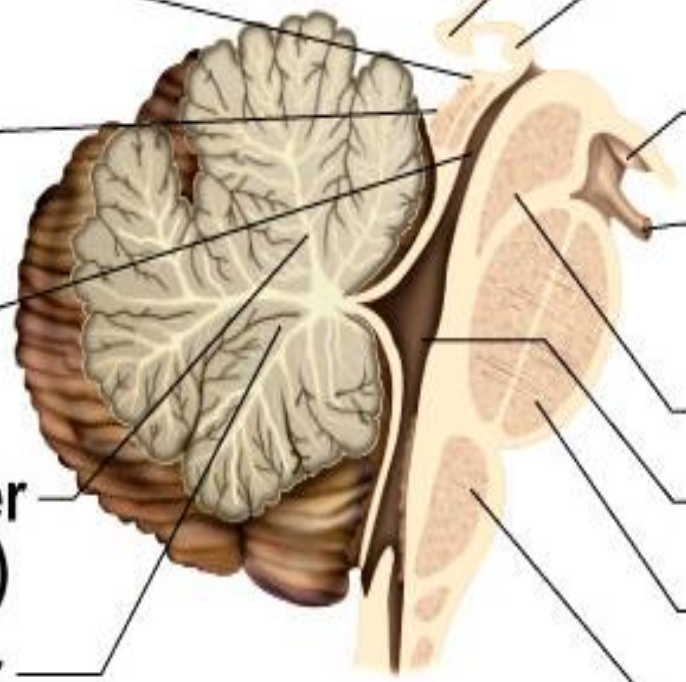
Superior colliculus
Inferior colliculus
Cerebral aqueduct
White matter (arbor vitae)
Gray matter
Pineal gland
Posterior commissure
Mammillary body
Oculomotor nerve
Midbrain
Fourth ventricle
Pons
Medulla oblongata

BLOOD SUPPLY OF THE BRAIN

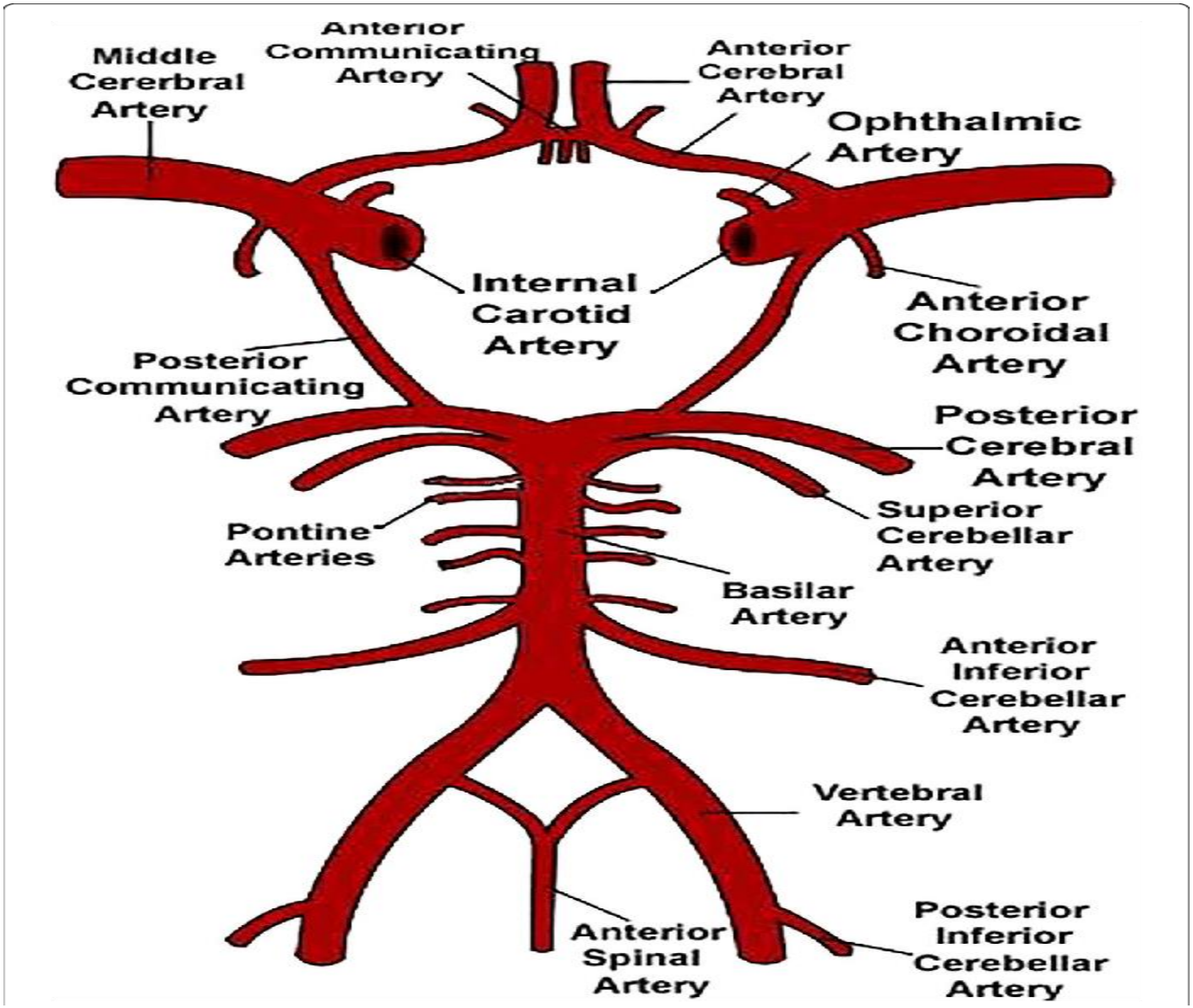

VENOUS DRAINAGE OF BRAIN

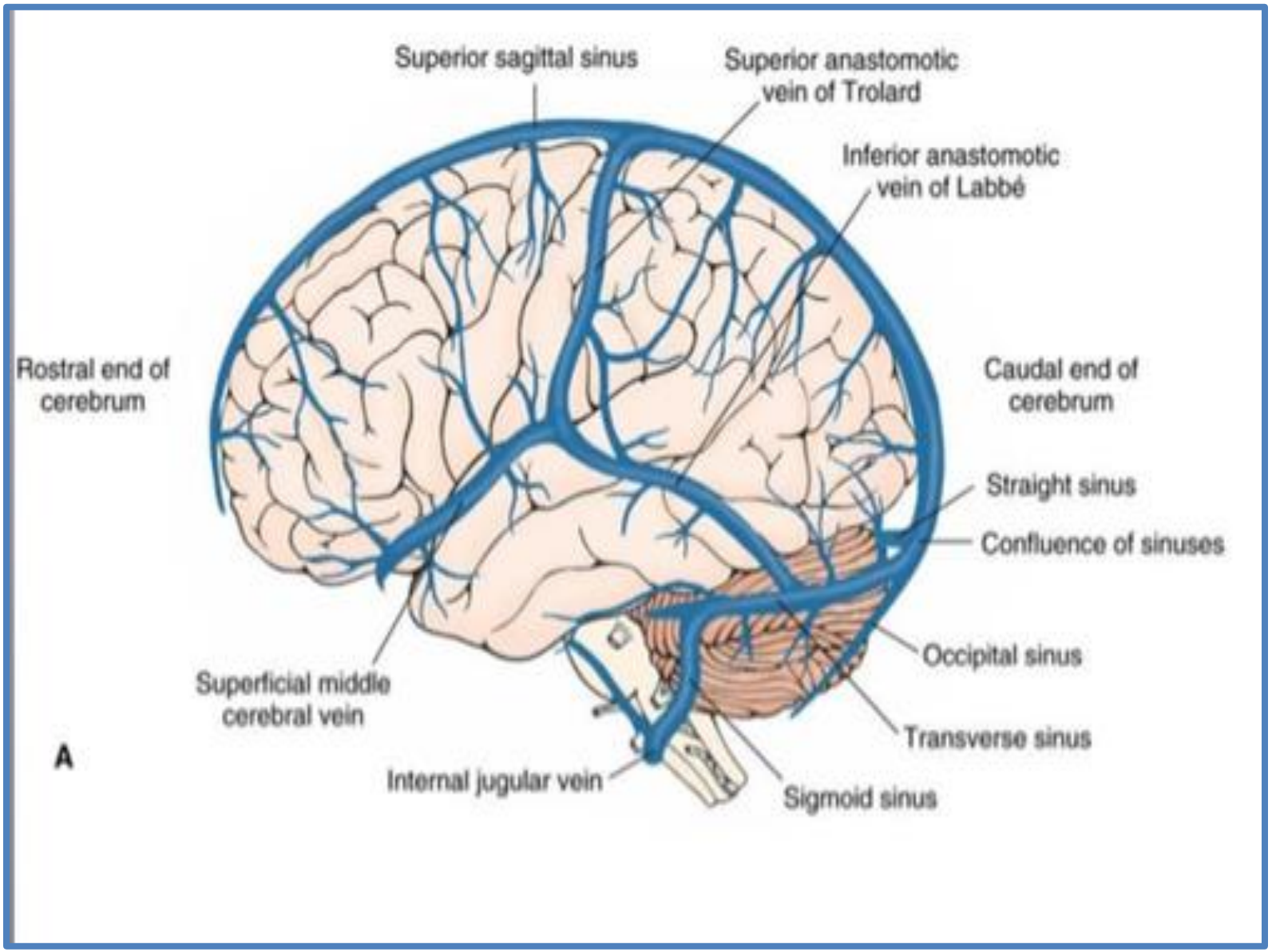

THANK YOU

CRANIAL NERVES PART 1

PREPARED BY:

Dr. REYADH AL-RASHIDI

Structural (Anatomical) Divisions of the Nervous System

Two Structural (Anatomical) Divisions

- **Central nervous system** (CNS)
  - Brain
  - Spinal cord
- **Peripheral nervous system** (PNS)
  - Cranial nerves (nerves that extend from the brain)
  - Spinal nerves (nerves that extend from the spinal cord)
  - Ganglia (clusters of neuron cell bodies located outside the CNS)

Olfactory Nerve (I)

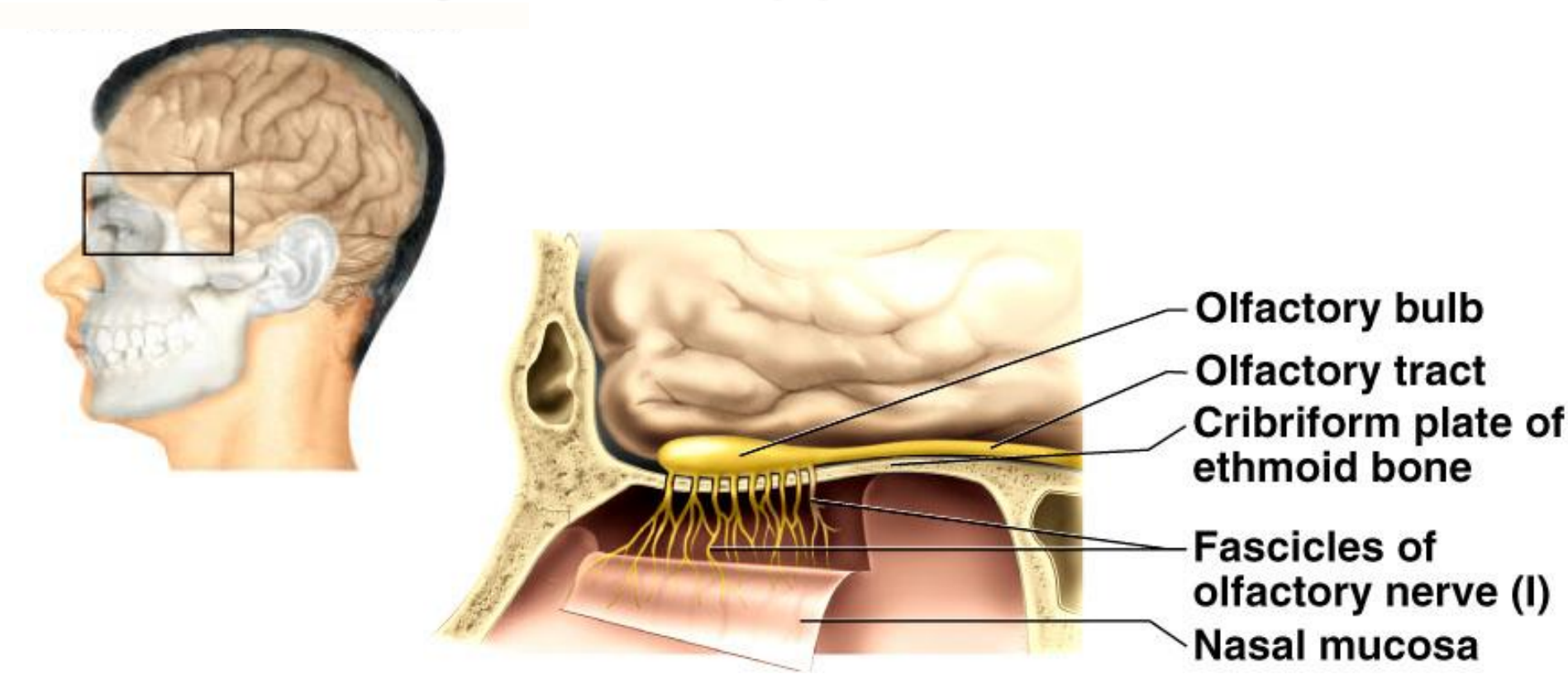

- Provides sense of smell

Olfactory Nerves

- The olfactory nerves arise from olfactory receptor nerve cells in the olfactory mucous membrane. The olfactory mucous membrane is situated in the upper part of the nasal cavity above the level of the superior concha
- Bundles of these olfactory nerve fibers pass through the openings of the cribriform plate of the ethmoidal bone to enter the olfactory bulb in the cranial cavity. The olfactory tract will be formed and then it pass through the Thalamus. Then will terminate in the (olfactory center) of the **cerebral cortex**.

Optic Nerve (II)

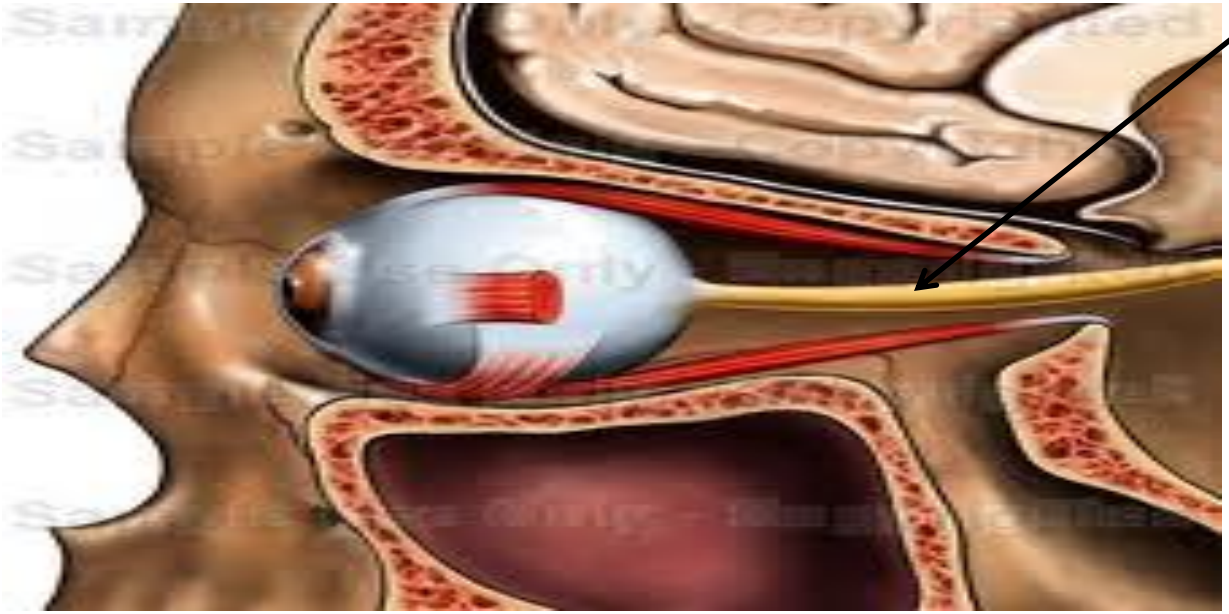

- Provides vision

Optic Nerve

The optic nerve arise from retina of the eye. The optic nerve emerges from the back of the eyeball and leaves the orbital cavity through the optic canal to enter the cranial cavity. The optic nerve then unites with the optic nerve of the opposite side to form the **optic chiasma**. Then divide again to form the **optic tract**. Then pass through Thalamus. Optic tract pass posteriorly as the optic radiation and terminate in the (visual center) **cerebral cortex**.

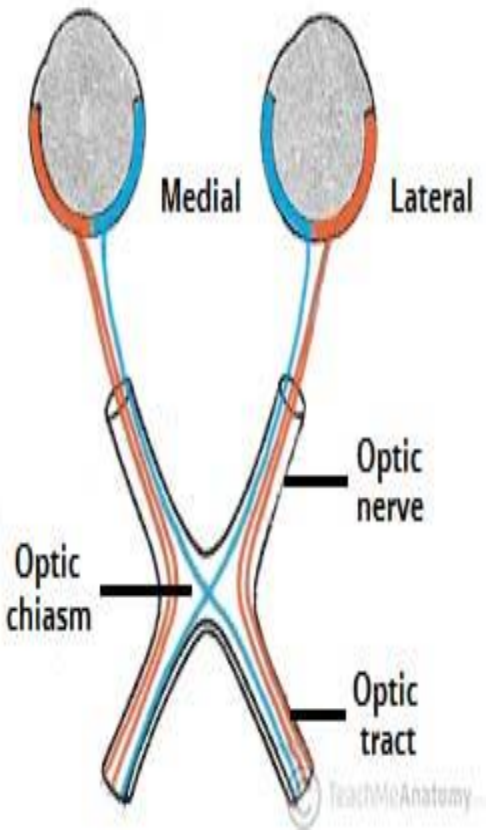

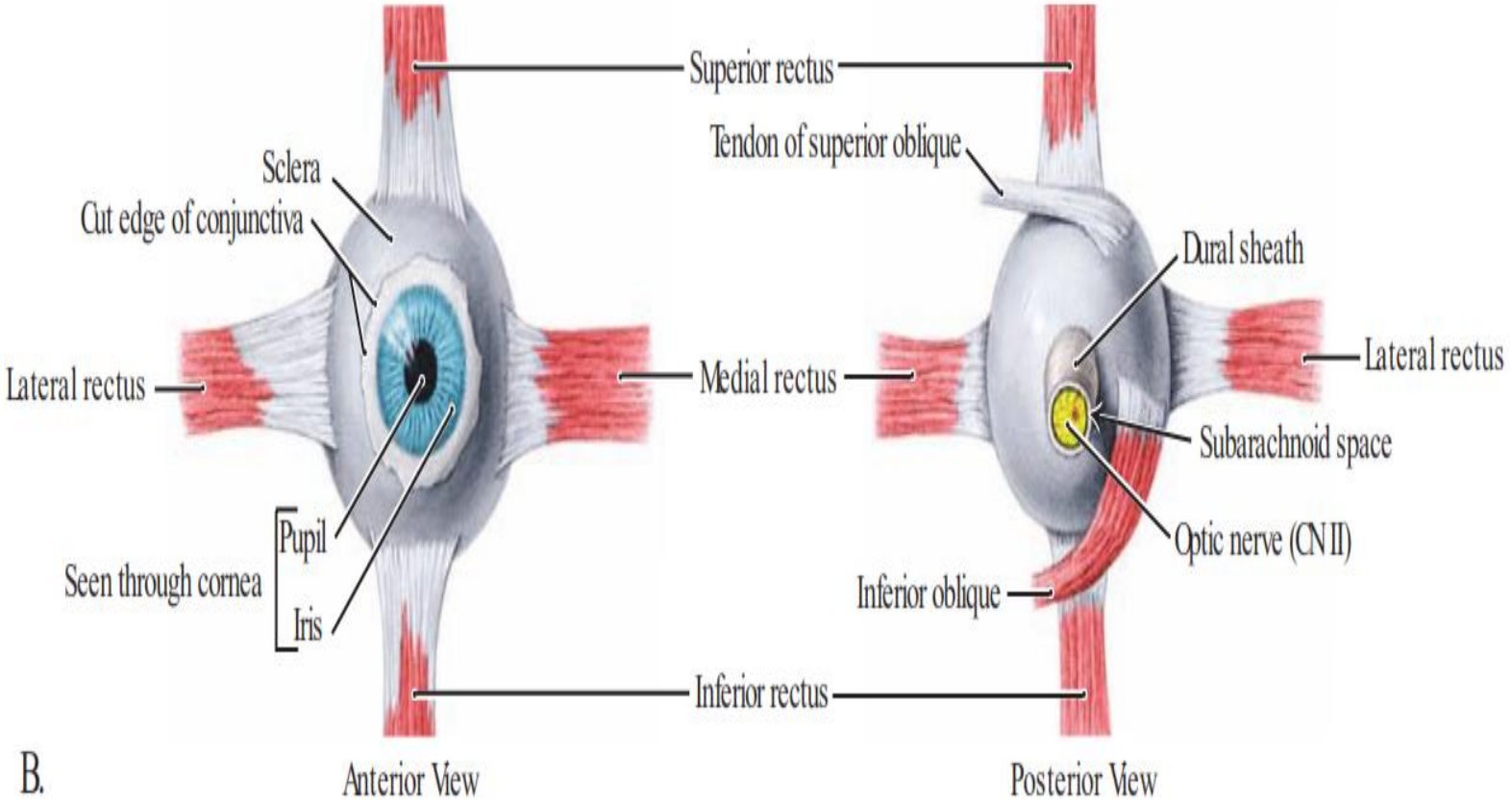
Superior rectus
Tendon of superior oblique
Sclera
Cut edge of conjunctiva
Dural sheath
Lateral rectus
Medial rectus
Lateral rectus
Subarachnoid space
Pupil
Seen through cornea
Iris
Optic nerve (CN II)
Inferior oblique
Inferior rectus
B.
Anterior View
Posterior View

Oculomotor Nerve (III)

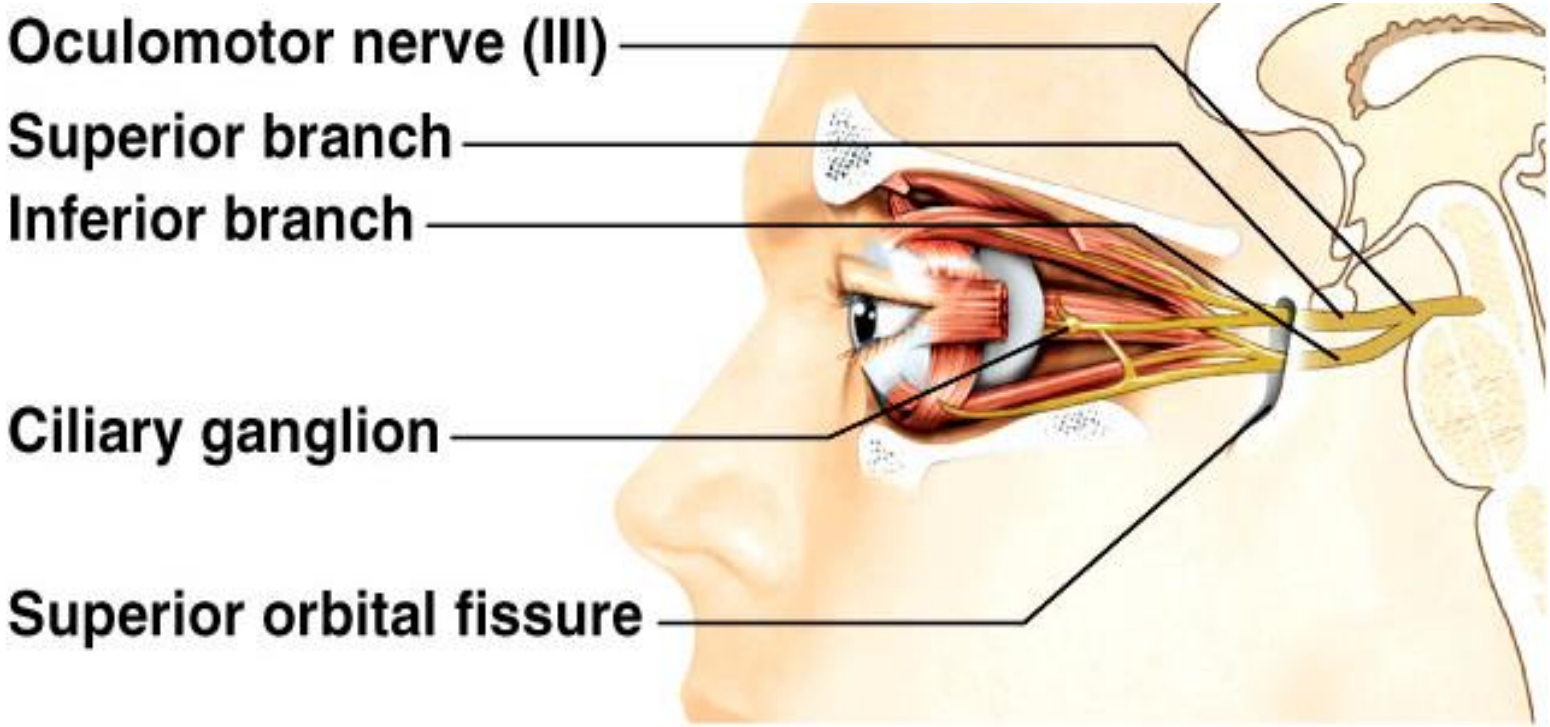

- Provides some eye movement, opening of eyelid, constriction of pupil, focusing .

- The oculomotor nerve emerges from the **midbrain** and enter the orbital cavity through the superior orbital fissure. The extrinsic muscles of the eye: the superior rectus, medial rectus, inferior rectus, and inferior oblique and Provides eye movement.
- The intrinsic muscles of the eye: The constrictor pupillae muscle is supplied by the parasympathetic component of the oculomotor nerve.

Trochlear Nerve (IV)

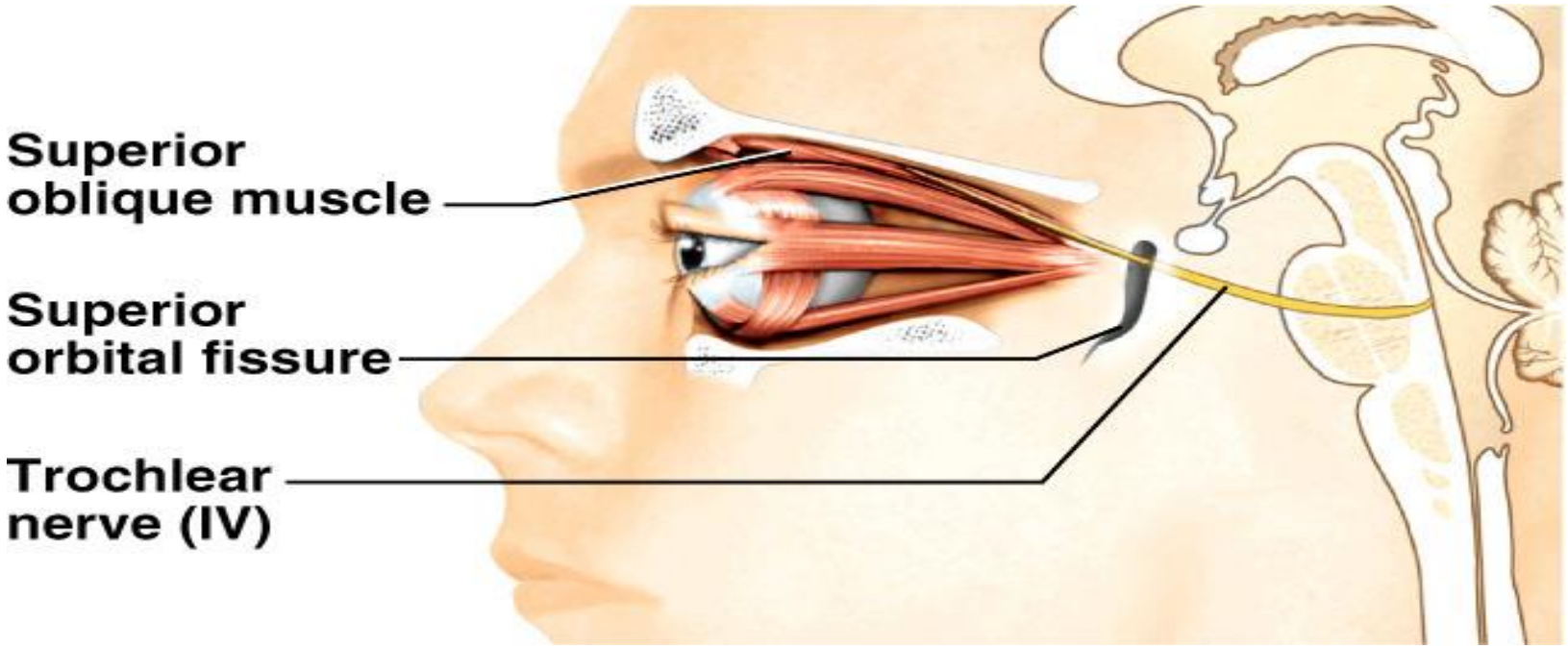

- Origin from the **midbrain**, it then passes forward through the middle cranial fossa in and enters the orbit through the superior orbital fissure. The trochlear nerve supplies: The superior oblique muscle of the eyeball and Provides eye movement.

Abducens Nerve (VI)

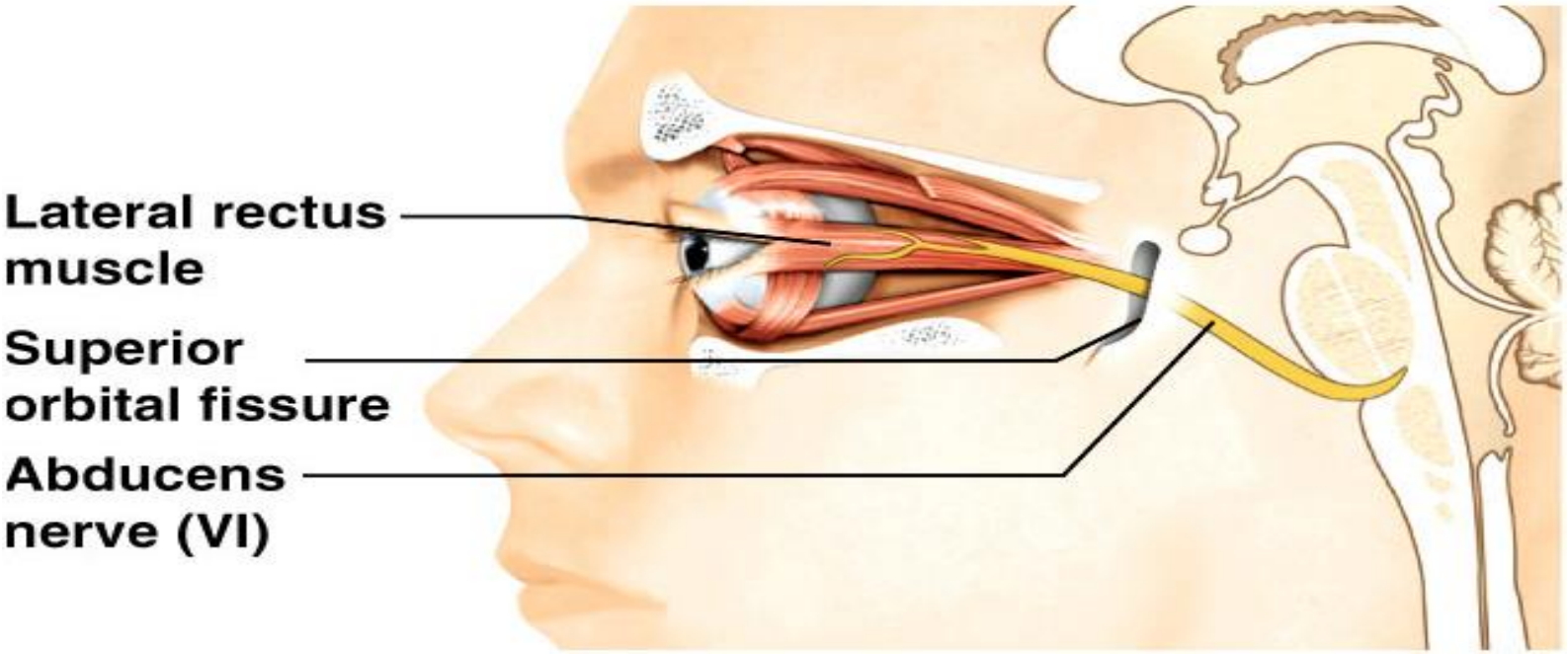

Origin from the **pons**, it then passes forward through the middle cranial fossa in and enters the orbit through the superior orbital fissure. The Abducens Nerve supplies: The Lateral rectus muscle of the eyeball and Provides eye movement.

Trigeminal Nerve (V)

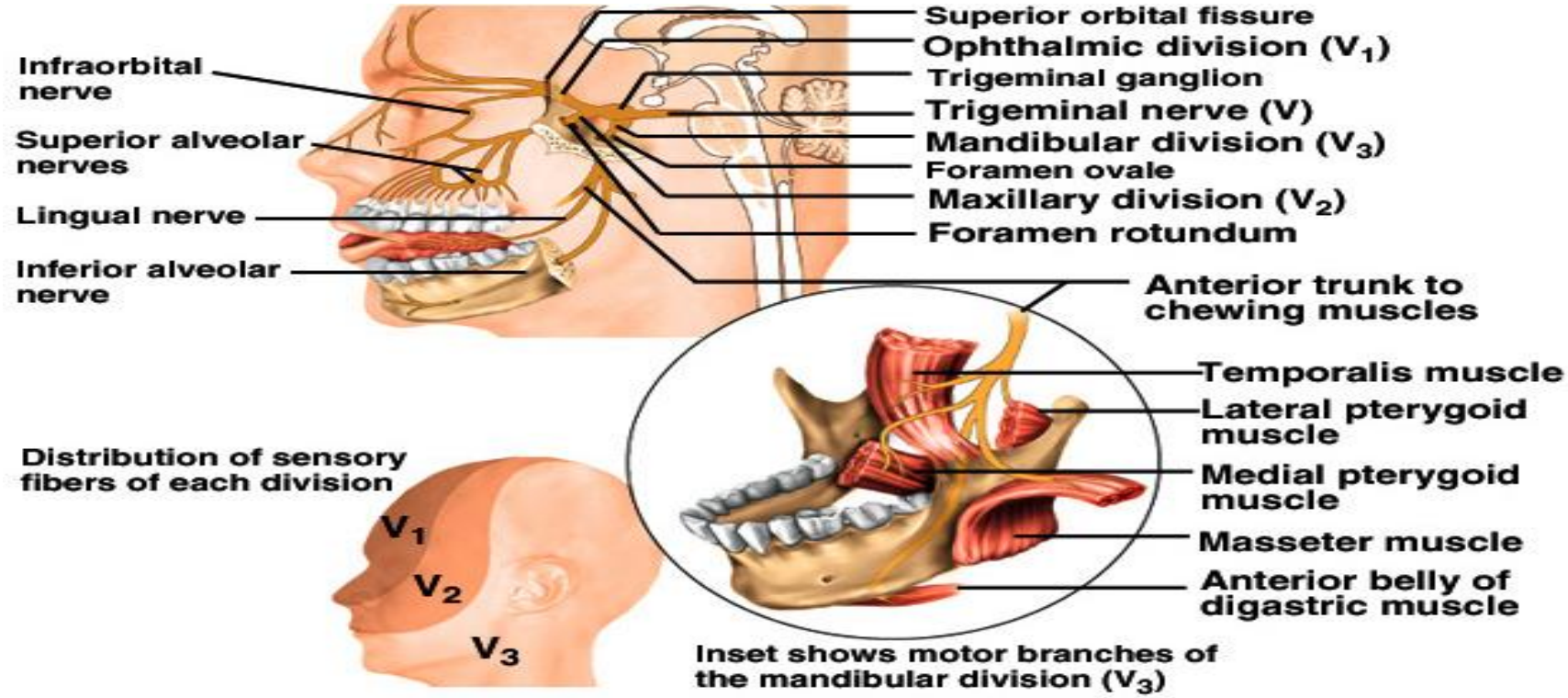

The trigeminal nerve is the largest cranial nerve origin from the pons as a small **motor root and a large sensory root, and it passes forward, out of** the posterior cranial fossa, to reach the apex of the petrous part of the temporal bone in the middle cranial fossa. It divides to ophthalmic (V1), maxillary (V2), and mandibular (V3) nerves.

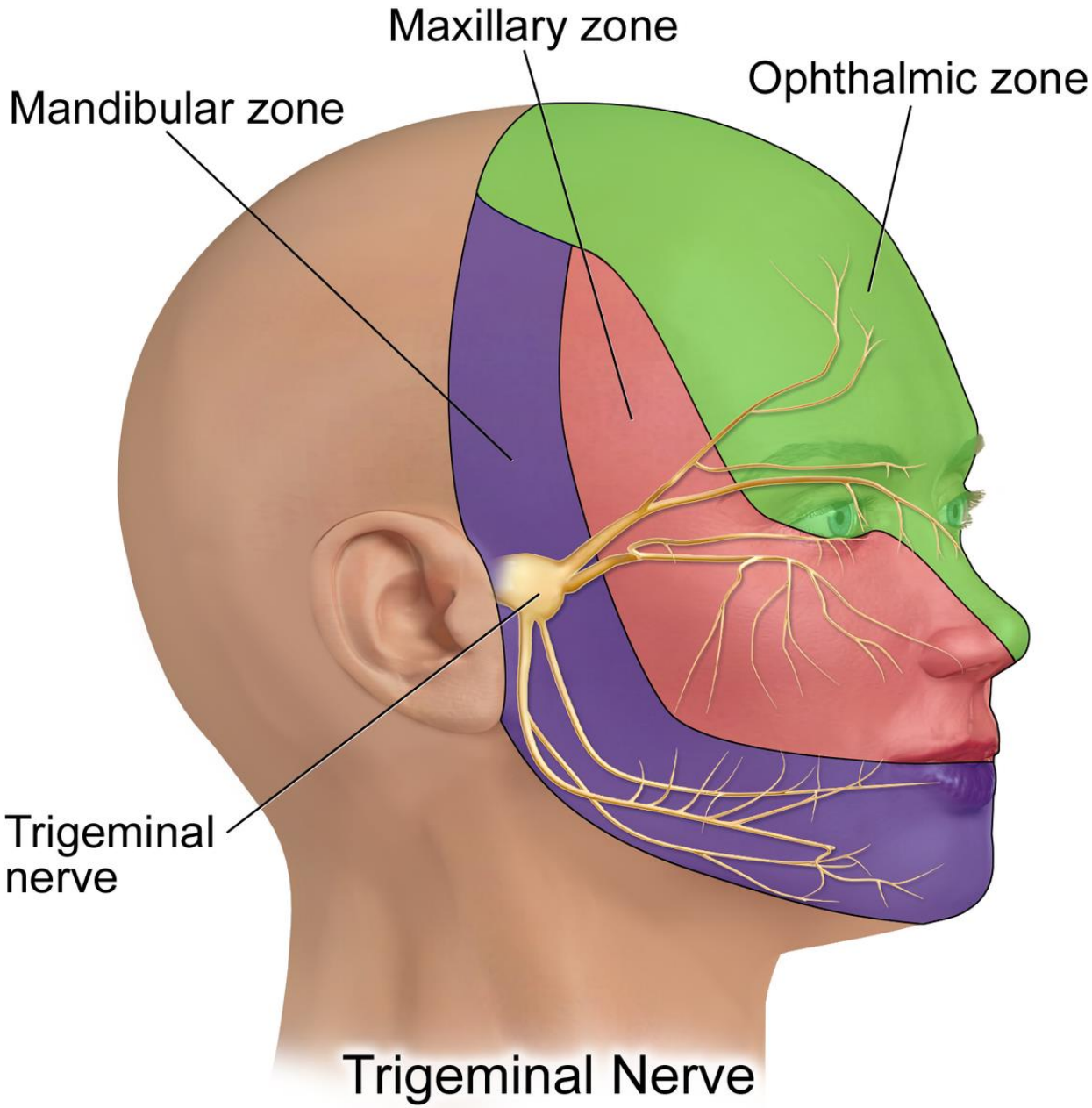
Maxillary zone
Ophthalmic zone
Mandibular zone
Trigeminal
nerve
Trigeminal Nerve

Ophthalmic Nerve (V1)

The ophthalmic nerve is purely sensory, it enters the orbital cavity through the superior orbital fissure. Branches :

- The lacrimal nerve runs forward on the upper border of the lateral rectus muscle It is joined by the zygomaticotemporal branch of the maxillary nerve, which contains the parasympathetic fibers to the lacrimal gland. The lacrimal nerve then enters the lacrimal gland and gives branches to the conjunctiva and the skin of the upper eyelid.
- The frontal nerve supply the frontal air sinus and the skin of the forehead and the scalp.
- The nasociliary nerve gives off two internal nasal branches and it then Supplies the skin of the tip of the nose with the external nasal nerve. Its branches include the following:
  - Long ciliary nerves→ sensory fibers to the cornea
  - Infratrochlear nerve → sensory to conjunctiva
  - Posterior ethmoidal nerve that is sensory to the ethmoid and sphenoid sinuses

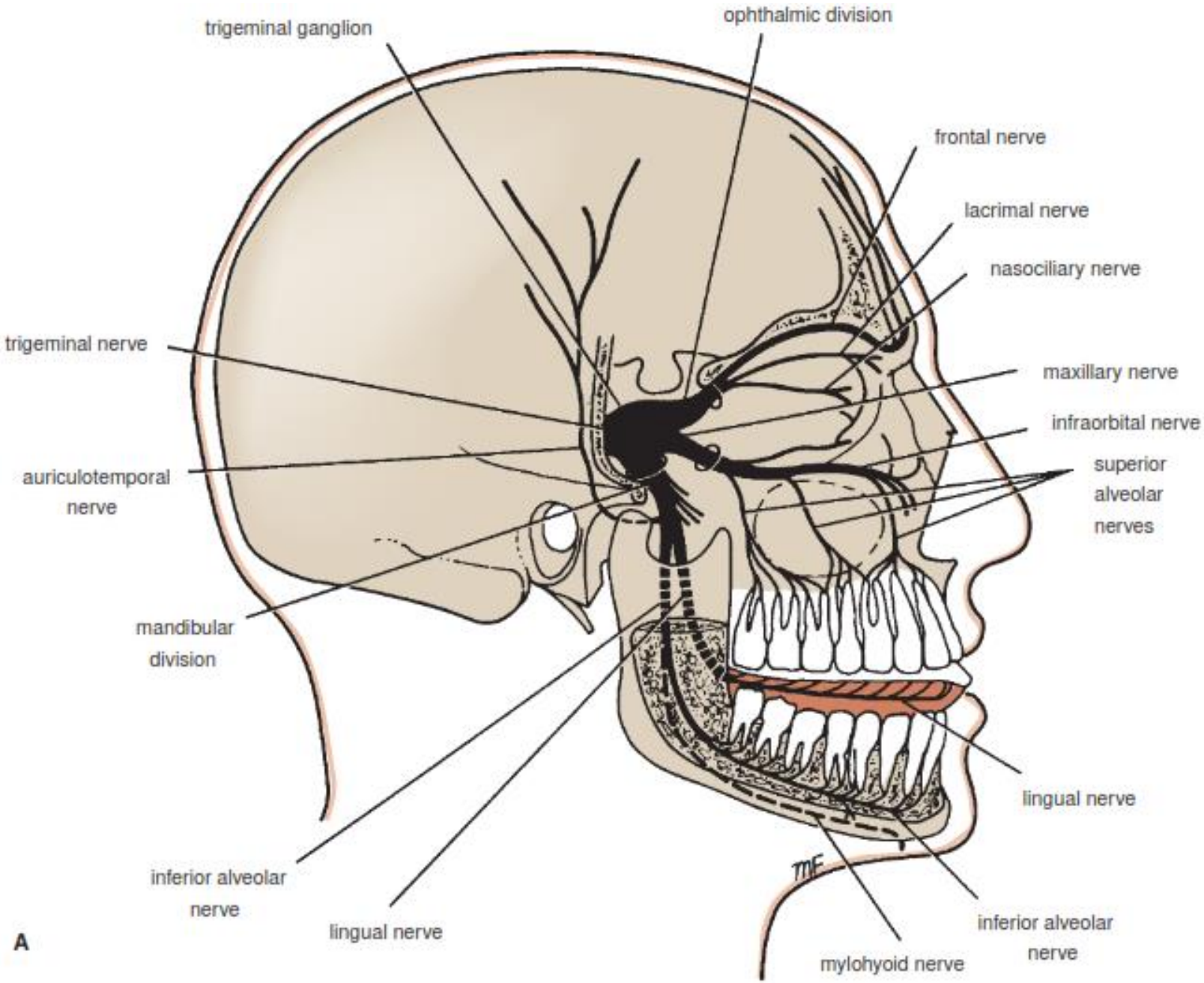
trigeminal ganglion
ophthalmic division
frontal nerve
lacrimal nerve
nasociliary nerve
trigeminal nerve
maxillary nerve
infraorbital nerve
auriculotemporal nerve
superior alveolar nerves
mandibular division
lingual nerve
inferior alveolar nerve
lingual nerve
TMF
inferior alveolar nerve
mylohyoid nerve
A

Maxillary Nerve (V2)

It is the second branch of the trigeminal nerve; it is pure sensory. It leaves the cranial cavity through foramen rotundum and crosses the pterygopalatine fossa to enter the orbit through the inferior orbital fissure and pass through the infraorbital canal. Then, it enters the face through the infraorbital foramen, where it continues as the infraorbital nerve.

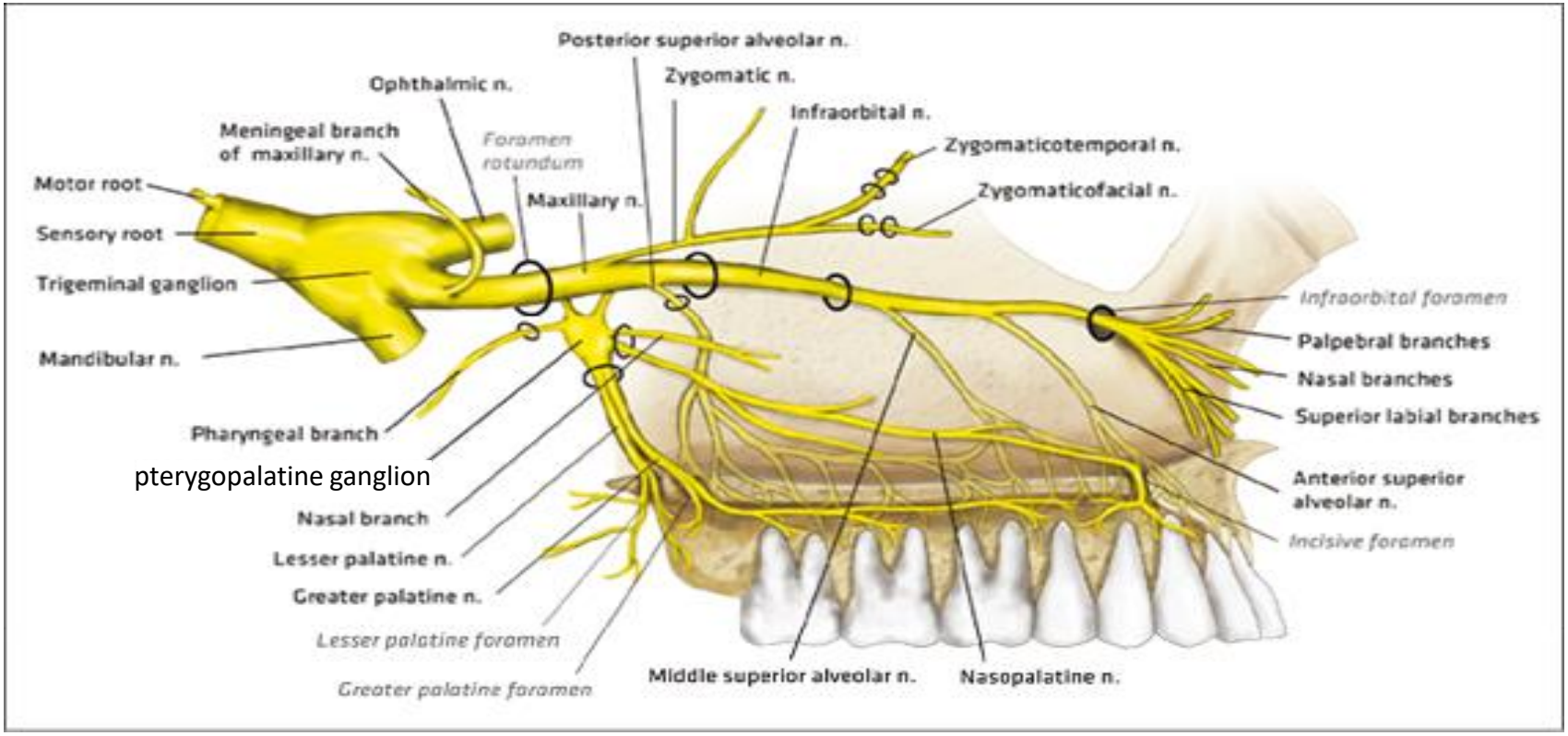

Branches

- **Meningeal branches**
- **Zygomatic branch** (Fig. 11.19), which divides into the zygomaticotemporal and the zygomaticofacial nerves that supply the skin of the face. The zygomaticotemporal branch gives parasympathetic secretomotor fibers to the lacrimal gland via the lacrimal nerve.
- **Ganglionic branches,** which are two short nerves that suspend the pterygopalatine ganglion in the pterygopalatine fossa (Fig. 11.19). They contain sensory fibers that have passed through the ganglion from the nose, the palate, and the pharynx. They also contain postganglionic parasympathetic fibers that are going to the lacrimal gland.
- **Posterior superior alveolar nerve** (Fig. 11.19), which supplies the maxillary sinus as well as the upper molar teeth and adjoining parts of the gum and the cheek
- **Middle superior alveolar nerve** (Fig. 11.19), which supplies the maxillary sinus as well as the upper premolar teeth, the gums, and the cheek
- **Anterior superior alveolar nerve** (Fig. 11.19), which supplies the maxillary sinus as well as the upper canine and the incisor teeth

- After it exit to the face → Terminal branches in the face: palpebral, nasal and labial.

Pterygopalatine Ganglion

The pterygopalatine ganglion is a parasympathetic ganglion, which is suspended from the maxillary nerve in the pterygopalatine fossa (Fig. 11.19). It is secretomotor to the lacrimal and nasal glands

Branches

- **Orbital branches,** which enter the orbit through the inferior orbital fissure
- **Greater and lesser palatine nerves** (Fig. 11.19), which supply the palate, the tonsil, and the nasal cavity
- **Pharyngeal branch,** which supplies the roof of the nasopharynx

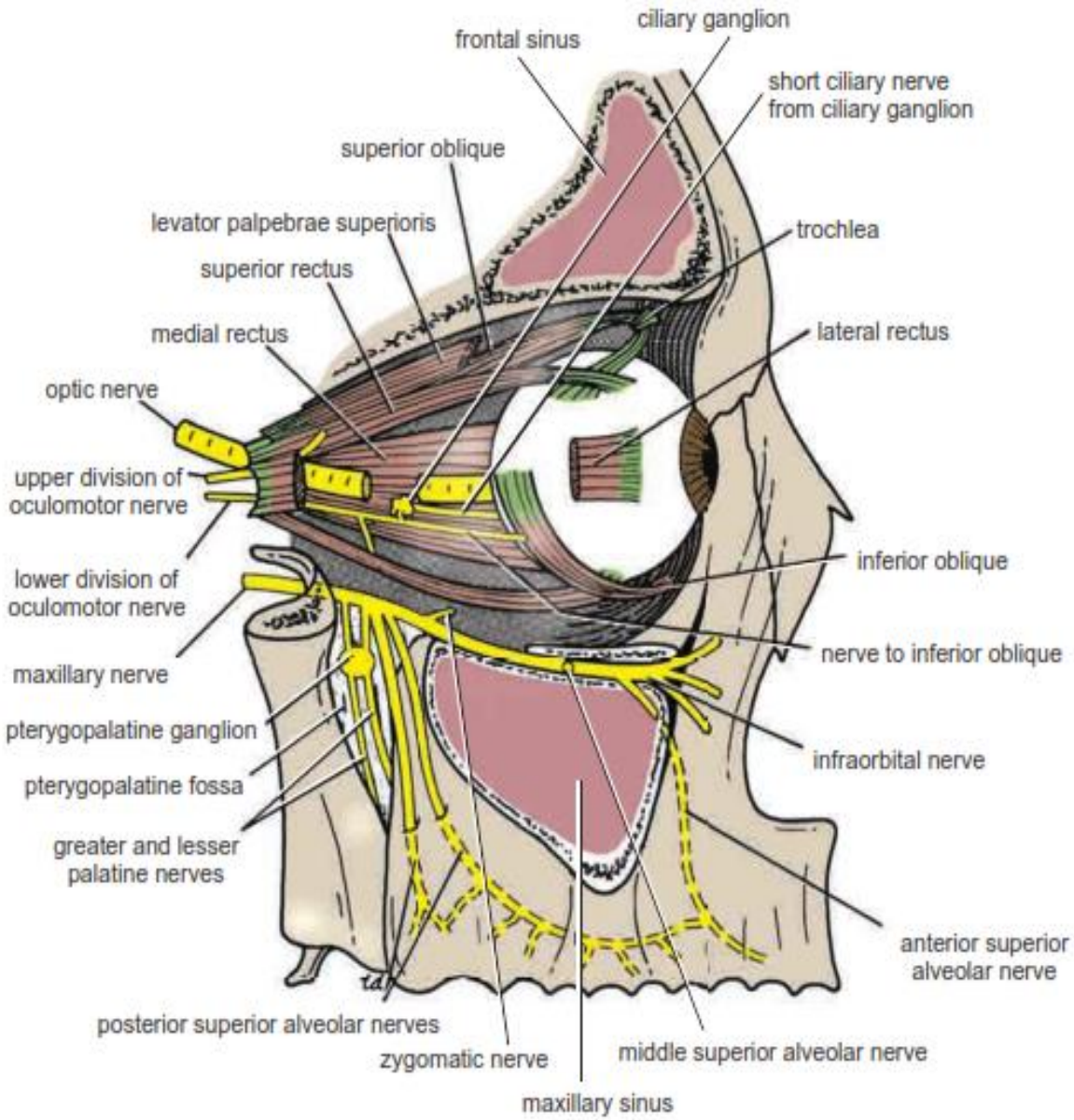

FIGURE 11.19 Muscles and nerves of the right orbit viewed from the lateral side. The maxillary nerve and the pterygopalatine ganglion are also shown.

Mandibular Nerve (V3)

It is one of the three divisions of the trigeminal nerve. - It is a mixed nerve, it is formed of a large sensory root and a small motor root, which unite just below the foramen ovale to form a short trunk, which descends and divides into anterior and posterior divisions

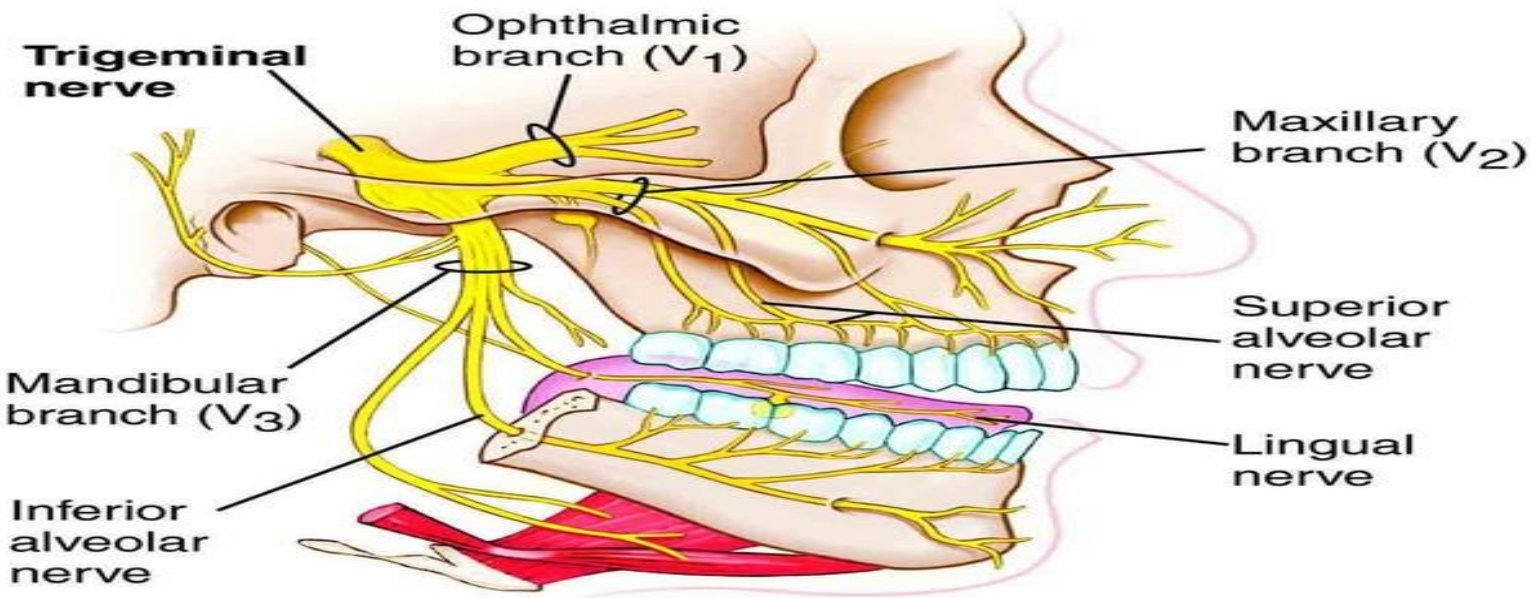

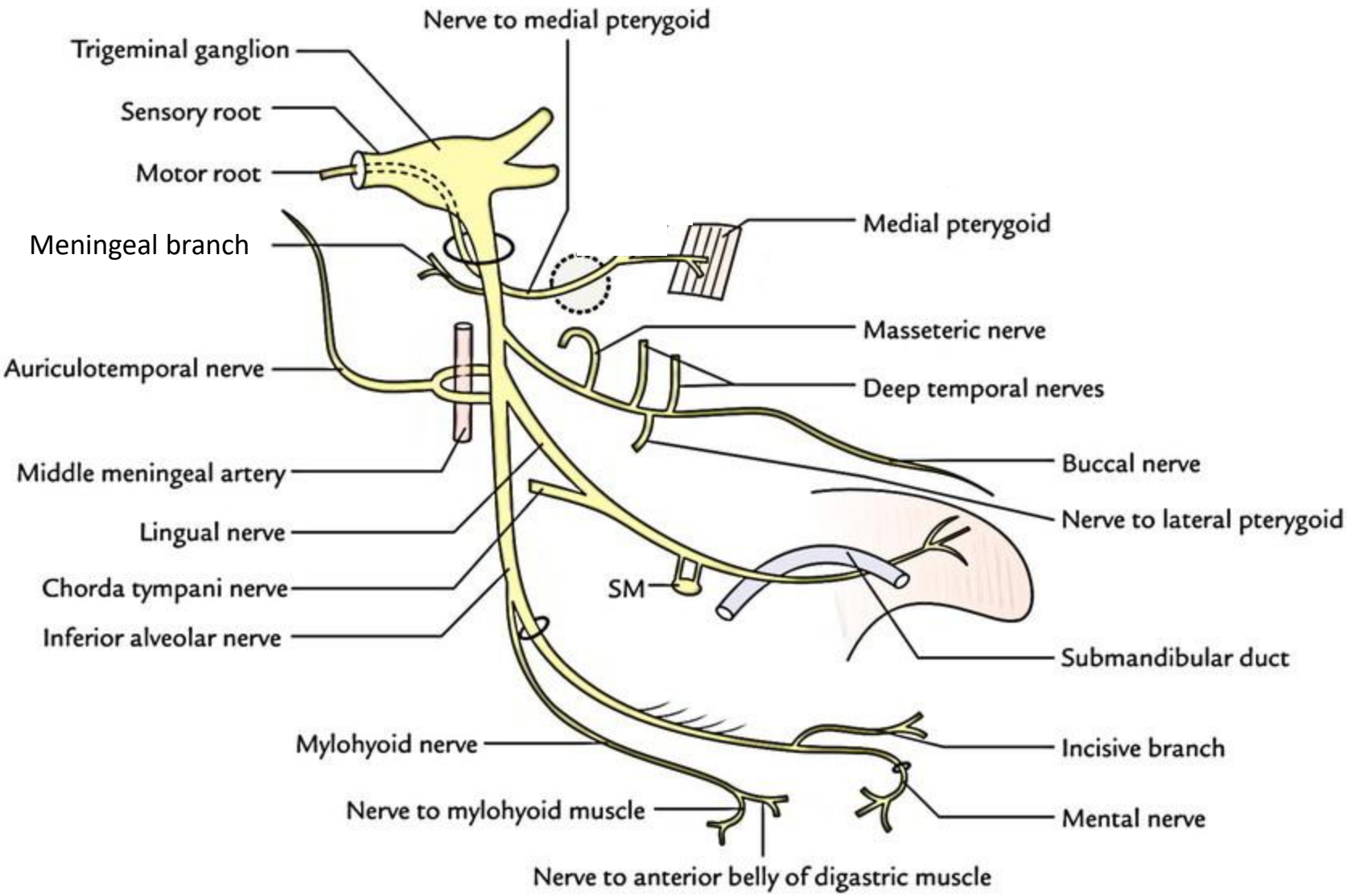
Nerve to medial pterygoid
Trigeminal ganglion
Sensory root
Motor root
Meningeal branch
Medial pterygoid
Masseteric nerve
Auriculotemporal nerve
Deep temporal nerves
Buccal nerve
Middle meningeal artery
Nerve to lateral pterygoid
Lingual nerve
Chorda tympani nerve
SM
Inferior alveolar nerve
Submandibular duct
Mylohyoid nerve
Incisive branch
Nerve to mylohyoid muscle
Mental nerve
Nerve to anterior belly of digastric muscle

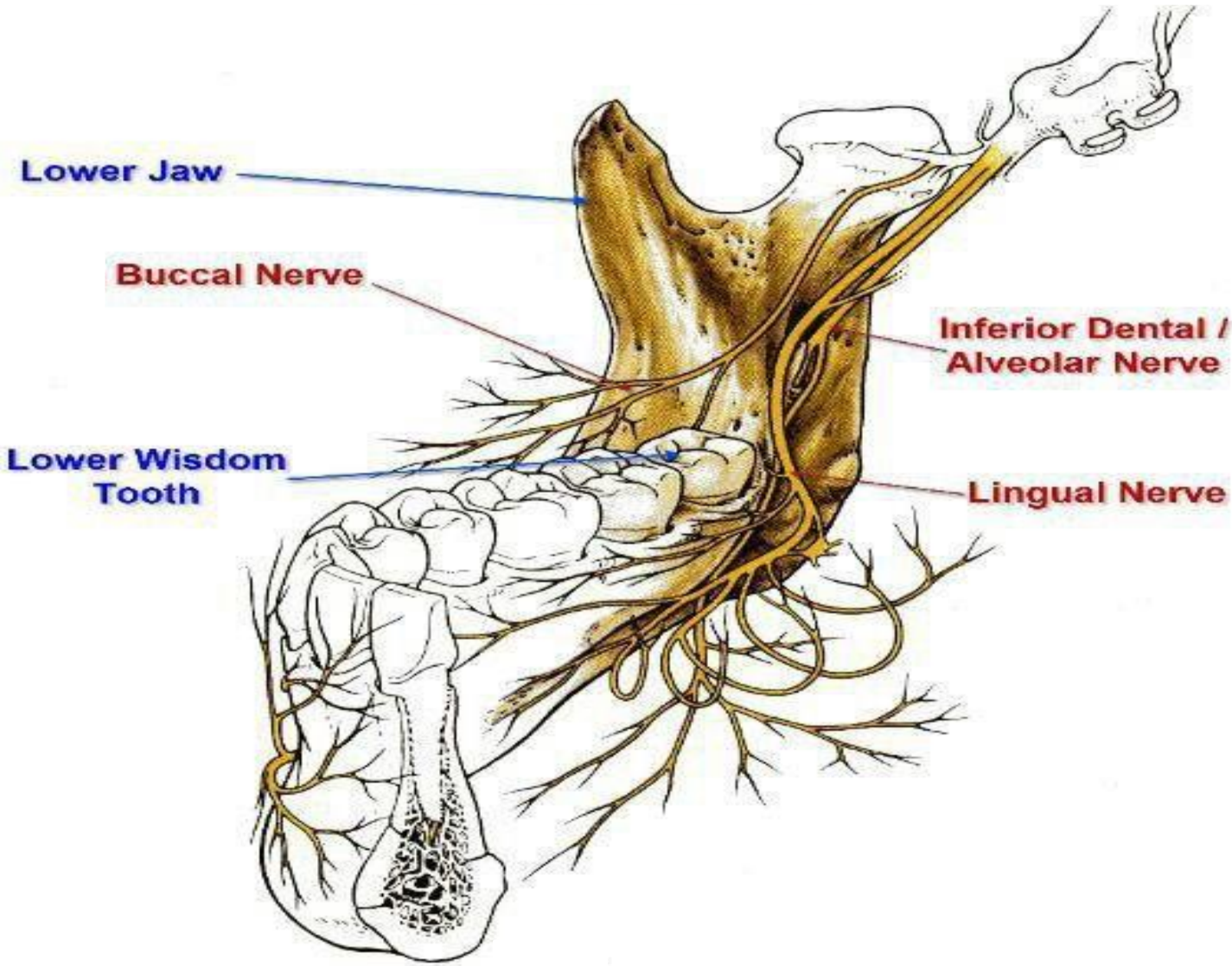
Lower Jaw
Buccal Nerve
Inferior Dental /
Alveolar Nerve
Lower Wisdom
Tooth
Lingual Nerve

Branches from the Main Trunk of the Mandibular Nerve

- **Meningeal branch**
- **Nerve to the medial pterygoid muscle,** which supplies not only the medial pterygoid, but also the tensor veli palatini muscle.

Branches from the Anterior Division of the Mandibular Nerve

- **Masseteric nerve** to the masseter muscle (Fig. 11.36)
- **Deep temporal nerves** to the temporalis muscle (Fig. 11.36)
- **Nerve to the lateral pterygoid muscle**

- **Buccal nerve** to the skin and the mucous membrane of the cheek (Fig. 11.36). The buccal nerve **does not supply the buccinator muscle** (which is supplied by the facial nerve), and it is the **only sensory branch** of the anterior division of the mandibular nerve.

Branches from the Posterior Division of the Mandibular Nerve

- **Auriculotemporal nerve,** which supplies the skin of the auricle (Fig. 11.66), the external auditory meatus, the temporomandibular joint, and the scalp. This nerve also conveys postganglionic parasympathetic secretomotor fibers → to the parotid salivary gland.
- **Lingual nerve,** which descends in front of the inferior alveolar nerve and enters the mouth (Figs. 11.36 and 11.66). It then runs forward on the side of the tongue and crosses the submandibular duct. In its course, it is joined by the **chorda tympani nerve** (Figs. 11.36 and 11.66), and it supplies the mucous membrane of the anterior two thirds of the tongue and the floor of the mouth.
- **Inferior alveolar nerve** (Figs. 11.36 and 11.66), which enters the mandibular canal to supply the teeth of the lower jaw and emerges through the mental foramen (mental nerve) to supply the skin of the chin (Fig. 11.50). Before entering the canal, it gives off the **mylohyoid nerve** (Fig. 11.36), which supplies the mylohyoid muscle and the anterior belly of the digastric muscle.
- **Communicating branch,** which frequently runs from the inferior alveolar nerve to the lingual nerve

Nerve	Components	Function	Opening in Skull
I. Olfactory	Sensory	Smell	Openings in cribriform plate of ethmoid
II. Optic	Sensory	Vision	Optic canal
III. Oculomotor	Motor	Lifts upper eyelid, turns eyeball upward, downward, and medially; constricts pupil; accommodates eye	Superior orbital fissure
IV. Trochlear	Motor	Assists in turning eyeball downward and laterally	Superior orbital fissure
V. Trigeminal			
Ophthalmic division	Sensory	Cornea, skin of forehead, scalp, eyelids, and nose; also mucous membrane of paranasal sinuses and nasal cavity	Superior orbital fissure
Maxillary division	Sensory	Skin of face over maxilla and the upper lip; teeth of upper jaw; mucous membrane of nose, the maxillary air sinus, and palate	Foramen rotundum
Mandibular division	Motor	Muscles of mastication, mylohyoid, anterior belly of digastric, tensor veli palatini, and tensor tympani	Foramen ovale
	Sensory	Skin of cheek, skin over mandible, lower lip, and side of head; teeth of lower jaw and temporomandibular joint; mucous membrane of mouth and anterior two thirds of tongue	
VI. Abducent	Motor	Lateral rectus muscle: turns eyeball laterally	Superior orbital fissure

THANK YOU

CRANIAL NERVES – PART 2

PREPARED BY:

Dr. REYADH AL-RASHIDI

Facial Nerve (VII)

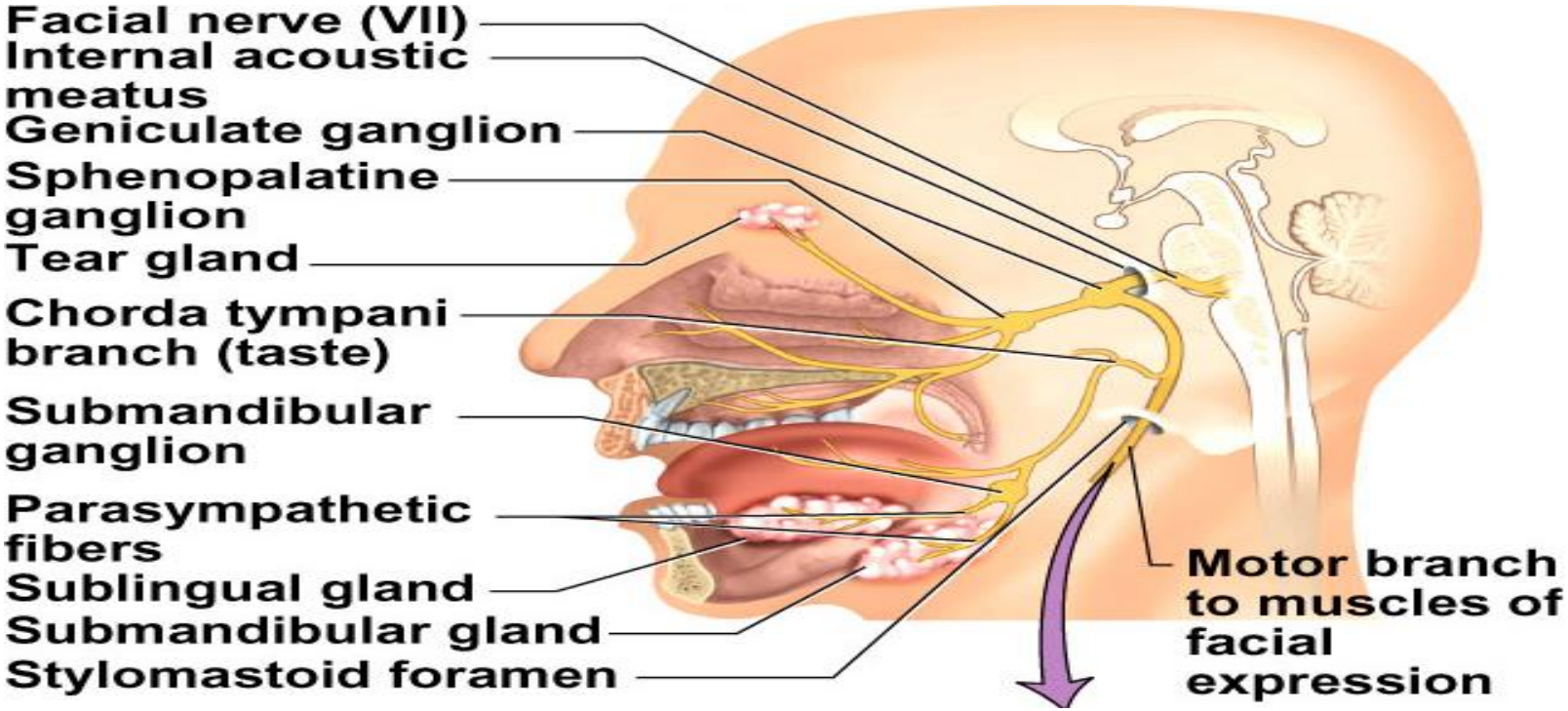

The facial nerve has a motor root and a sensory root, The nerve emerges on the anterior surface of the **hindbrain between the pons and the medulla oblongata** and enter the internal acoustic meatus in the temporal bone and exit from the stylomastoid foramen.

Branches are :

1. The greater petrosal nerve provides parasympathetic innervation to several glands, including the nasal glands, the palatine glands, and the pharyngeal gland.
2. The nerve to stapedius provides motor innervation for the stapedius muscle in middle ear
3. The **chorda tympani** provides parasympathetic innervation to the sublingual and submandibular glands, as well as mucus membrane (special sensory taste) fibers for the anterior two thirds of the tongue
4. Branch to posterior belly of digastric muscle as well as the stylohyoid muscle
5. Five major facial branches to the muscles of facial expression
    1. Temporal branch
    2. Zygomatic branch
    3. Buccal branch
    4. Marginal mandibular branch
    5. Cervical branch

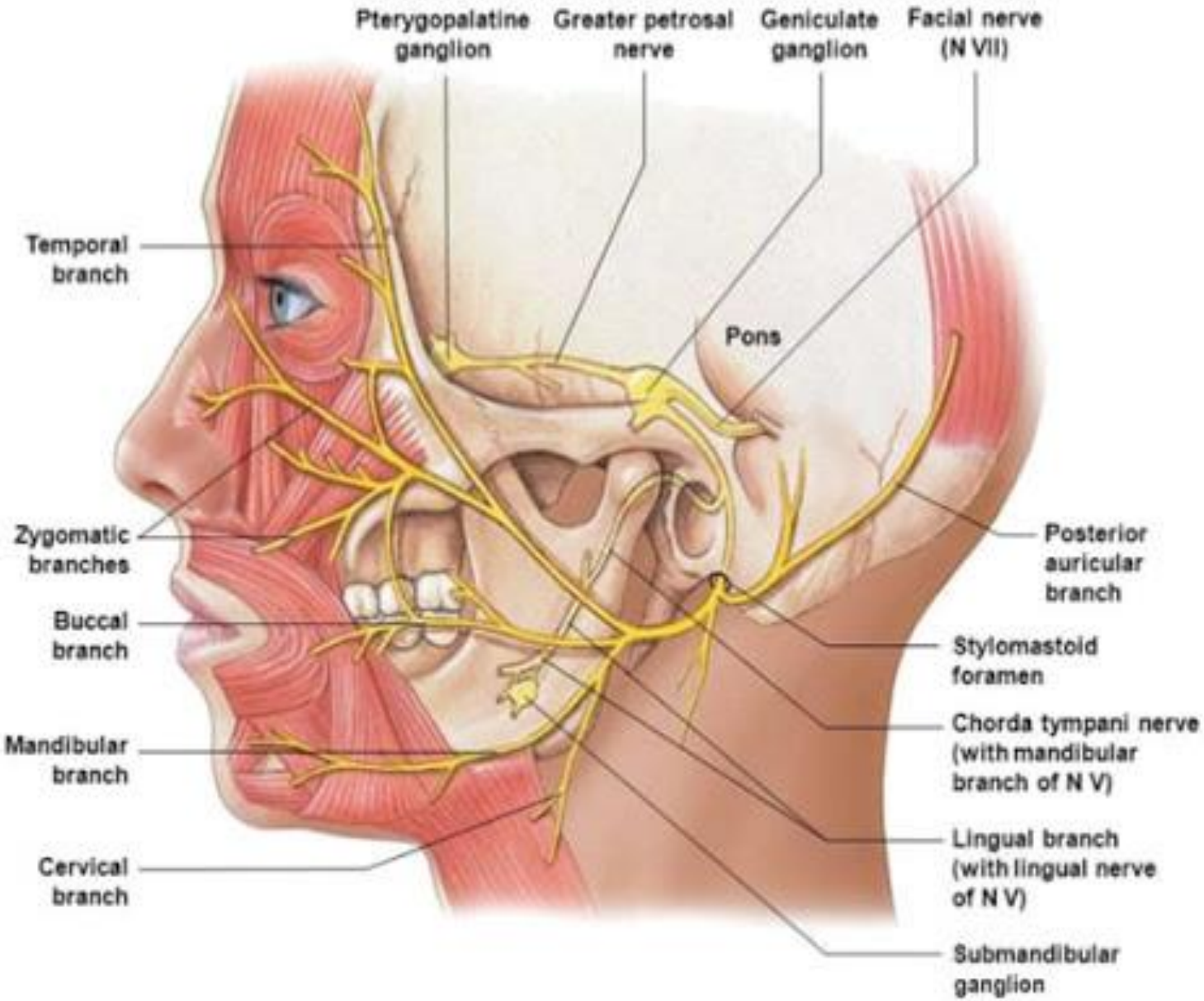
Pterygopalatine ganglion
Greater petrosal nerve
Geniculate ganglion
Facial nerve (N VII)
Temporal branch
Pons
Zygomatic branches
Posterior auricular branch
Buccal branch
Stylomastoid foramen
Chorda tympani nerve (with mandibular branch of N V)
Mandibular branch
Lingual branch (with lingual nerve of N V)
Cervical branch
Submandibular ganglion

Vestibulocochlear Nerve (VIII)

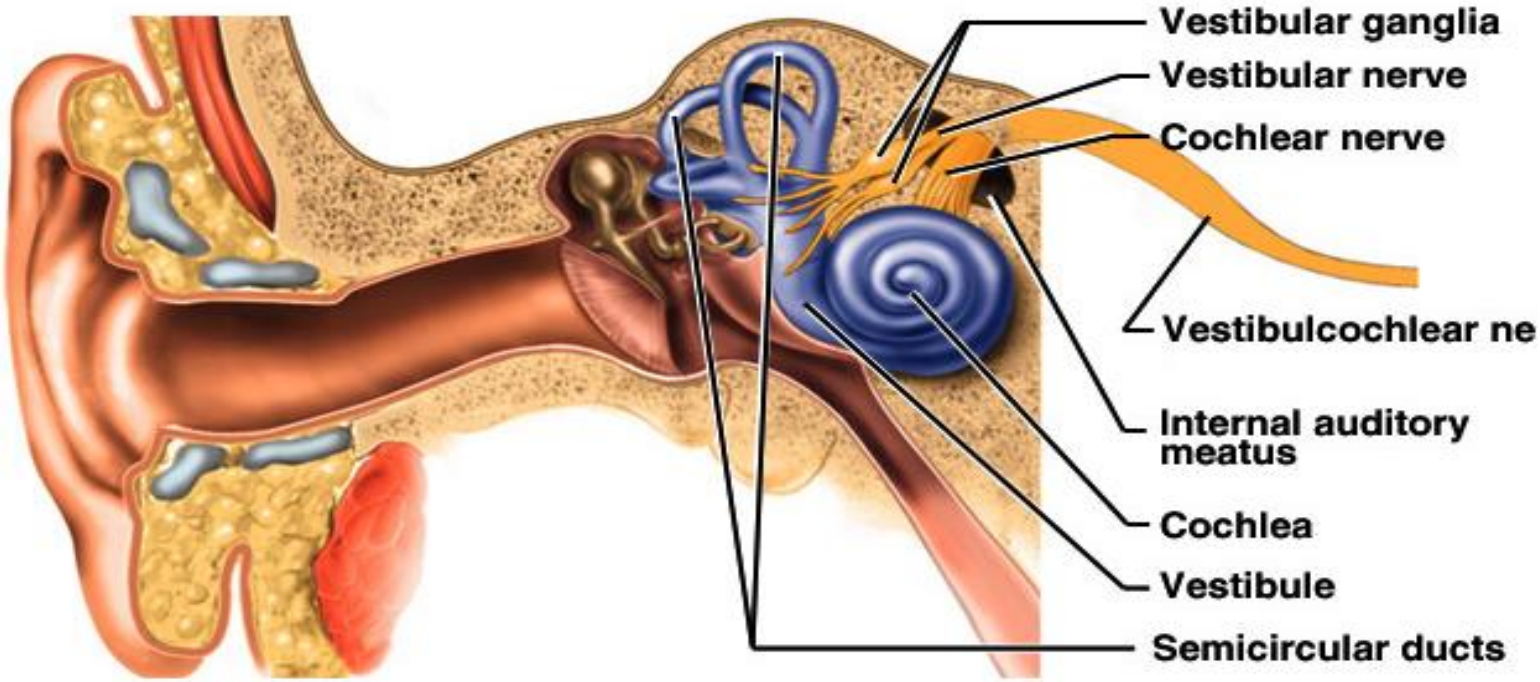

The cochlear nerve travels away from the cochlea of the inner ear and The vestibular nerve travels from the vestibular system of the inner ear. They unite to form the Vestibulocochlear nerve and enter the internal acoustic meatus . They reach the thalamus and then to the cerebral cortex. It provides sensory for hearing and balance.

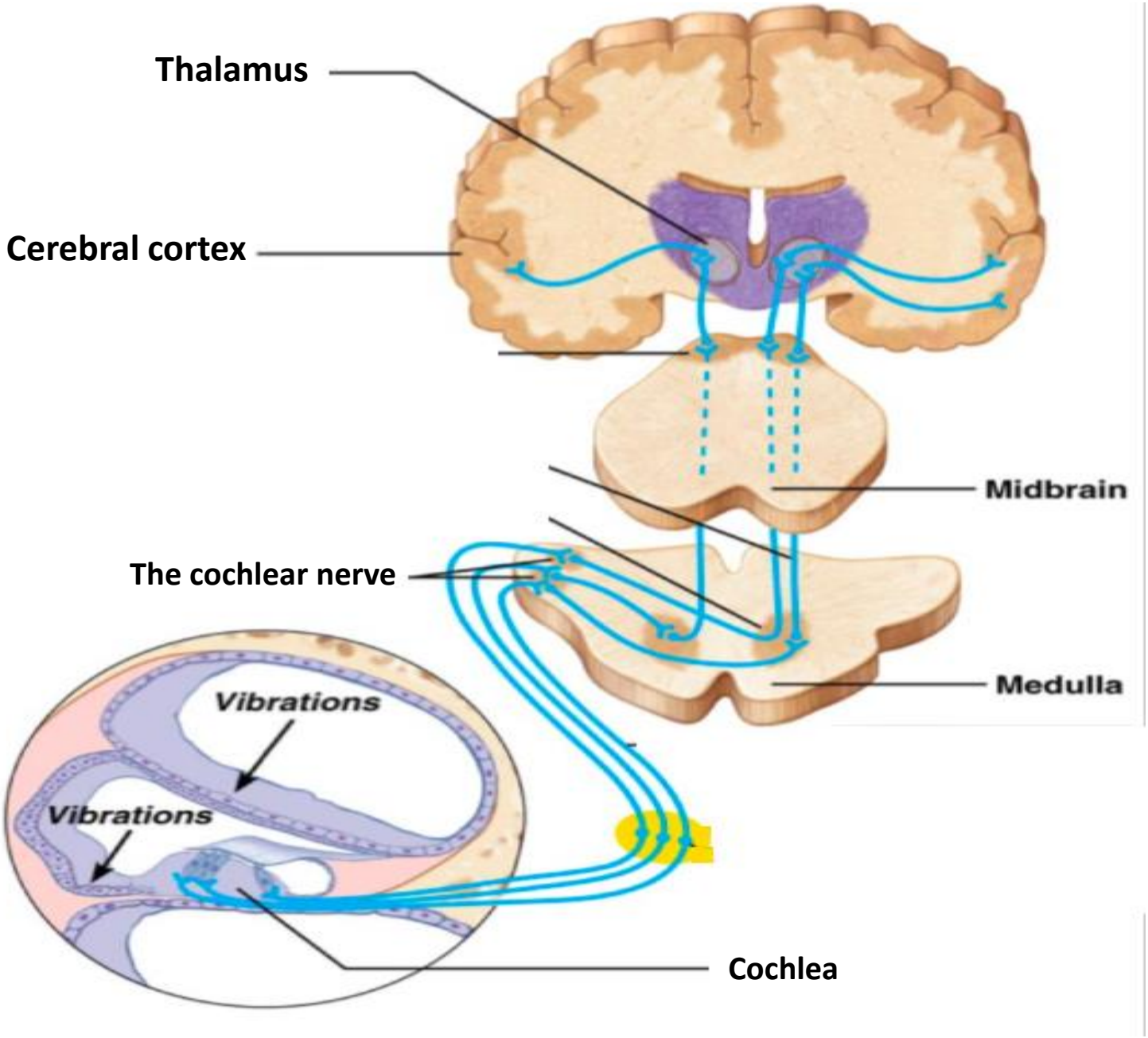
Thalamus
Cerebral cortex
Midbrain
The cochlear nerve
Medulla
Vibrations
Vibrations
Cochlea

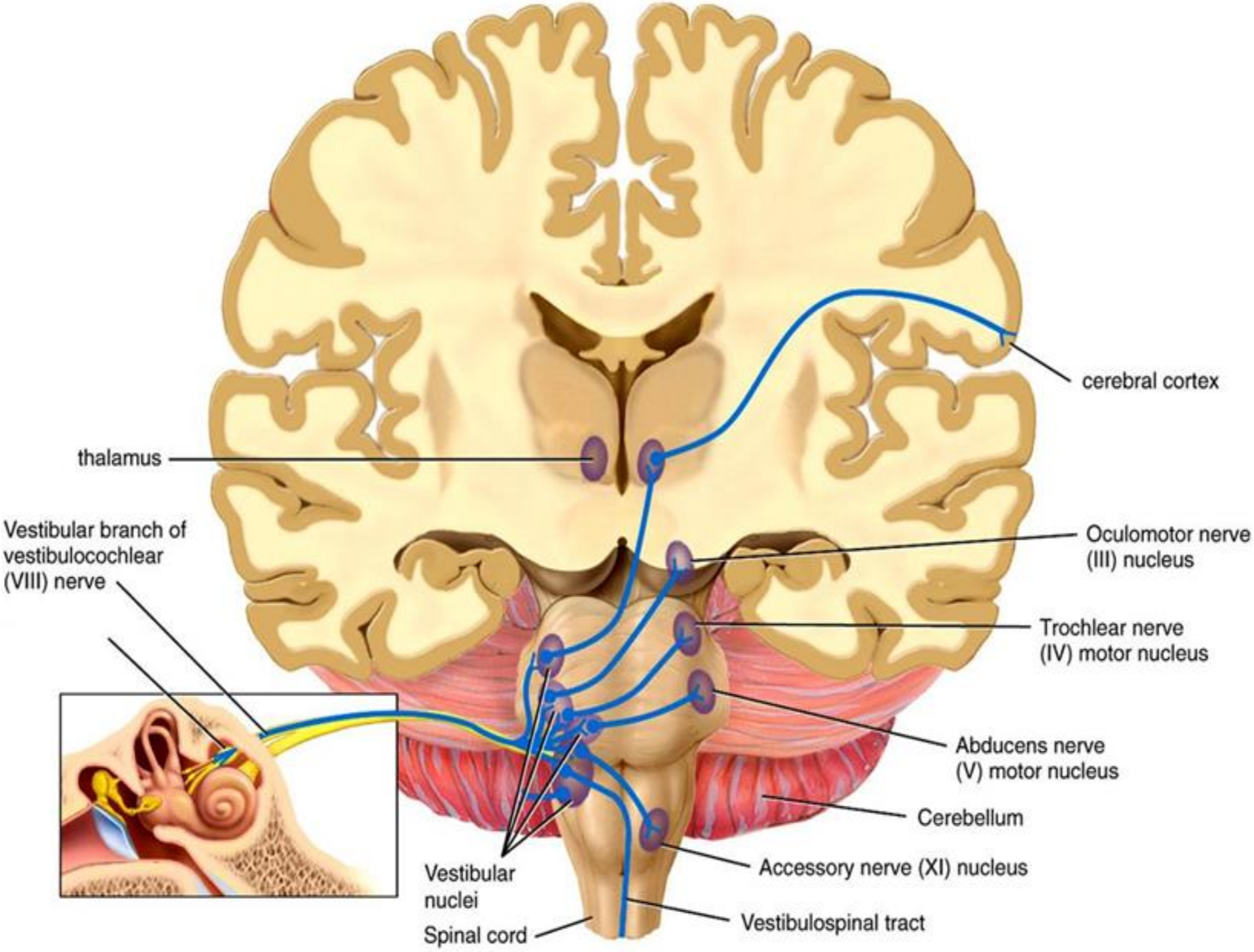
cerebral cortex
thalamus
Vestibular branch of vestibulocochlear (VIII) nerve
Oculomotor nerve (III) nucleus
Trochlear nerve (IV) motor nucleus
Abducens nerve (V) motor nucleus
Cerebellum
Accessory nerve (XI) nucleus
Vestibular nuclei
Spinal cord
Vestibulospinal tract

Glossopharyngeal Nerve (IX)

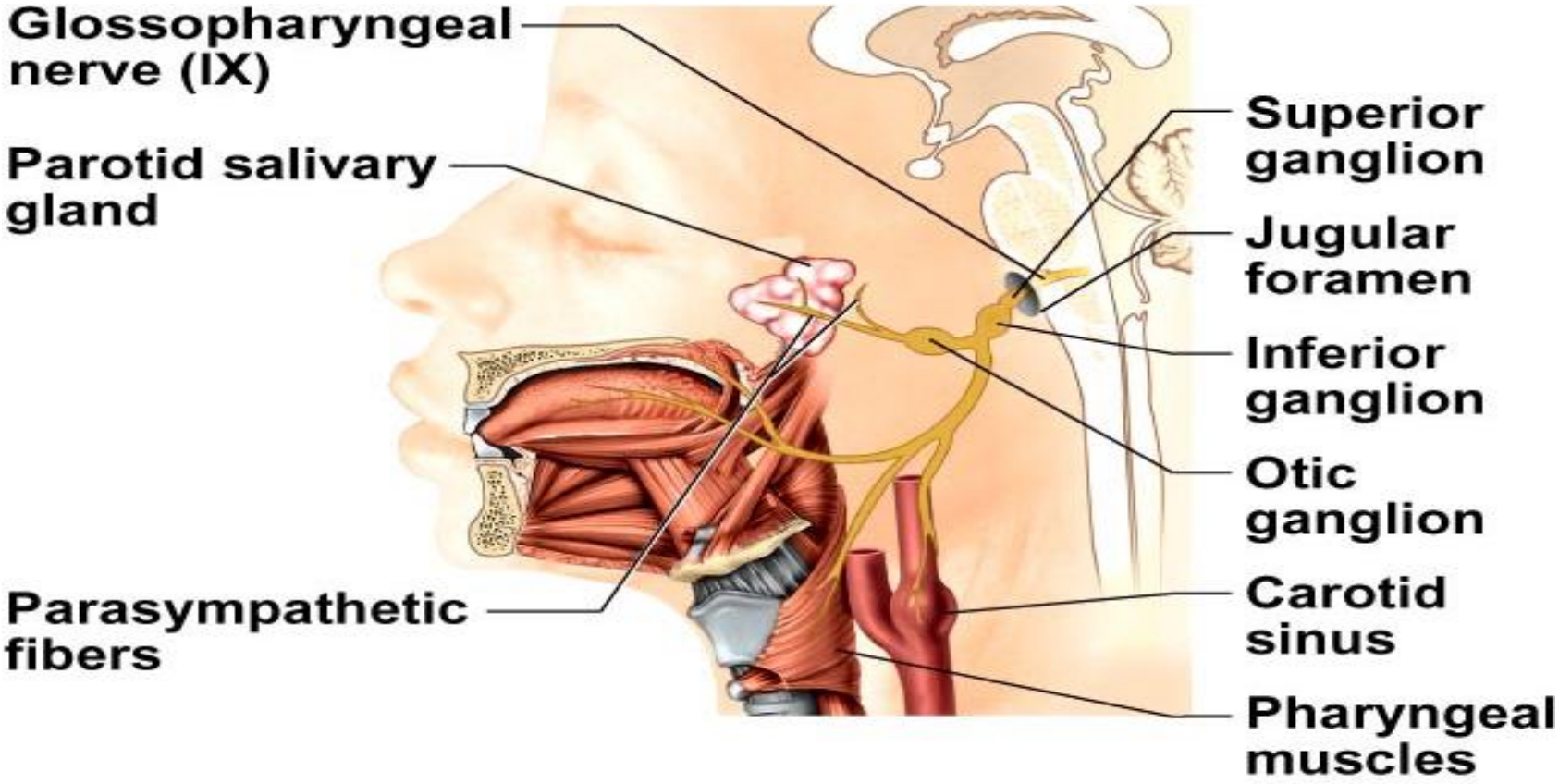

- Provides control over swallowing, salivation, gagging, sensations from posterior 1/3 of tongue.

The glossopharyngeal nerve is a motor and sensory nerve. It emerges from the anterior surface of the **medulla oblongata**. It passes in the posterior cranial fossa and leaves the skull by passing through the jugular foramen. Branches are:

1. Lingual branch passes to the mucous membrane (special sensory for taste) of the posterior third of the tongue.
2. stylopharyngeal nerve.
3. Carotid branch which carries impulses from the baroreceptors in the carotid sinus to the vasomotor center in the brainstem (to help maintain a more consistent blood pressure)
4. The glossopharyngeal nerve contributes in the formation of the pharyngeal plexus together with the vagus nerve.

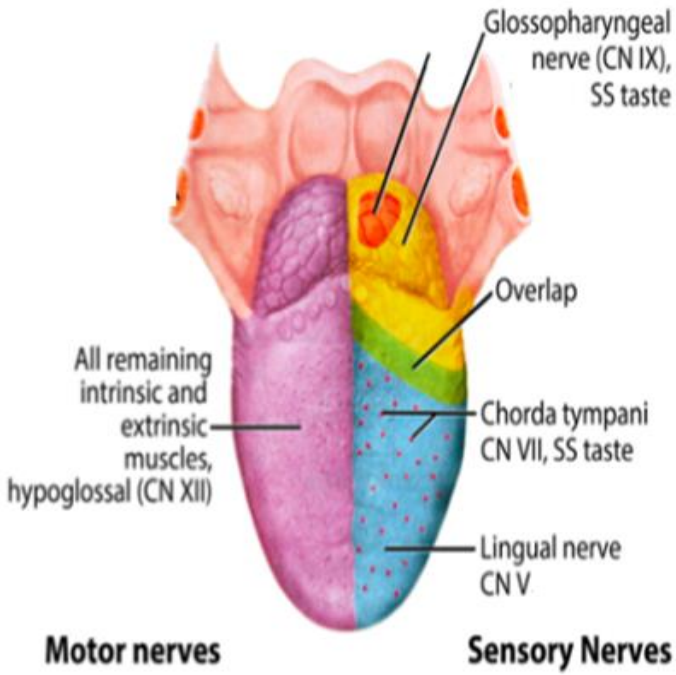
Glossopharyngeal nerve (CN IX), SS taste
Overlap
All remaining intrinsic and extrinsic muscles, hypoglossal (CN XII)
Chorda tympani CN VII, SS taste
Lingual nerve CN V
Motor nerves
Sensory Nerves

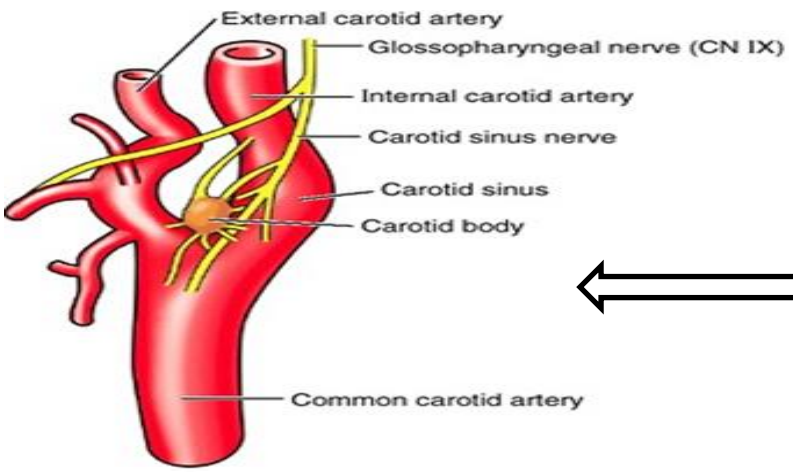
External carotid artery
Glossopharyngeal nerve (CN IX)
Internal carotid artery
Carotid sinus nerve
Carotid sinus
Carotid body
Common carotid artery

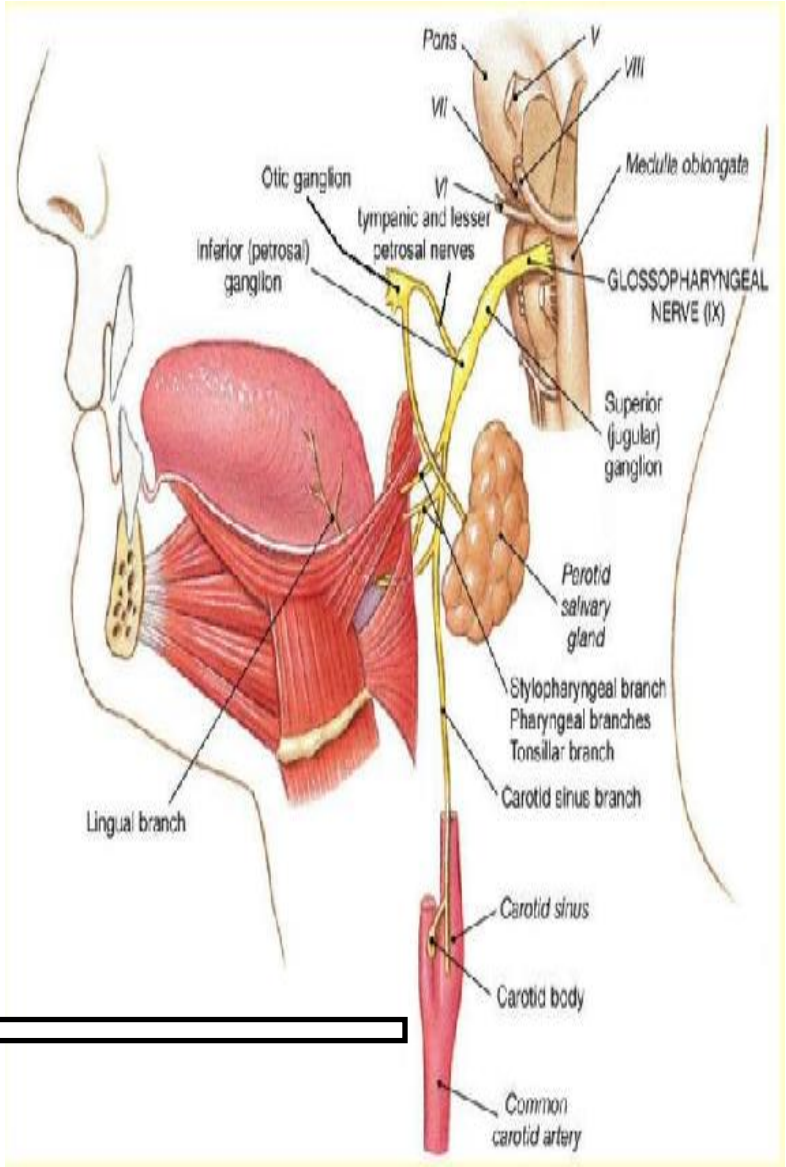
Pons
V
VIII
VII
Medulla oblongata
Otic ganglion
VI
tympanic and lesser petrosal nerves
Inferior (petrosal) ganglion
GLOSSOPHARYNGEAL NERVE (IX)
Superior (jugular) ganglion
Parotid salivary gland
Stylopharyngeal branch
Pharyngeal branches
Tonsillar branch
Carotid sinus branch
Lingual branch
Carotid sinus
Carotid body
Common carotid artery

Pharyngeal plexus

The glossopharyngeal nerve and the vagus nerve contributes in the formation of the pharyngeal plexus

Sensory

The pharyngeal plexus provides sensory innervation of the oropharynx and laryngopharynx. (The nasopharynx is innervated by CN V_2).

Motor

The pharyngeal plexus innervates all the muscles of the pharynx (except stylopharyngeus, which is innervated directly by a branch of CN IX). This includes the following muscles: palatopharyngeus, **palatoglossus**, musculus uvulae, salpingopharyngeus superior pharyngeal constrictor, middle pharyngeal constrictor and inferior pharyngeal constrictor.

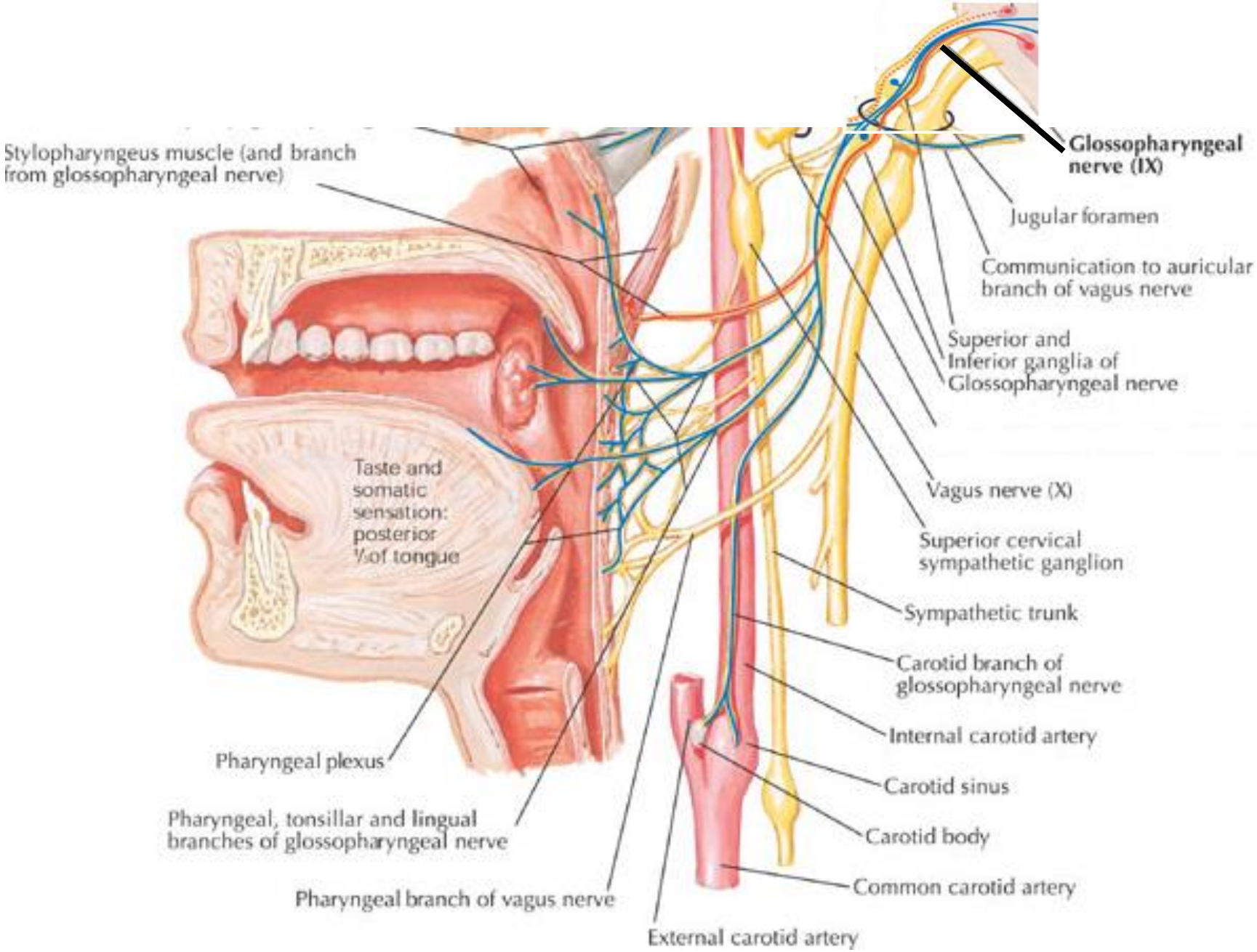
Stylopharyngeus muscle (and branch from glossopharyngeal nerve)
Glossopharyngeal nerve (IX)
Jugular foramen
Communication to auricular branch of vagus nerve
Superior and Inferior ganglia of Glossopharyngeal nerve
Taste and somatic sensation: posterior ⅓ of tongue
Vagus nerve (X)
Superior cervical sympathetic ganglion
Sympathetic trunk
Carotid branch of glossopharyngeal nerve
Internal carotid artery
Carotid sinus
Carotid body
Common carotid artery
Pharyngeal plexus
Pharyngeal, tonsillar and lingual branches of glossopharyngeal nerve
Pharyngeal branch of vagus nerve
External carotid artery

Vagus Nerve (X)

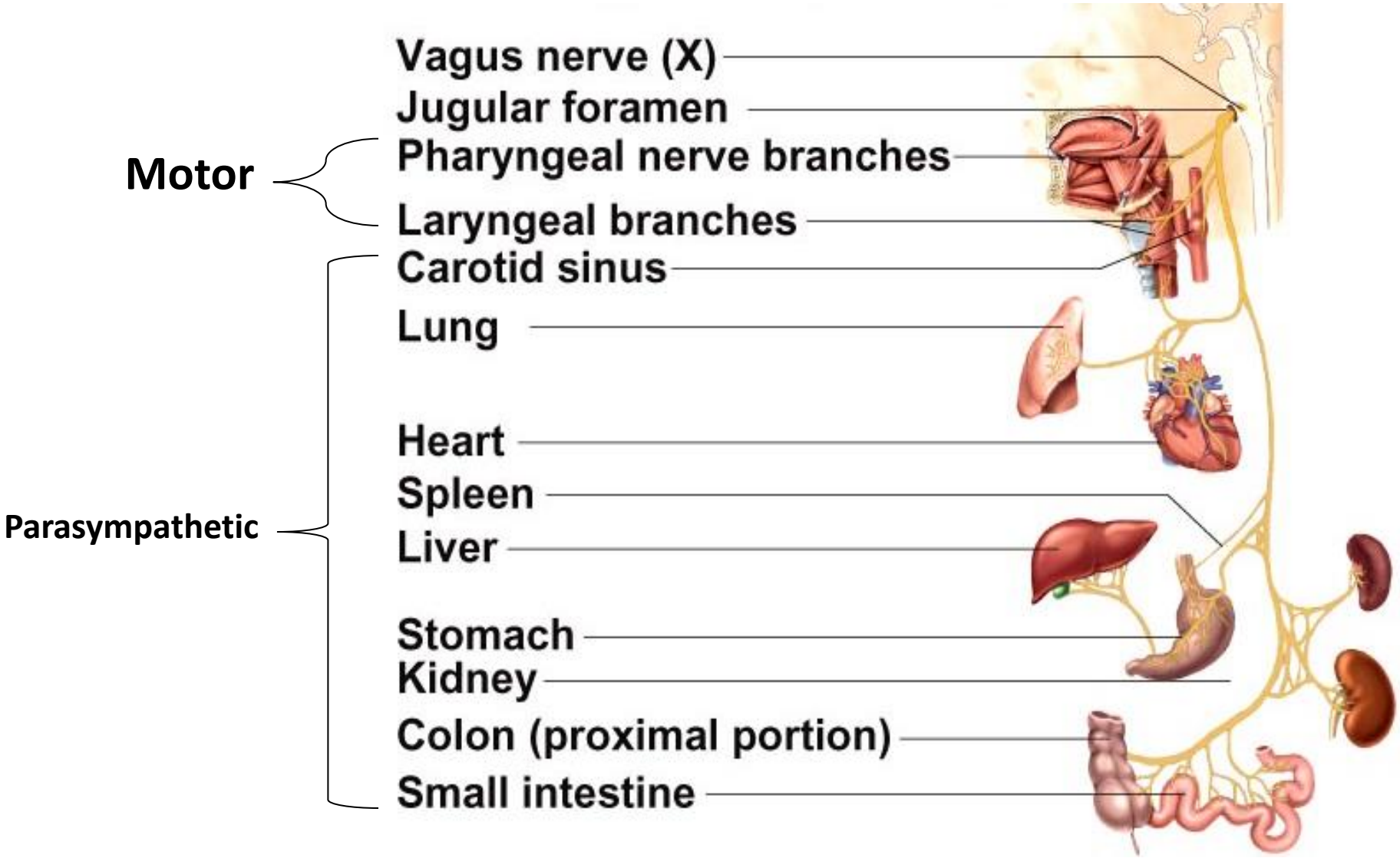

Origin from medulla oblongata, the vagus nerve extends through the jugular foramen, then passes into the carotid sheath between the internal carotid artery and the internal jugular vein down to the neck, chest, and abdomen, where it contributes to the innervation of the viscera, reaching all the way to the colon. Branches:

1. Pharyngeal nerve → Pharyngeal plexus
2. Superior laryngeal nerve → larynx
3. Recurrent laryngeal nerve → larynx (voice)
4. Cardiac branches → heart
5. Pulmonary branches → lung
6. Esophageal branches → Esophagus
7. Gastric branches → Stomach
8. Intestinal branches → small intestine
9. Colonic branches → proximal part of the colon
10. Branches to the kidney
11. Branches to the liver

Accessory Nerve (XI)

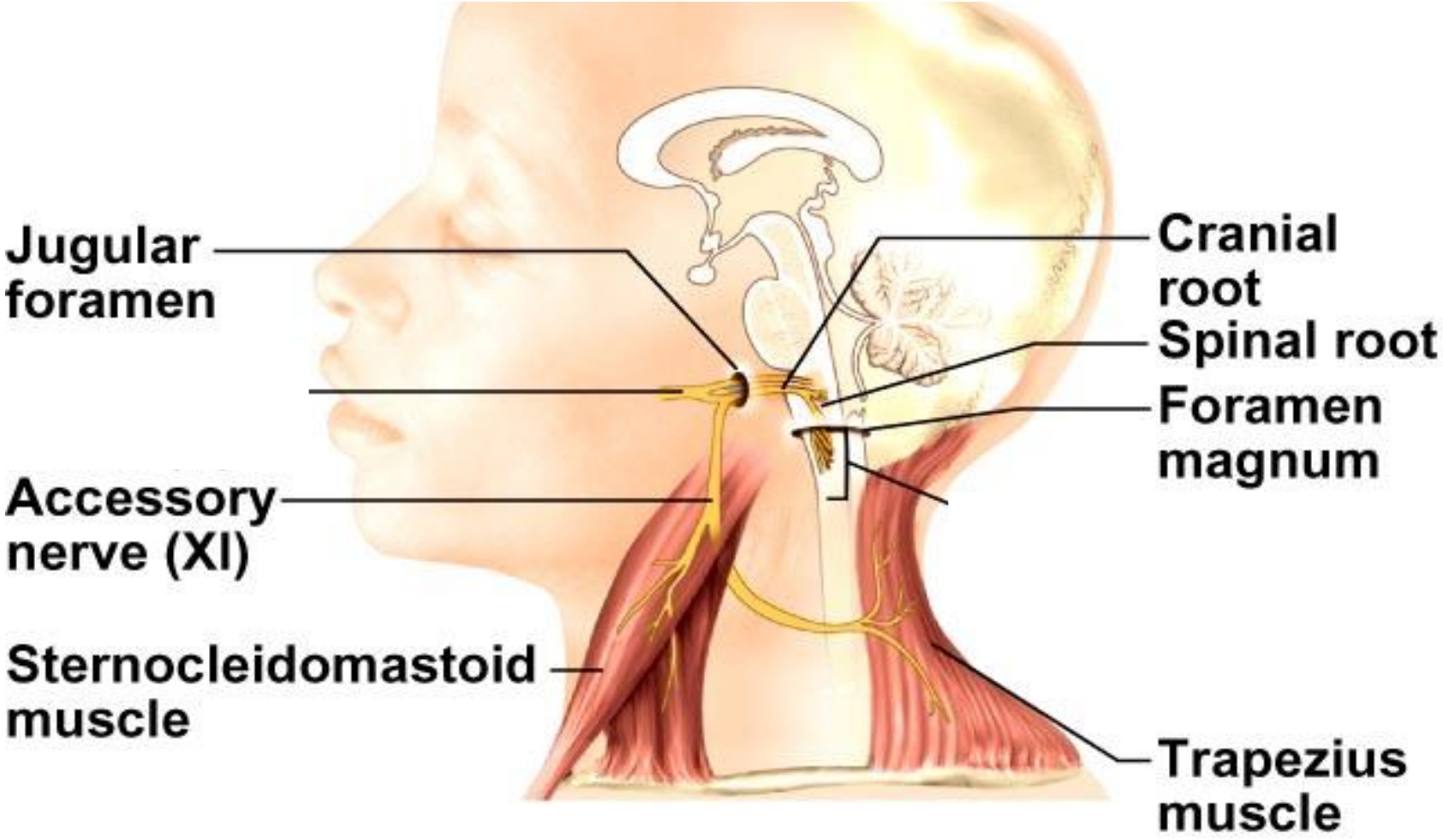

Cranial root of Accessory nerve origins from medulla oblongata and the spinal root origins from spinal cord (C1 – C5 spinal cord segments). The spinal root enters the skull through the foramen magnum then unite with the cranial root. The nerve travels along the inner wall of the skull and exit the skull through jugular foramen. Branches:

1. Nerve to sternocleidomastoid muscle
2. Nerve to trapezius muscle

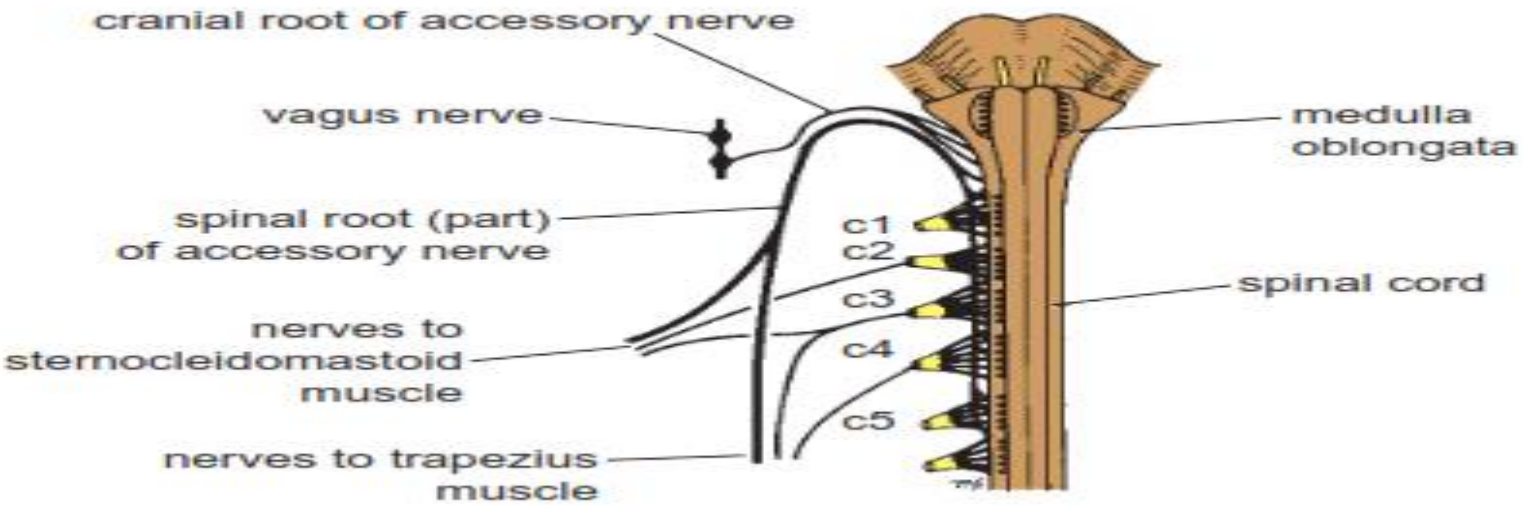

Hypoglossal Nerve(XII)

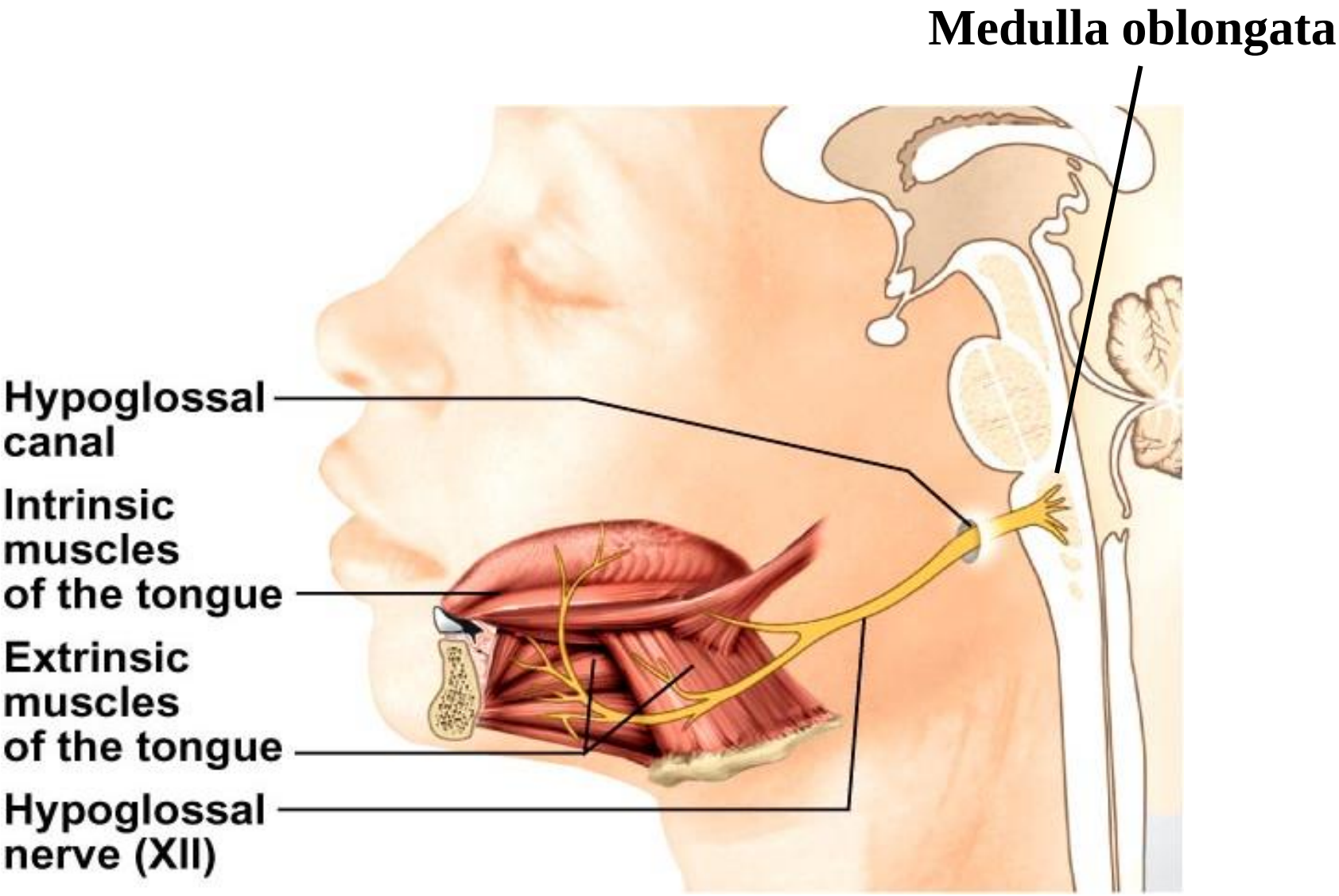

The hypoglossal nerve is a motor nerve. It origins from the medulla oblongata and crosses the posterior cranial fossa, and leaves the skull through the hypoglossal canal.

Branches are :

1. The hypoglossal nerve provides motor control of the extrinsic muscles of the tongue: genioglossus, hyoglossus, styloglossus, and the intrinsic muscles of the tongue. These represent all muscles of the tongue (except the palatoglossus muscle)
2. Nerve to the thyrohyoid muscle
3. Nerve to the geniohyoid muscle
4. Descending branch to ansa cervicalis

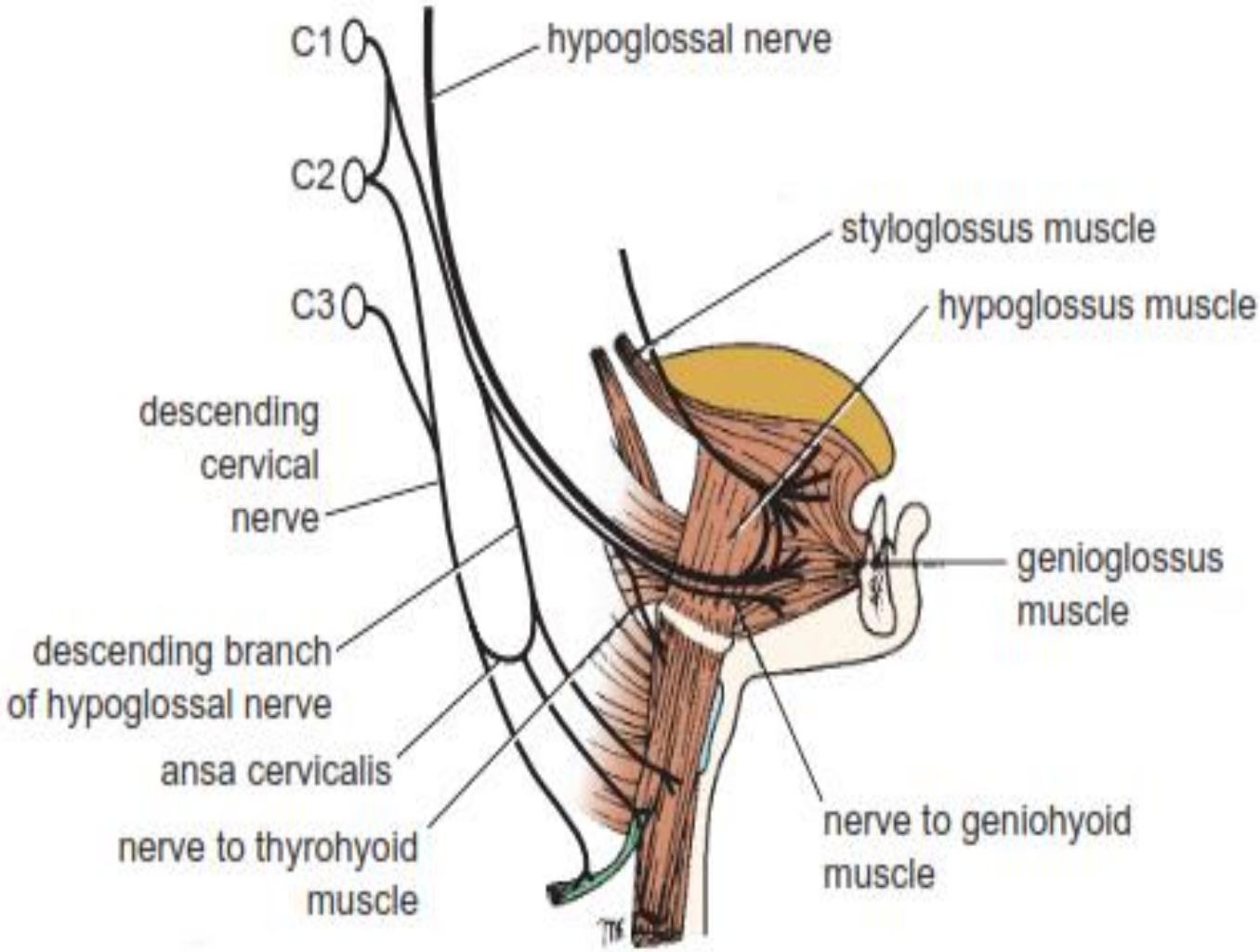
C1
C2
C3
hypoglossal nerve
styloglossus muscle
hypoglossus muscle
descending cervical nerve
genioglossus muscle
descending branch of hypoglossal nerve
ansa cervicalis
nerve to thyrohyoid muscle
nerve to geniohyoid muscle

Ansa cervicalis

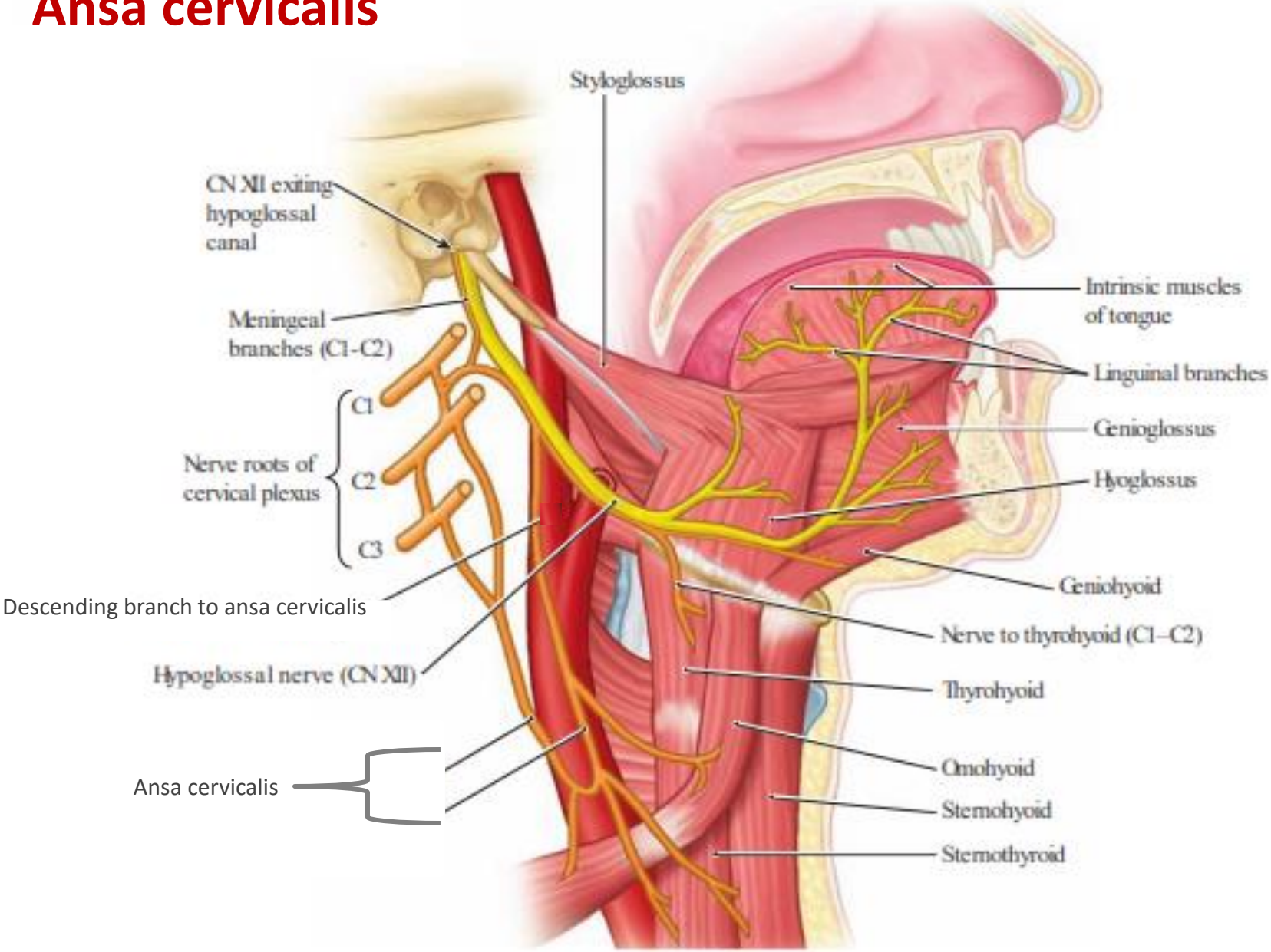

Nerve	Components	Function	Opening in Skull
VII. Facial	Motor	Muscles of face, cheek, and scalp; stapedius muscle of middle ear; stylohyoid; and posterior belly of digastric	Internal acoustic meatus, facial canal, stylomastoid foramen
	Sensory	Taste from anterior two thirds of tongue, floor of mouth, and palate	
	Secretomotor parasympathetic	Submandibular and sublingual salivary glands, lacrimal gland, and glands of nose and palate	
VIII. Vestibulocochlear			
Vestibular	Sensory	Position and movement of head	Internal acoustic meatus
Cochlear	Sensory	Hearing	
IX. Glossopharyngeal	Motor	Stylopharyngeus muscle: assists swallowing	
	Secretomotor parasympathetic	Parotid salivary gland	Jugular foramen
	Sensory	General sensation and taste from posterior third of tongue and pharynx; carotid sinus and carotid body	
X. Vagus	Motor	Constrictor muscles of pharynx and intrinsic muscles of larynx; involuntary muscle of trachea and bronchi, heart, alimentary tract from pharynx to splenic flexure of colon; liver and pancreas	Jugular foramen
	Sensory	Taste from epiglottis and vallecula and afferent fibers from structures named above	
XI. Accessory			
Cranial root	Motor	Muscles of soft palate, pharynx, and larynx	Jugular foramen
Spinal root	Motor	Sternocleidomastoid and trapezius muscles	
XII. Hypoglossal	Motor	Muscles of tongue controlling its shape and movement (except palatoglossus)	Hypoglossal canal

THANK YOU

POSTERIOR TRIANGLE OF THE NECK

PREPARED BY:

Dr. REYADH AL-RASHIDI

Posterior triangle

Boundaries :

- **Anterior** : posterior border of sternomastoid.
- **Posterior :** anterior border of trapezius.
- **Inferior(base) :** intermediate of third of the clavicle
- **Apex :** meeting of trapeziue and sternomastoid

Roof : formed by

- (1) skin; (2) superficial fascia and platysma (3) deep fascia

Floor : formed by the following muslces from above downwards:

(1) levator scapula (2) splenius capitis . (3) Scalenus anterior
(4) Scalenus posterior . (5) scalenus medius.

- **Division of the triangle:** it is subdivided by the inferior belly of mohyoid into:
  - ❶ Occipital triangle : the larger uper part.
  - ❷ Supraclavicular triangle : the smaller lower part.

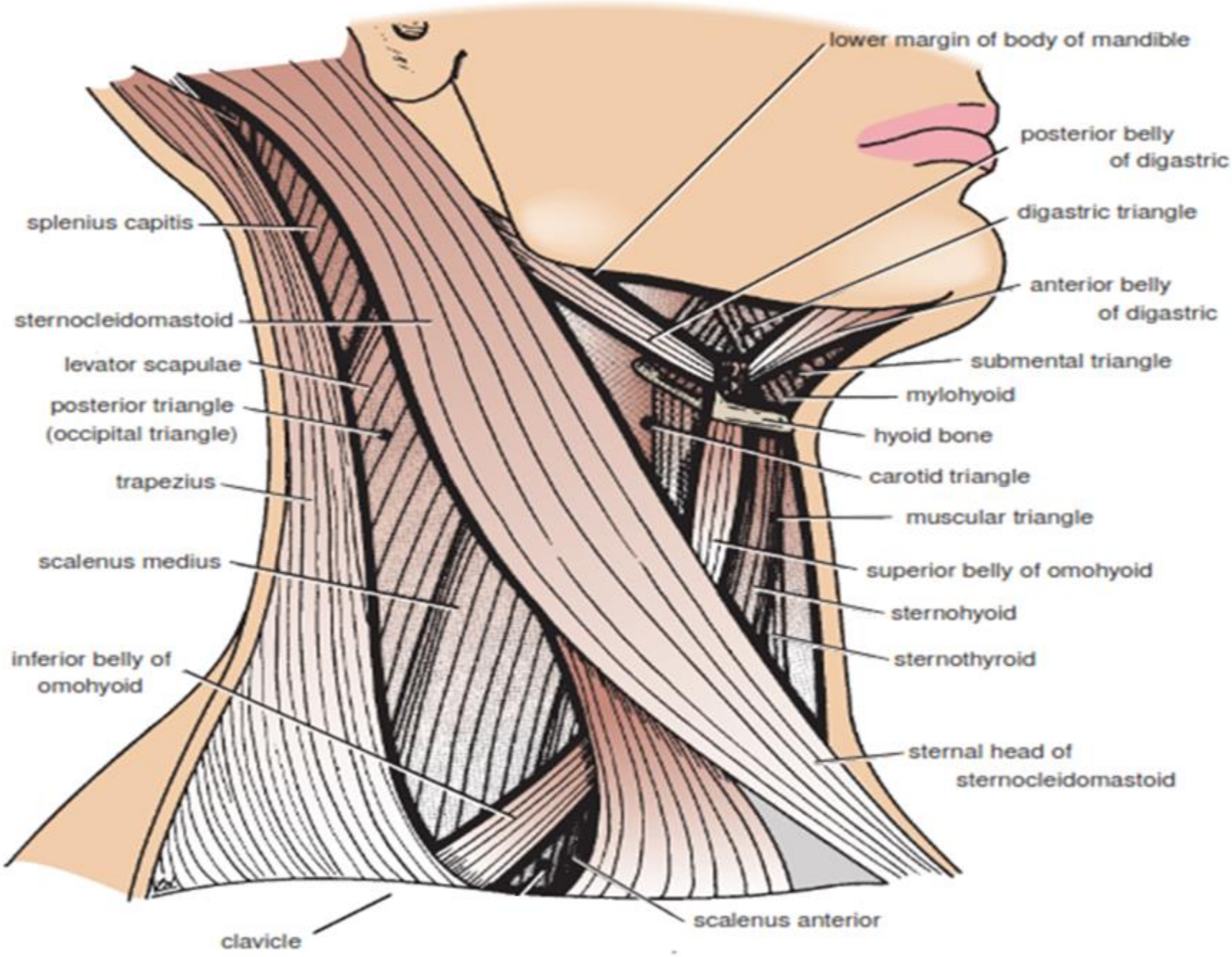
lower margin of body of mandible
posterior belly of digastric
digastric triangle
anterior belly of digastric
submental triangle
mylohyoid
hyoid bone
carotid triangle
muscular triangle
superior belly of omohyoid
sternohyoid
sternothyroid
sternal head of sternocleidomastoid
splenius capitis
sternocleidomastoid
levator scapulae
posterior triangle (occipital triangle)
trapezius
scalenus medius
inferior belly of omohyoid
scalenus anterior
clavicle

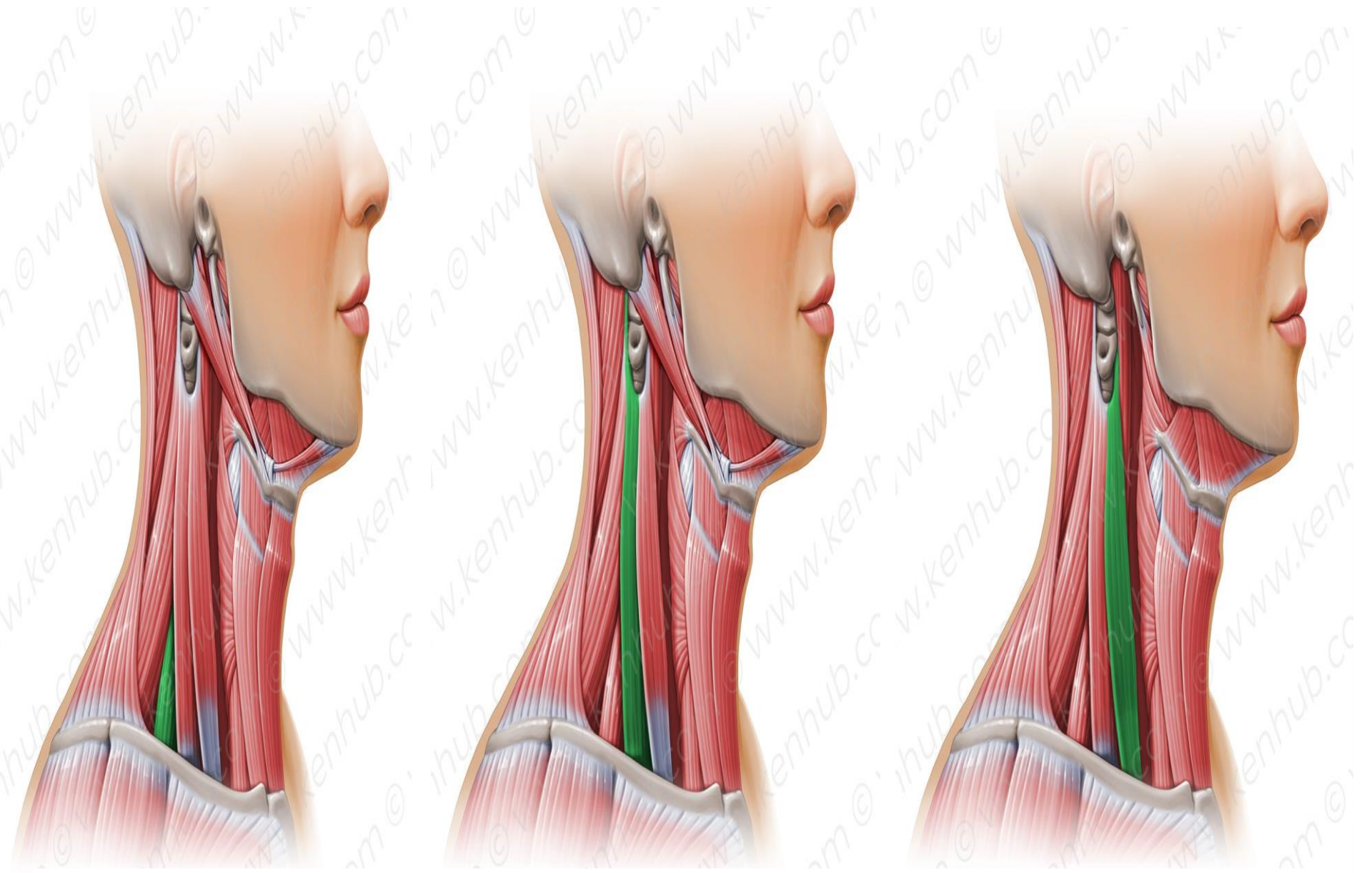

Scalenus posterior

Scalenus medius

Scalenus anterior

Contents of the posterior triangle

Nerves:

- - trunks of brachial plexus (C5, C6, C7, C8 & T1)
- Cutaneous branches of cervical plexus (C1,C2,C3 & C4). (lesser occipital, great auricular, transverse cervical & supraclavicular nerves).
- - Accessory nerve

Arteries:

- - Subclavian artery.
- - Suprascapular artery.
- - Transverse cervical artery.
- - Occipital artery.

Veins:

- - Subclavian vein.
- - External jugular vein.

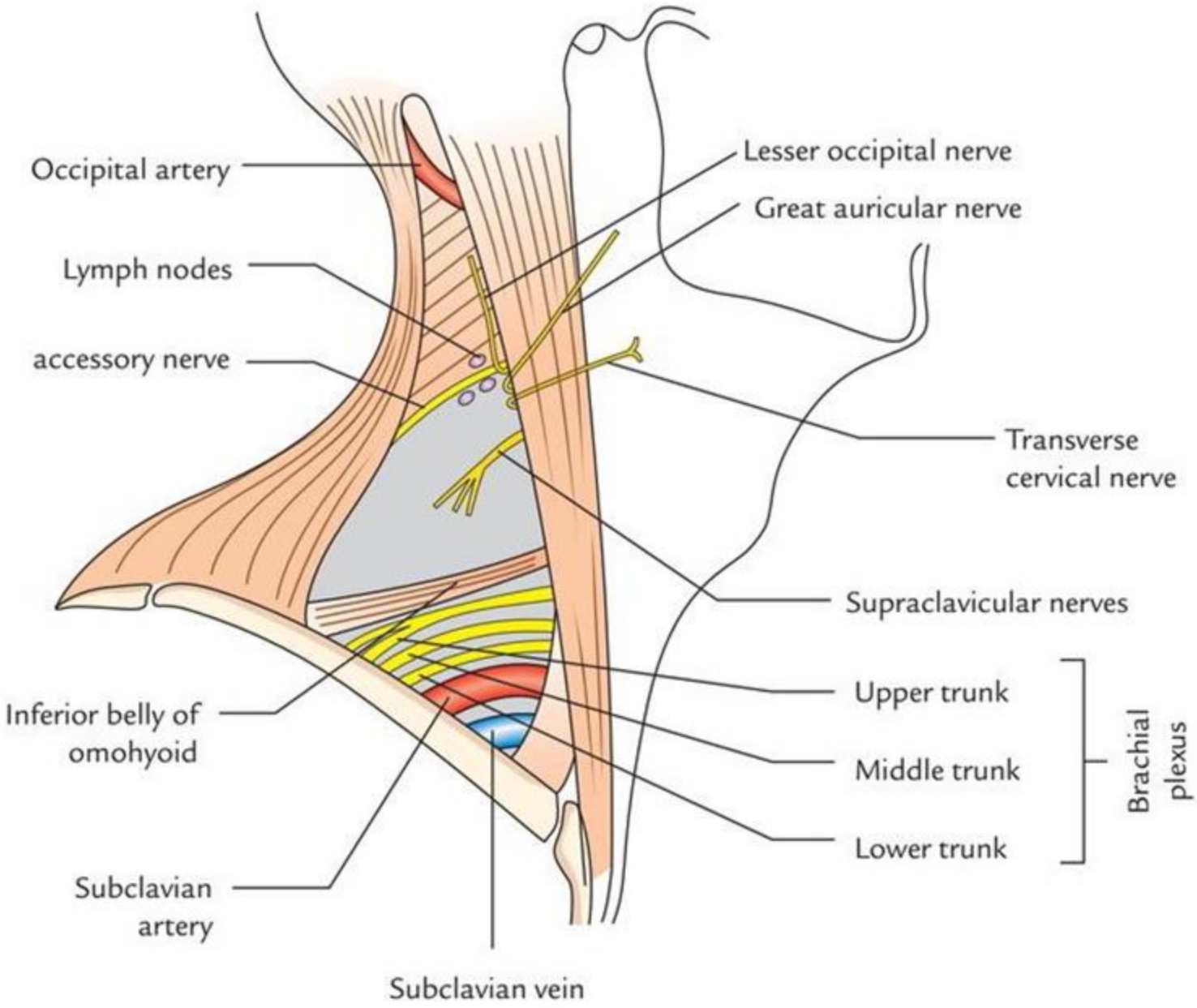
Occipital artery
Lymph nodes
accessory nerve
Inferior belly of omohyoid
Subclavian artery
Subclavian vein
Lesser occipital nerve
Great auricular nerve
Transverse cervical nerve
Supraclavicular nerves
Upper trunk
Middle trunk
Lower trunk
Brachial plexus

Omohyoid				
Inferior belly	Upper margin of scapula and suprascapular ligament	Intermediate tendon is held to clavicle and first rib by fascial sling	Ansa cervicalis; C1, 2, and 3	Depresses hyoid bone
Superior belly	Lower border of body of hyoid bone			
Scalenus anterior	Transverse processes of 3rd, 4th, 5th, and 6th cervical vertebrae	1st rib	C4, 5, and 6	Elevates 1st rib; laterally flexes and rotates cervical part of vertebral column
Scalenus medius	Transverse processes of upper six cervical vertebrae	1st rib	Anterior rami of cervical nerves	Elevates 1st rib; laterally flexes and rotates cervical part of vertebral column
Scalenus posterior	Transverse processes of lower cervical vertebrae	2nd rib	Anterior rami of cervical nerves	Elevates 2nd rib; laterally flexes and rotates cervical part of vertebral column

Sternohyoid	Manubrium sterni and clavicle	Body of hyoid bone	Ansa cervicalis; C1, 2, and 3	Depresses hyoid bone
Sternothyroid	Manubrium sterni	Oblique line on lamina of thyroid cartilage	Ansa cervicalis; C1, 2, and 3	Depresses larynx
Thyrohyoid	Oblique line on lamina of thyroid cartilage	Lower border of body of hyoid bone	Ansa cervicalis; C1, 2, and 3	Depresses hyoid bone or elevates larynx

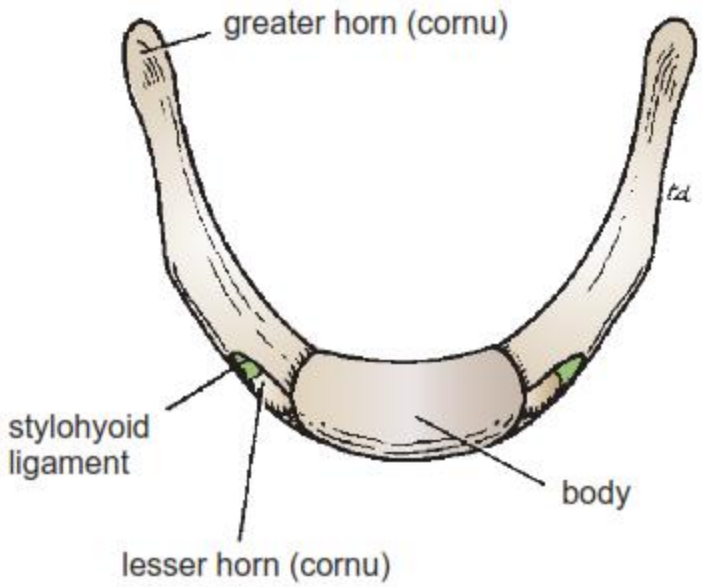

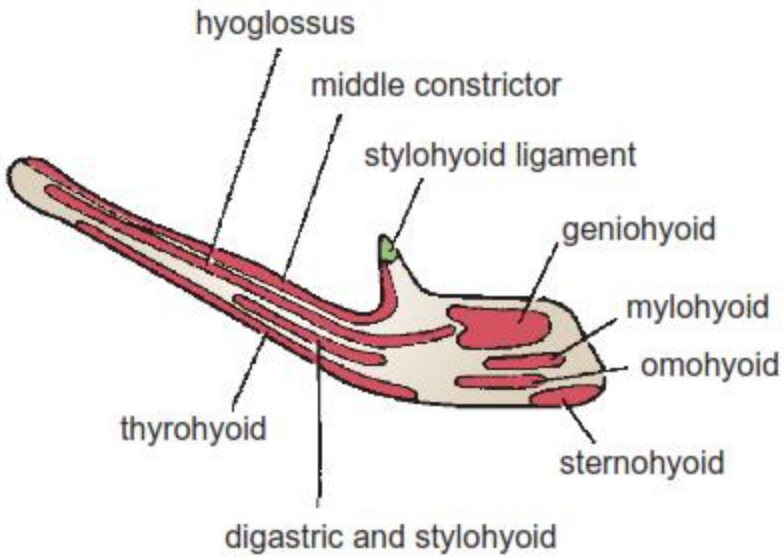

Hyoid bone

THANK YOU

ORAL CAVITY - PART 1

PREPARED BY:

Dr. REYADH AL-RASHIDI

The Mouth Cavity

The mouth extends from the lips to the pharynx. The entrance into the pharynx, the **oropharyngeal isthmus,** is formed on each side by the palatoglossal fold

The mouth is divided into the vestibule and the mouth cavity proper.

Vestibule

The vestibule lies between the lips and the cheeks externally and the gums and the teeth internally. This slitlike space communicates with the exterior through the oral fissure between the lips. When the jaws are closed, it communicates with the mouth proper behind the third molar tooth on each side. The vestibule is limited above and below by the reflection of the mucous membrane from the lips and cheeks to the gums.

The lateral wall of the vestibule is formed by the cheek, which is made up by the buccinator muscle and is lined with mucous membrane. The tone of the buccinator muscle and that of the muscles of the lips keeps the walls of the vestibule in contact with one another. The **duct of the parotid salivary gland** opens on a small papilla into the vestibule opposite the upper second molar tooth

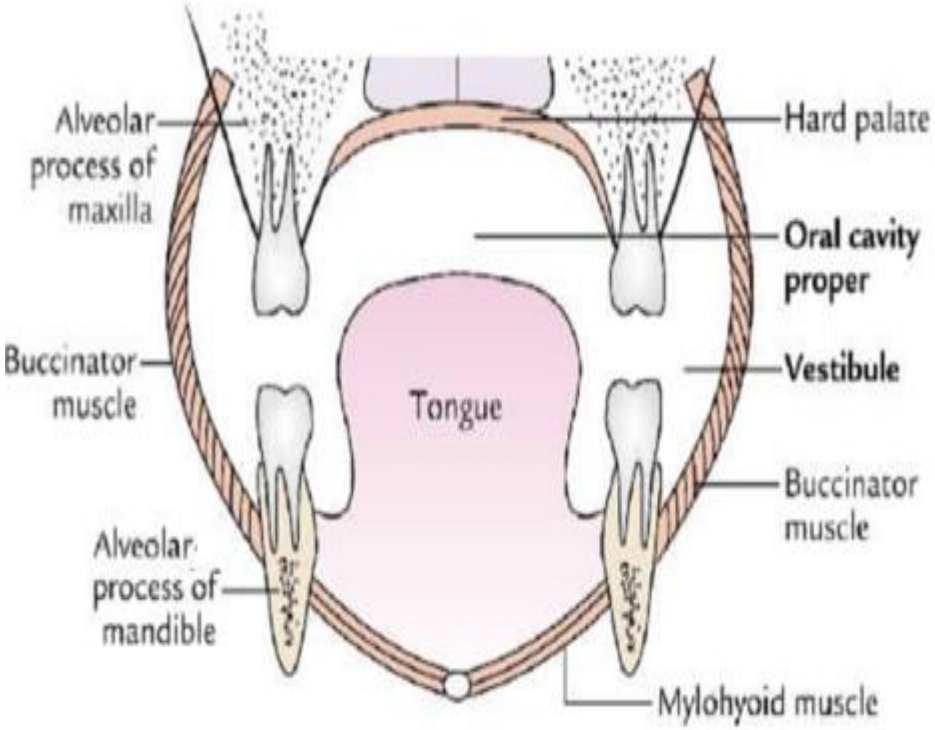
Alveolar process of maxilla
Hard palate
Oral cavity proper
Buccinator muscle
Vestibule
Tongue
Buccinator muscle
Alveolar process of mandible
Mylohyoid muscle

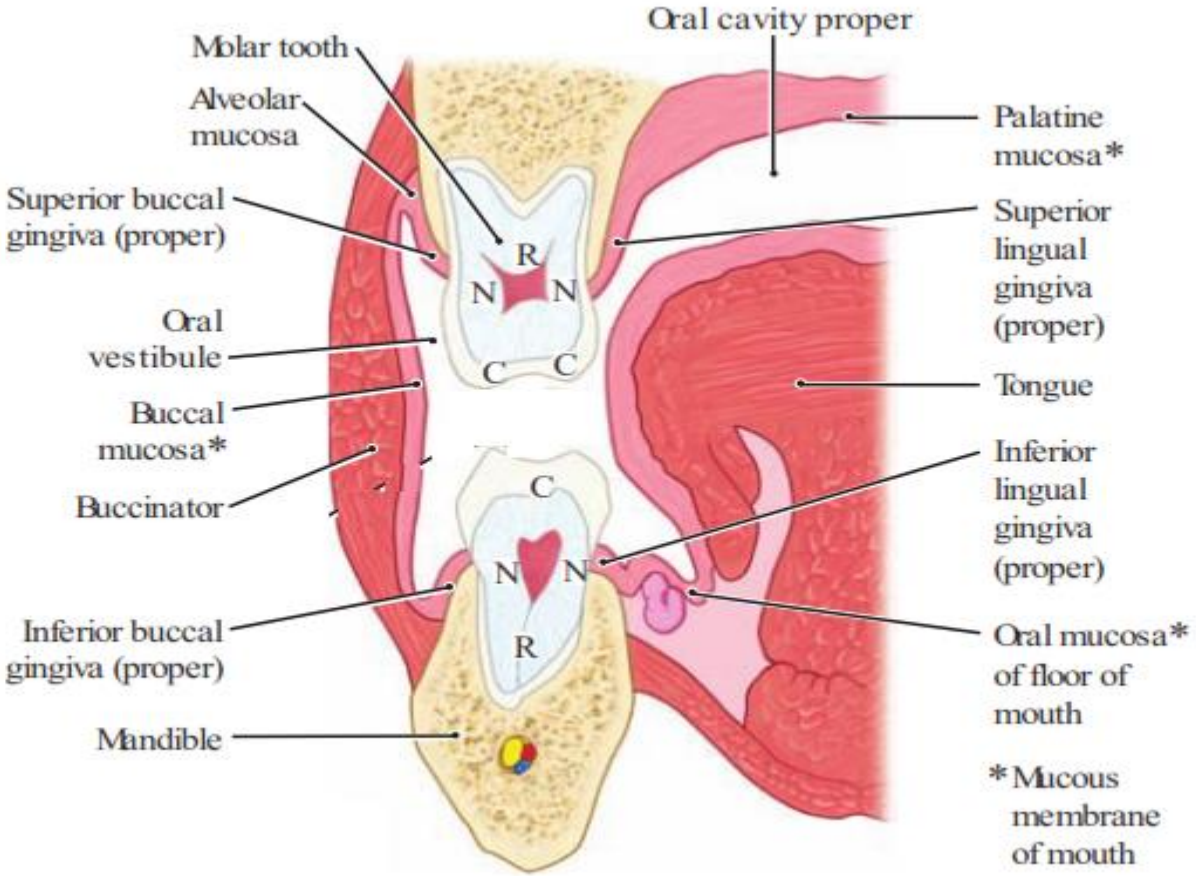
Oral cavity proper
Molar tooth
Alveolar mucosa
Palatine mucosa*
Superior buccal gingiva (proper)
Superior lingual gingiva (proper)
R
N
N
Oral vestibule
C
C
Tongue
Buccal mucosa*
Buccinator
C
Inferior lingual gingiva (proper)
N
N
Inferior buccal gingiva (proper)
R
Oral mucosa* of floor of mouth
Mandible
* Mucous membrane of mouth

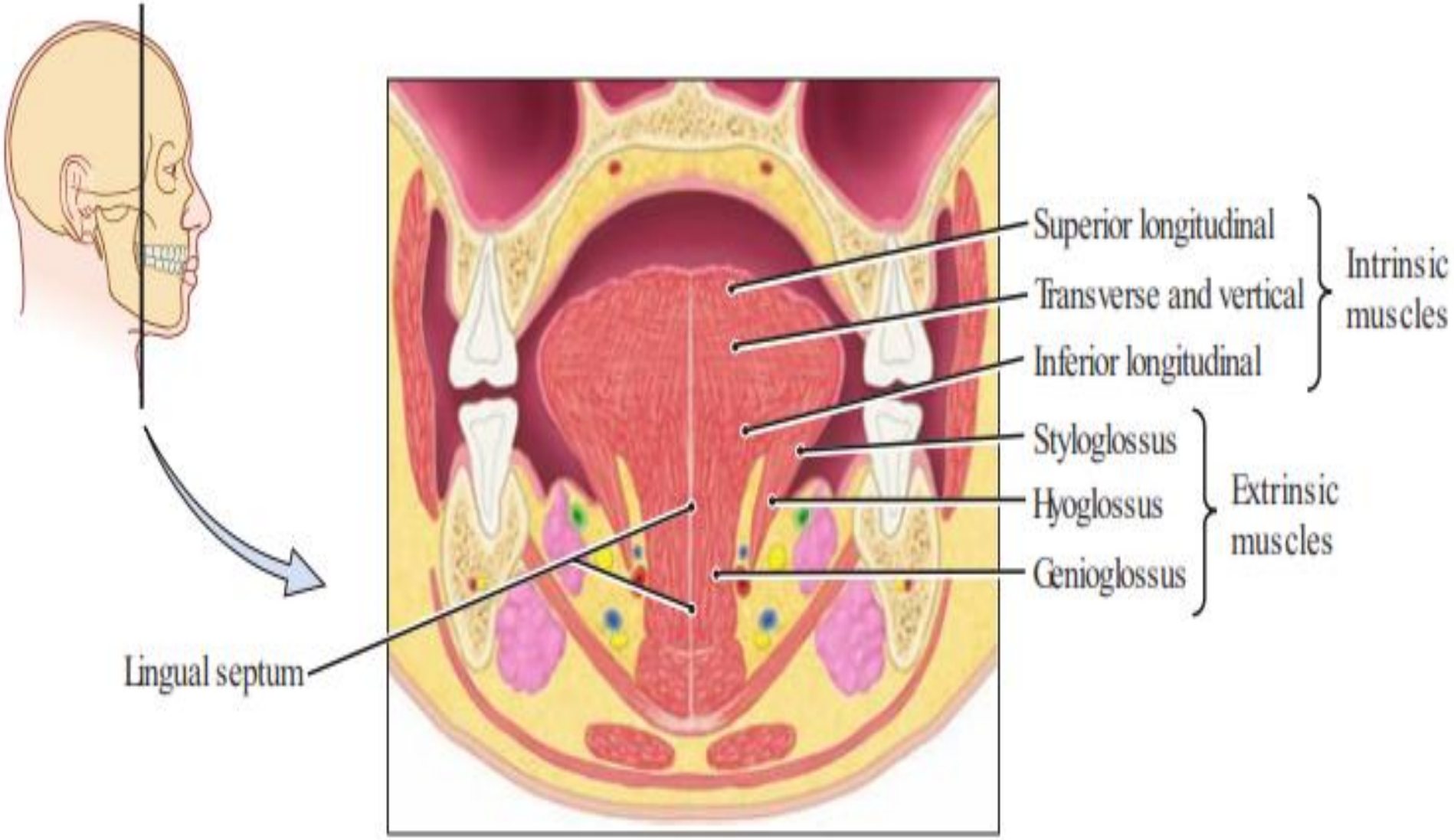

C. Anterior View of Coronal Section of Mouth

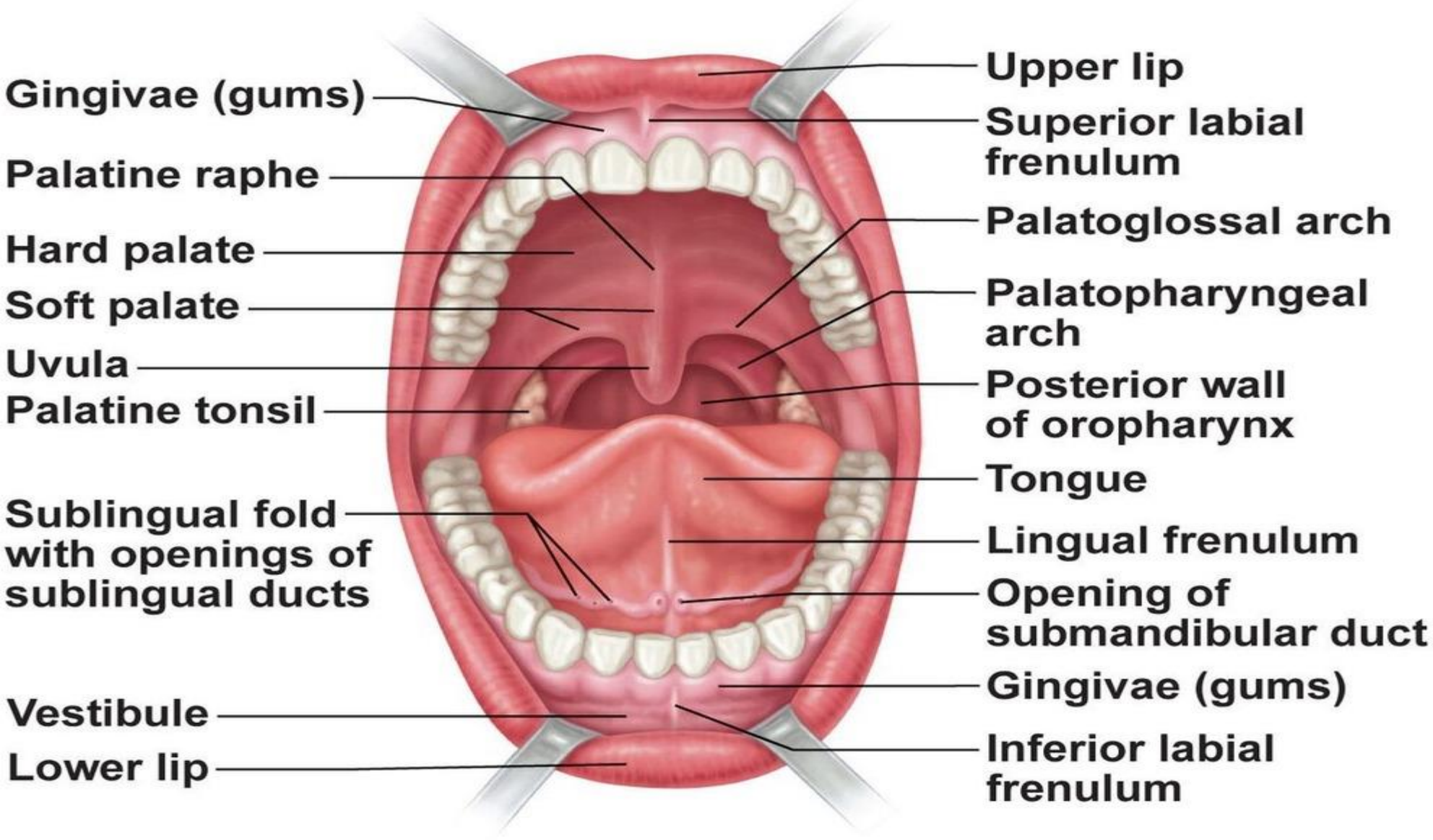
Gingivae (gums)
Palatine raphe
Hard palate
Soft palate
Uvula
Palatine tonsil
Sublingual fold with openings of sublingual ducts
Vestibule
Lower lip
Upper lip
Superior labial frenulum
Palatoglossal arch
Palatopharyngeal arch
Posterior wall of oropharynx
Tongue
Lingual frenulum
Opening of submandibular duct
Gingivae (gums)
Inferior labial frenulum

Mouth Proper

The mouth proper has a roof and a floor.

Roof of Mouth

The roof of the mouth is formed by the hard palate in front and the soft palate behind

Floor of Mouth

The floor is formed largely by the anterior two thirds of the tongue and by the reflection of the mucous membrane from the sides of the tongue to the gum of the mandible. A fold of mucous membrane called the **frenulum of the tongue** connects the undersurface of the tongue in the midline to the floor of the mouth (Fig. 11.72). Lateral to the frenulum, the mucous membrane forms a fringed fold, the **plica fimbriata**

The submandibular duct of the submandibular gland opens onto the floor of the mouth on the summit of a small papilla on either side of the frenulum of the tongue (Fig. 11.72). The sublingual gland projects up into the mouth, producing a low fold of mucous membrane, the **sublingual fold.** Numerous ducts of the gland open on the summit of the fold.

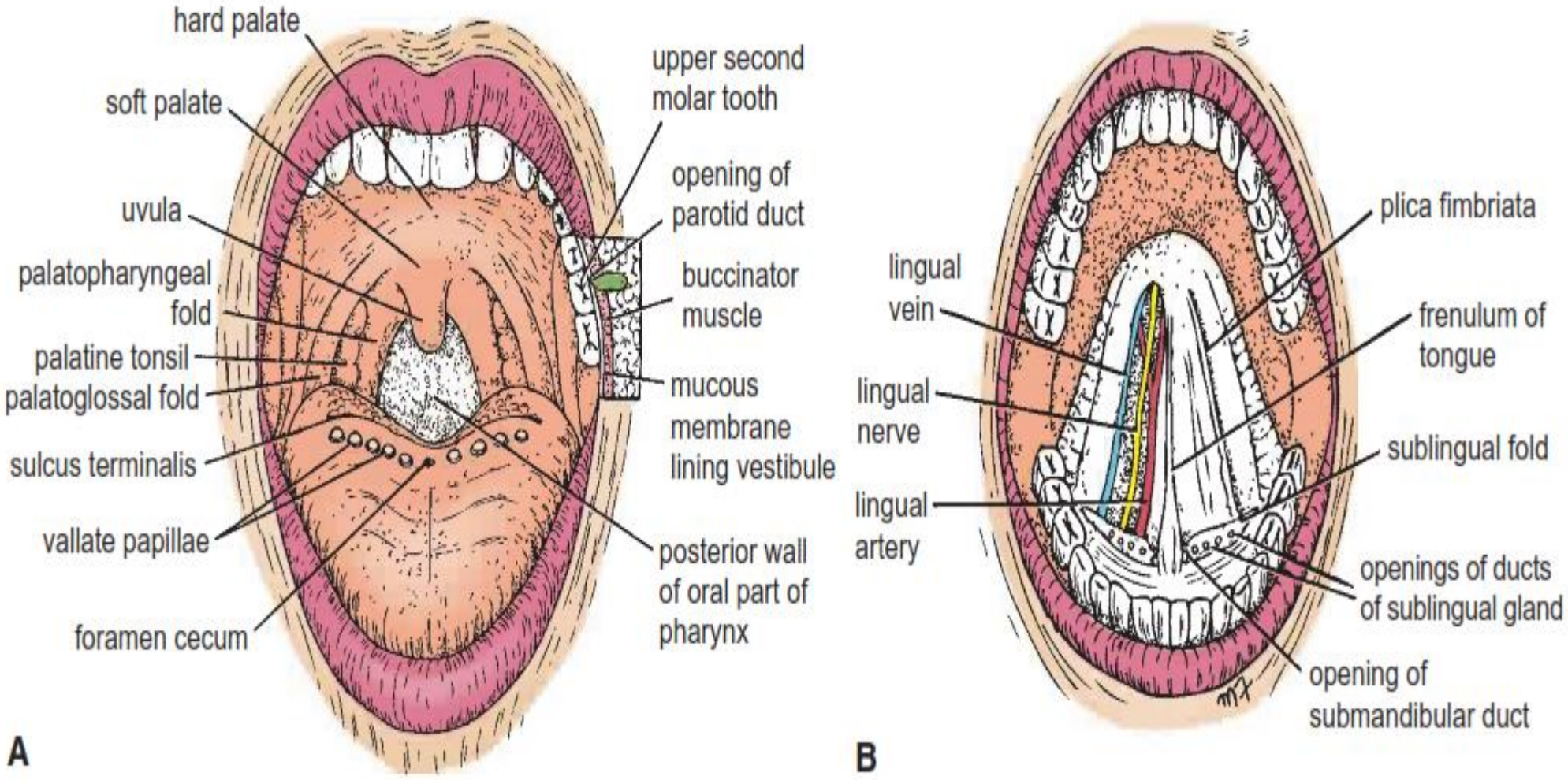

FIGURE 11.72 **A.** Cavity of the mouth. Cheek on the left side of the face has been cut away to show the buccinator muscle and the parotid duct. **B.** Undersurface of the tongue.

The Tongue

The tongue is a mass of striated muscle covered with mucous membrane (Fig. 11.77). The muscles attach the tongue to the styloid process and the soft palate above and to the mandible and the hyoid bone below. The tongue is divided into right and left halves by a median **fibrous septum.**

Mucous Membrane of the Tongue

The mucous membrane of the upper surface of the tongue can be divided into anterior and posterior parts by a V-shaped sulcus, the **sulcus terminalis** (Fig. 11.77). The apex of the sulcus projects backward and is marked by a small pit, the foramen cecum. The sulcus serves to divide the tongue into the anterior two thirds, or oral part, and the posterior third, or pharyngeal part. The foramen cecum is an embryologic remnant and marks the site of the upper end of the thyroglossal duct

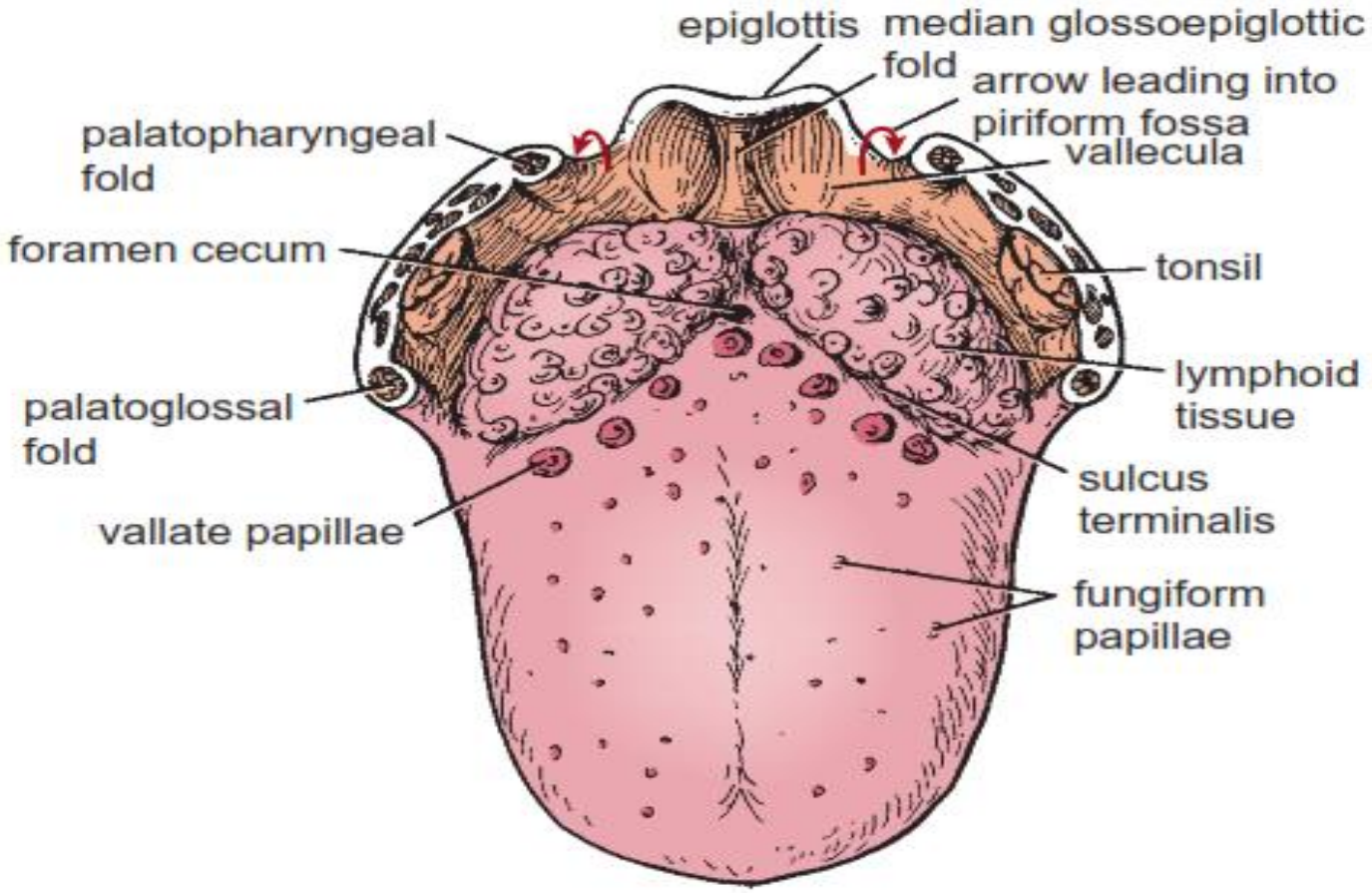

FIGURE 11.77 Dorsal surface of the tongue showing the valleculae, the epiglottis, and the entrance into the piriform fossa on each side

Three types of papillae are present on the upper surface of the anterior two thirds of the tongue: the **filiform papillae,** the **fungiform papillae,** and the **vallate papillae.**

The mucous membrane covering the posterior third of the tongue is devoid of papillae but has an irregular surface (Fig. 11.77), caused by the presence of underlying lymph nodules, the **lingual tonsil.**

The mucous membrane on the inferior surface of the tongue is reflected from the tongue to the floor of the mouth. In the midline anteriorly, the undersurface of the tongue is connected to the floor of the mouth by a fold of mucous membrane, the **frenulum of the tongue.**

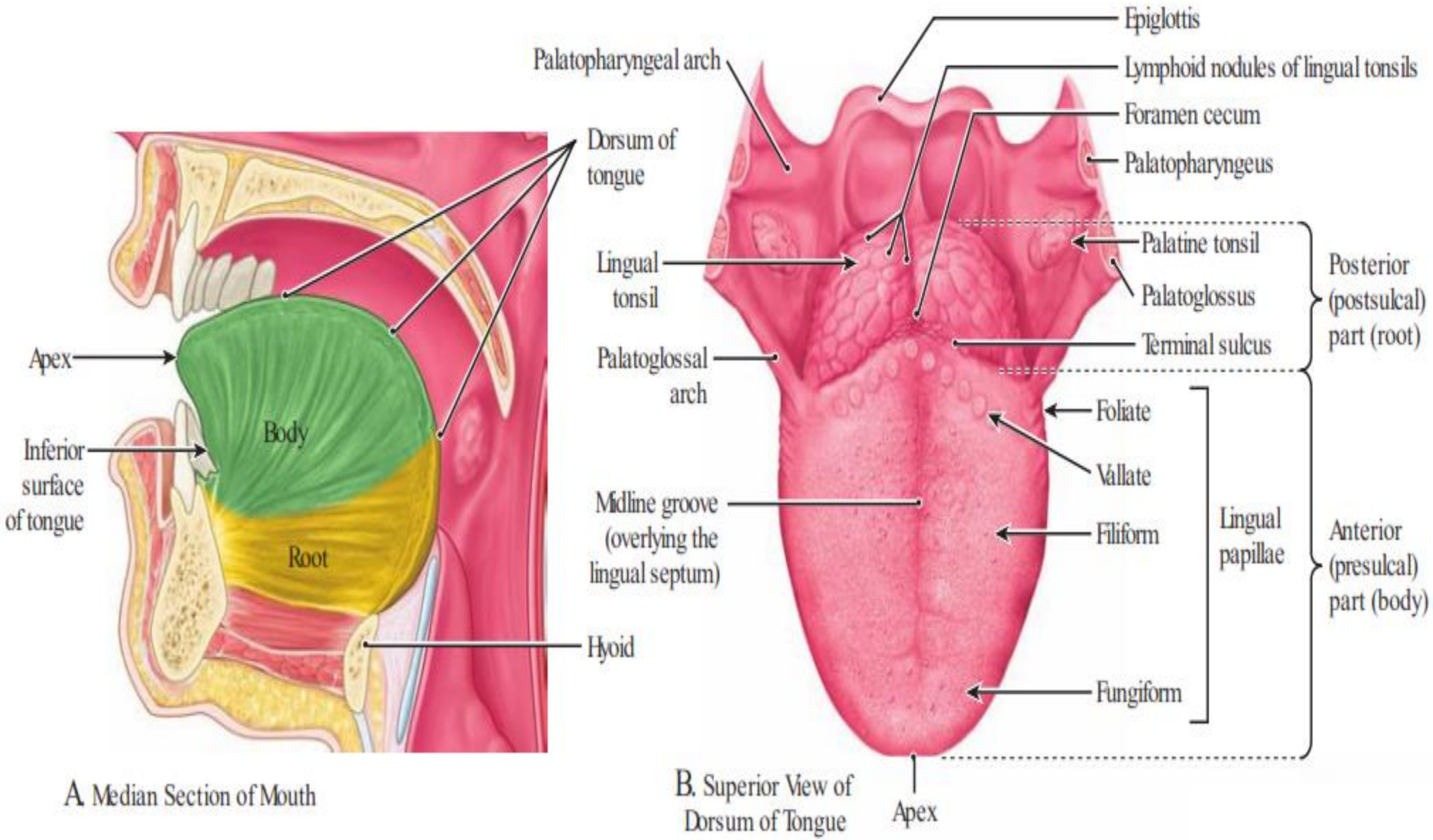
Dorsum of tongue
Apex
Body
Inferior surface of tongue
Root
Hyoid
A. Median Section of Mouth
Palatopharyngeal arch
Epiglottis
Lymphoid nodules of lingual tonsils
Foramen cecum
Palatopharyngeus
Lingual tonsil
Palatine tonsil
Palatoglossus
Terminal sulcus
Palatoglossal arch
Foliate
Vallate
Midline groove (overlying the lingual septum)
Filiform
Fungiform
Lingual papillae
Posterior (postsulcal) part (root)
Anterior (presulcal) part (body)
B. Superior View of Dorsum of Tongue
Apex

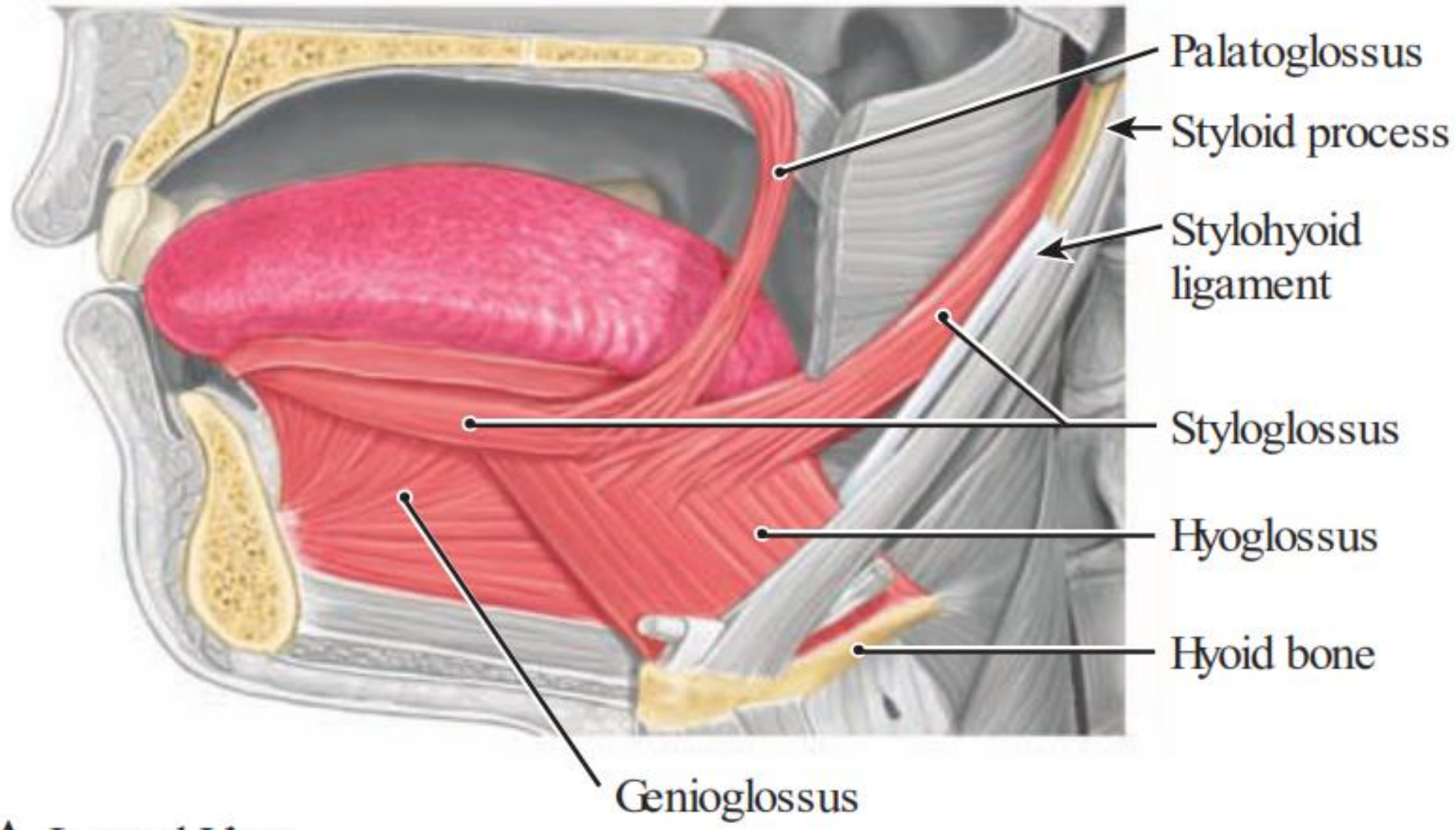

A. Lateral View

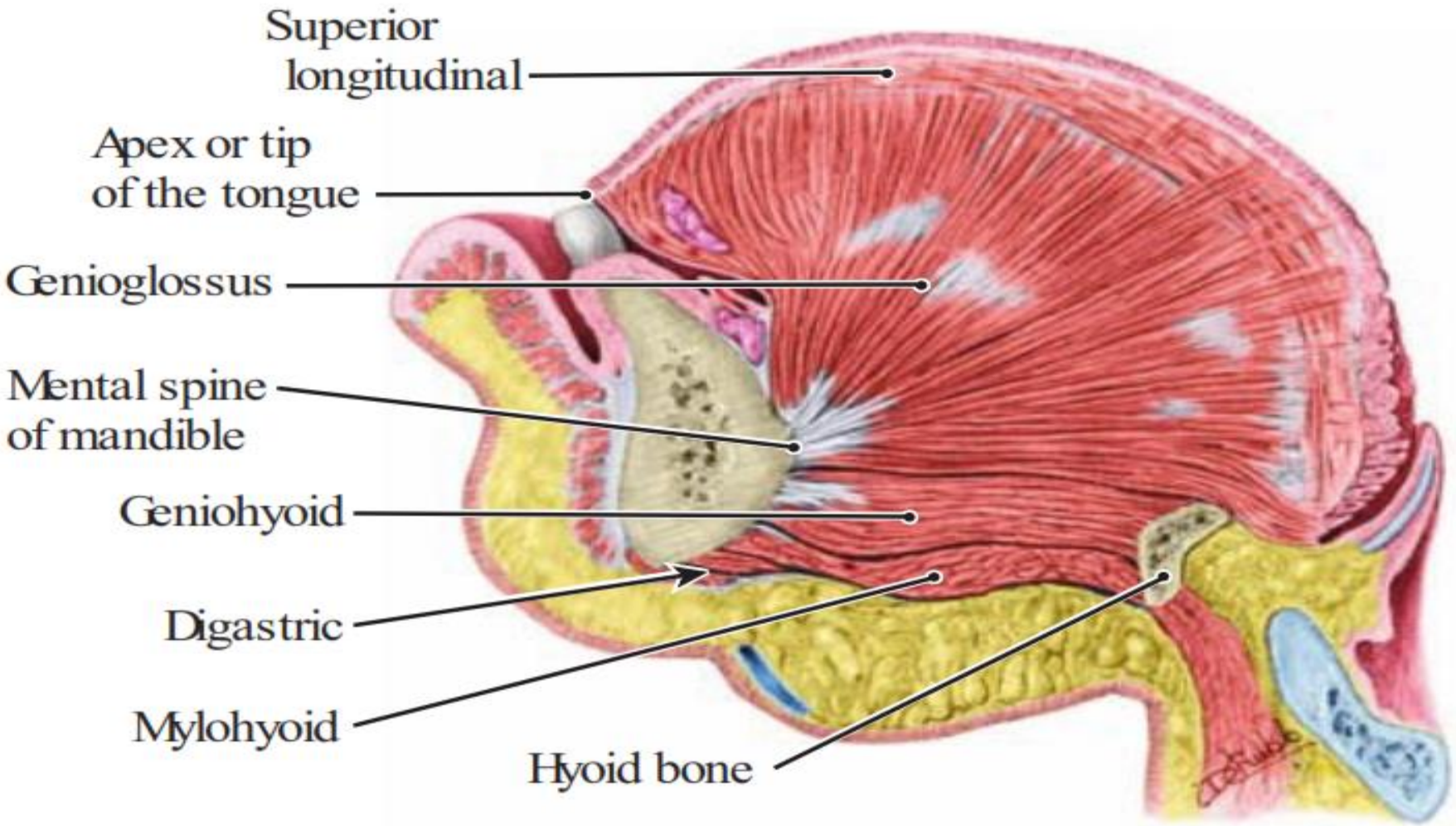

B. Medial View of Right Half of Bisected Tongue

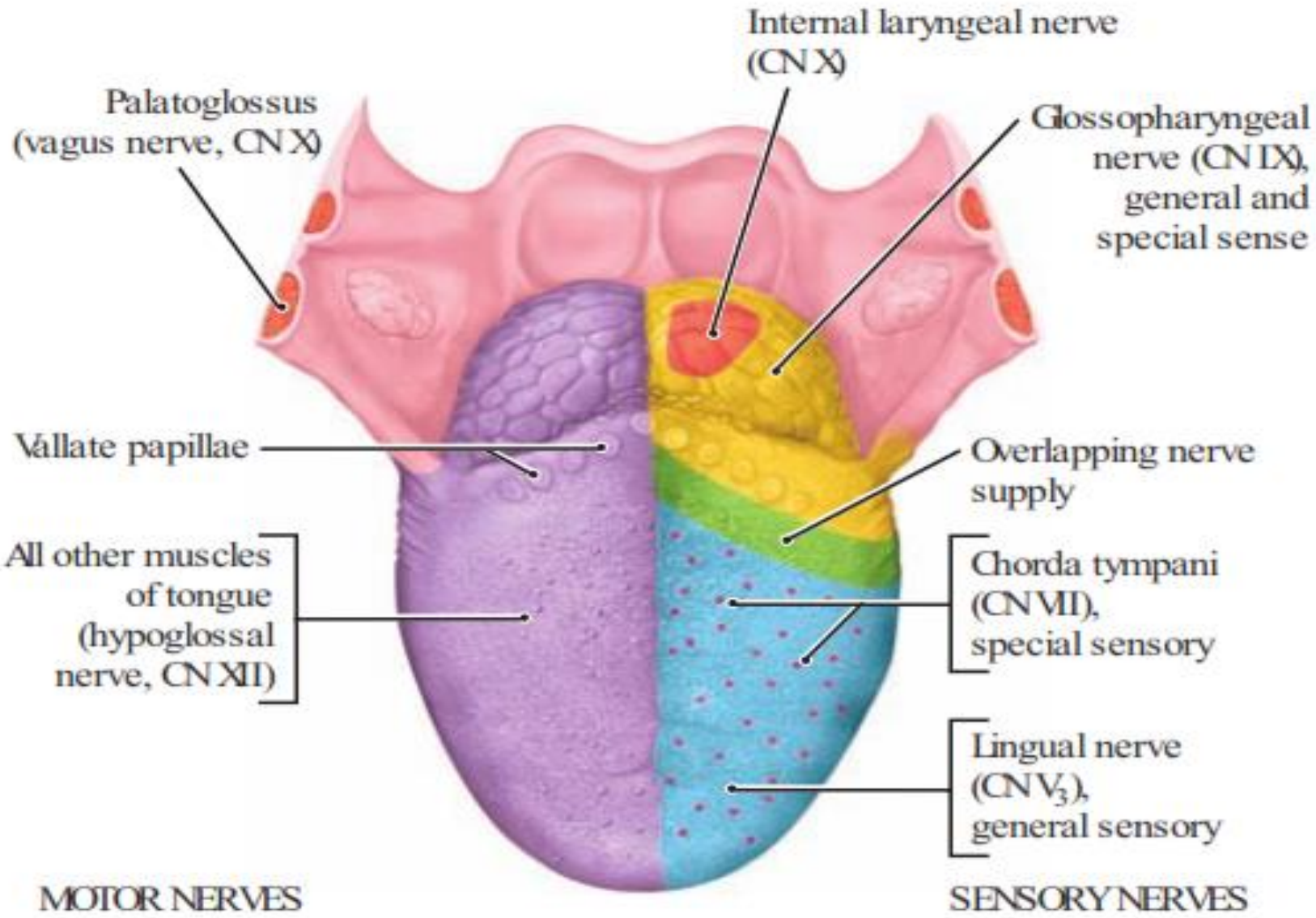

A. Anterior View

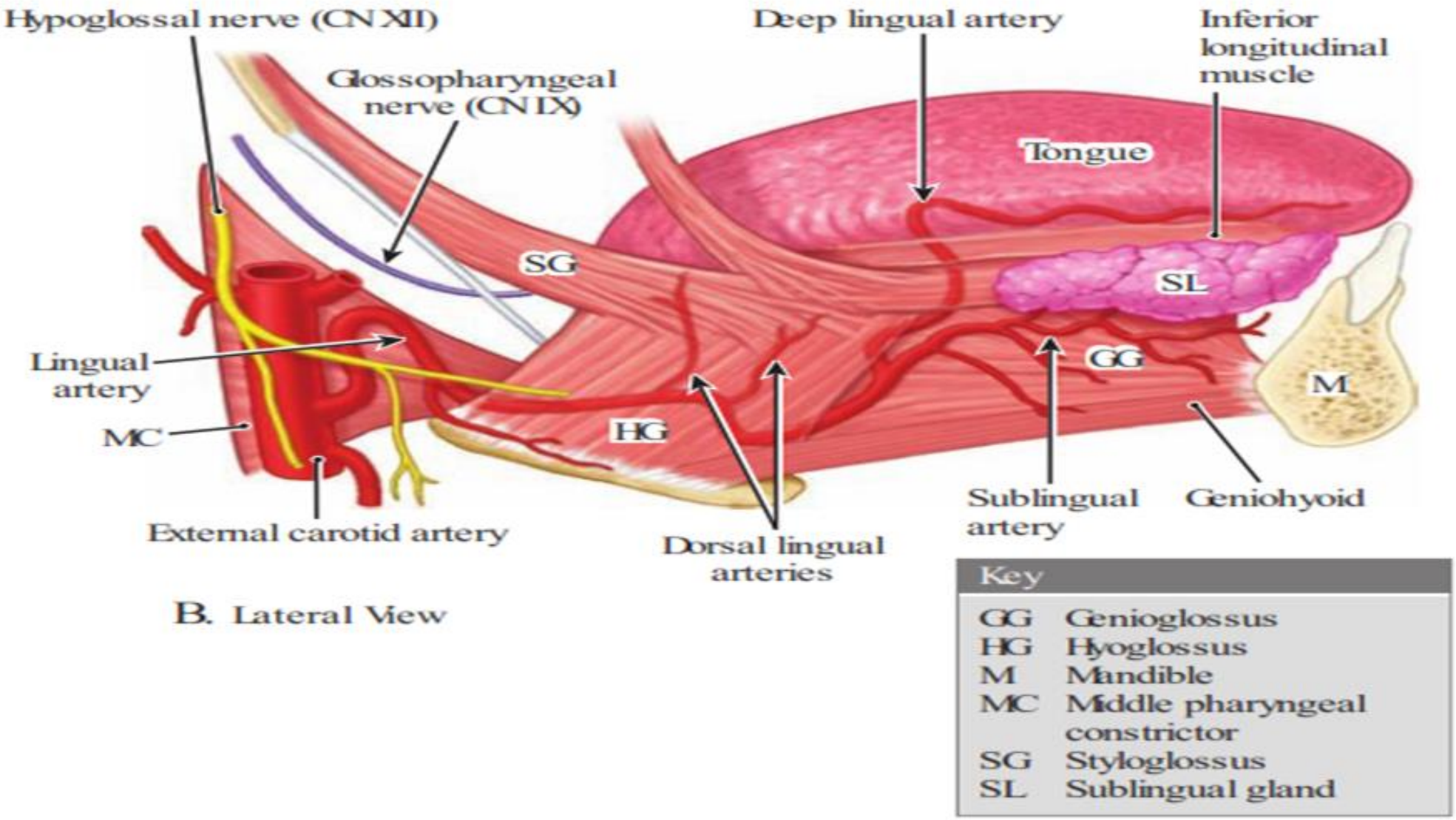

B. Lateral View

TABLE 11.8 Muscles of Tongue

Muscle	Origin	Insertion	Nerve Supply	Action
Intrinsic Muscles				
Longitudinal	Median septum and submucosa	Mucous membrane	Hypoglossal nerve	Alters shape of tongue
Transverse				
Vertical				
Extrinsic Muscles				
Genioglossus	Superior genial spine of mandible	Blends with other muscles of tongue	Hypoglossal nerve	Protrudes apex of tongue through mouth
Hyoglossus	Body and greater cornu of hyoid bone	Blends with other muscles of tongue	Hypoglossal nerve	Depresses tongue
Styloglossus	Styloid process of temporal bone	Blends with other muscles of tongue	Hypoglossal nerve	Draws tongue upward and backward
Palatoglossus	Palatine aponeurosis	Side of tongue	Pharyngeal plexus	Pulls roots of tongue upward and backward, narrows oropharyngeal isthmus

Movements of the Tongue

Protrusion: The genioglossus muscles on both sides acting together

Retraction: Styloglossus and hyoglossus muscles on both sides acting together

Depression: Hyoglossus muscles on both sides acting together

Retraction and elevation of the posterior third: Styloglossus and palatoglossus muscles on both sides acting together

Shape changes: Intrinsic muscles

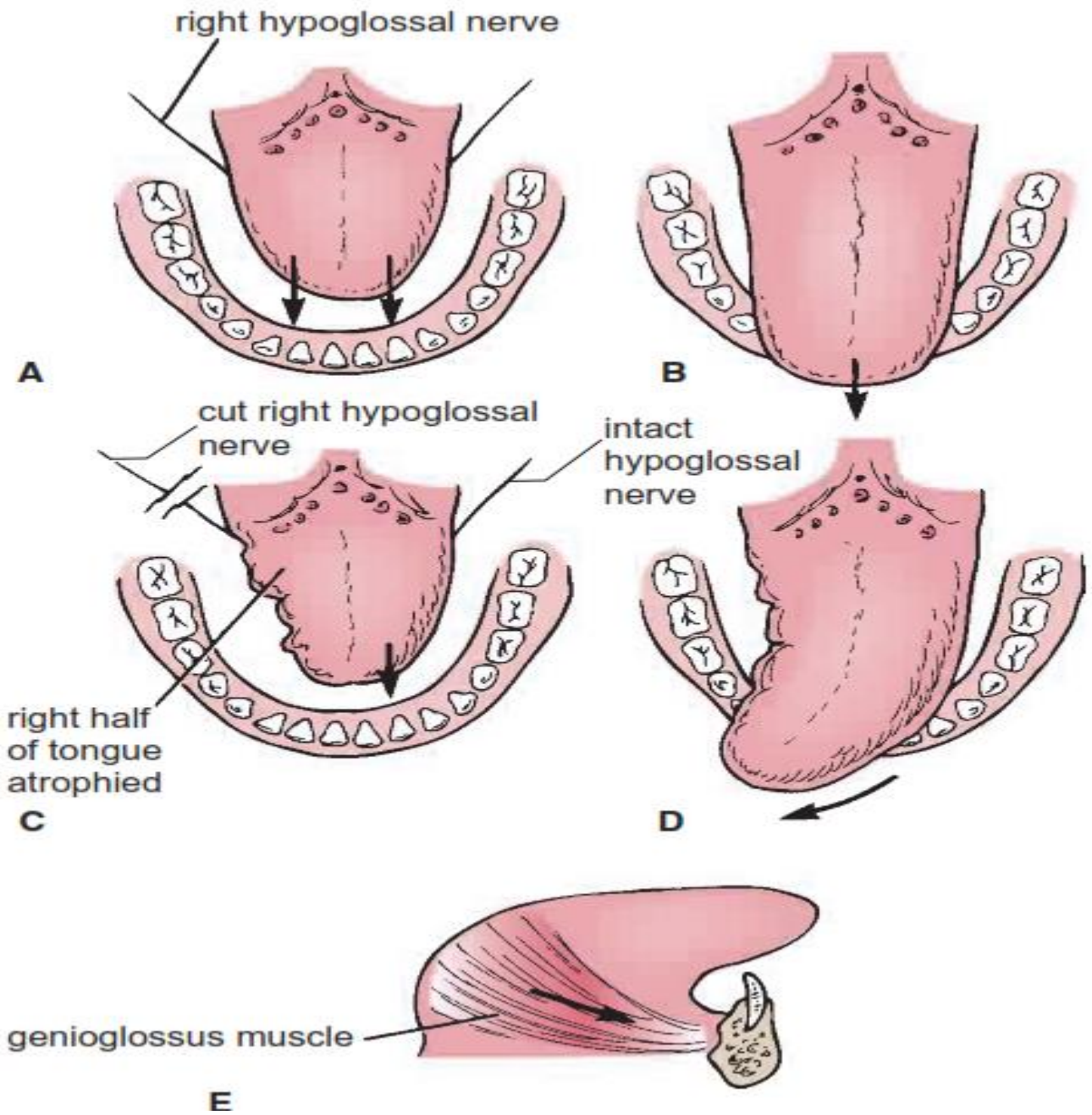

FIGURE 11.78 Diagrammatic representation of the action of the right and left genioglossus muscles of the tongue. **A.** The right and left muscles contract equally together and as a result **(B)** the tip of the tongue is protruded in the midline. **C.** The right hypoglossal nerve (which innervates the genioglossus muscle and the intrinsic tongue muscles on the same side) is cut and as a result the right side of the tongue is atrophied and wrinkled. **D.** When the patient is asked to protrude the tongue, the tip points to the side of the nerve lesion. **E.** The origin and insertion and direction of pull of the genioglossus muscle.

CLINICAL NOTES

Laceration of the Tongue

A wound of the tongue is often caused by the patient's teeth following a blow on the chin when the tongue is partly protruded from the mouth. It can also occur when a patient accidentally bites the tongue while eating, during recovery from an anesthetic, or during an epileptic attack. Bleeding is halted by grasping the tongue between the finger and thumb posterior to the laceration, thus occluding the branches of the lingual artery.

Maxilla

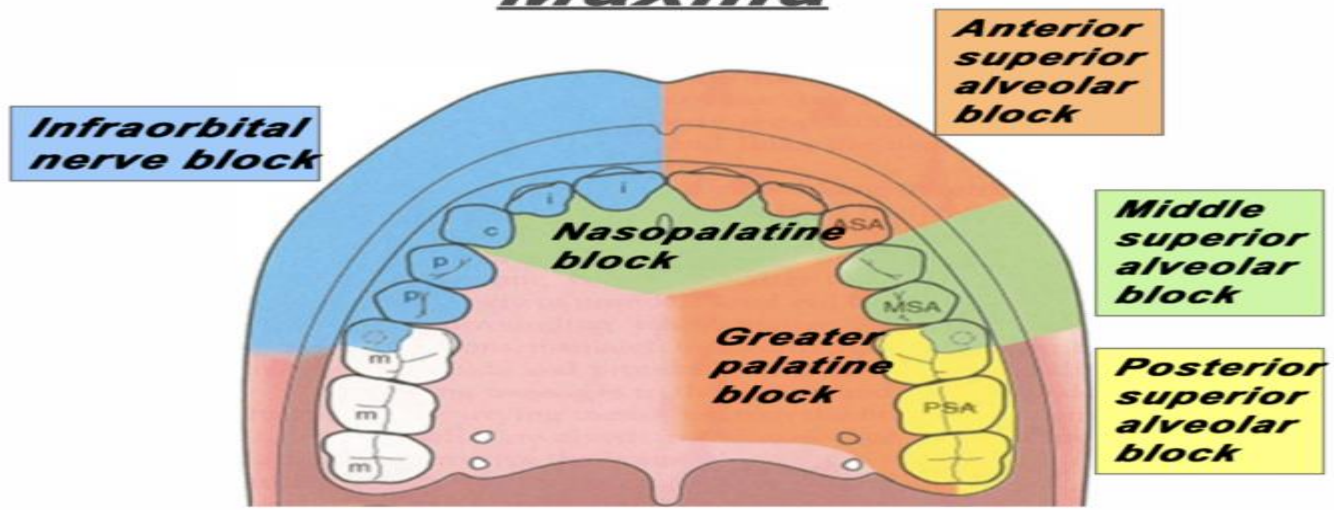

Mandible

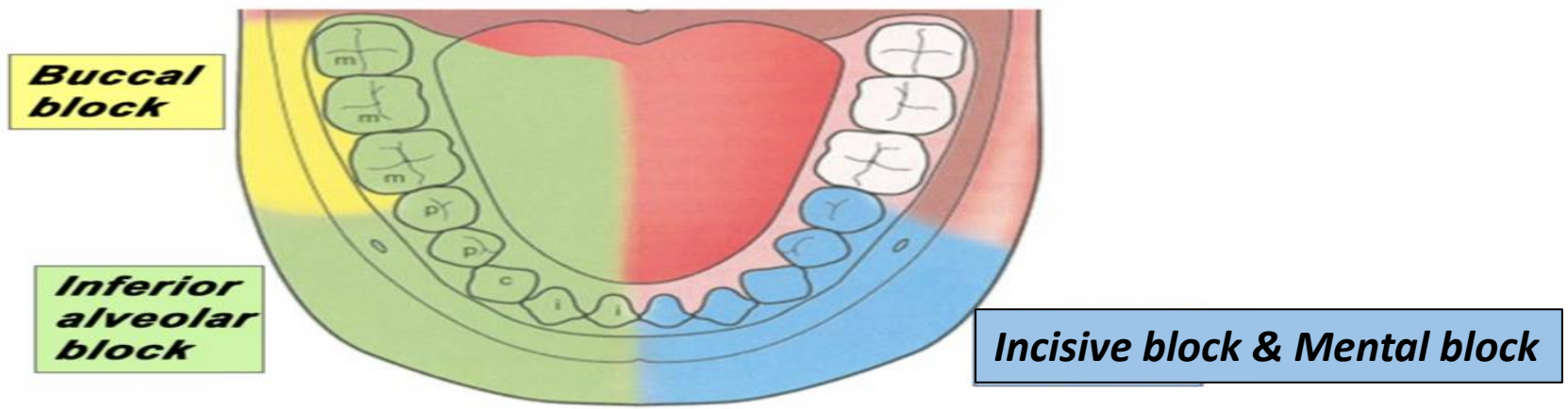

THANK YOU

ORAL CAVITY - PART 2

PREPARED BY:

Dr. REYADH AL-RASHIDI

The Palate

The palate forms the roof of the mouth and the floor of the nasal cavity. It is divided into two parts: the hard palate in front and the soft palate behind.

Hard Palate

The hard palate is formed by the palatine processes of the maxillae and the horizontal plates of the palatine bones (Fig. 11.80). It is continuous behind with the soft palate.

It contains several landmarks such as the incisive foramen and greater and lesser palatine foramina. They serve as passage way for the neurovascular structures intended for the supply of the oral cavity structures.

Key facts about hard palate

Borders	Anterior and lateral - maxillary teeth Posterior - soft palate
Structure	Palatine process of maxilla Paired palatine bones
Features	Incisive foramen (passage for nasopalatine nerve, sphenopalatine arteries and veins) Greater palatine foramina (passage for greater palatine nerve) Lesser palatine foramina (passage for lesser palatine nerve) Palatine raphe Transverse rugae
Clinical relation	Cleft palate

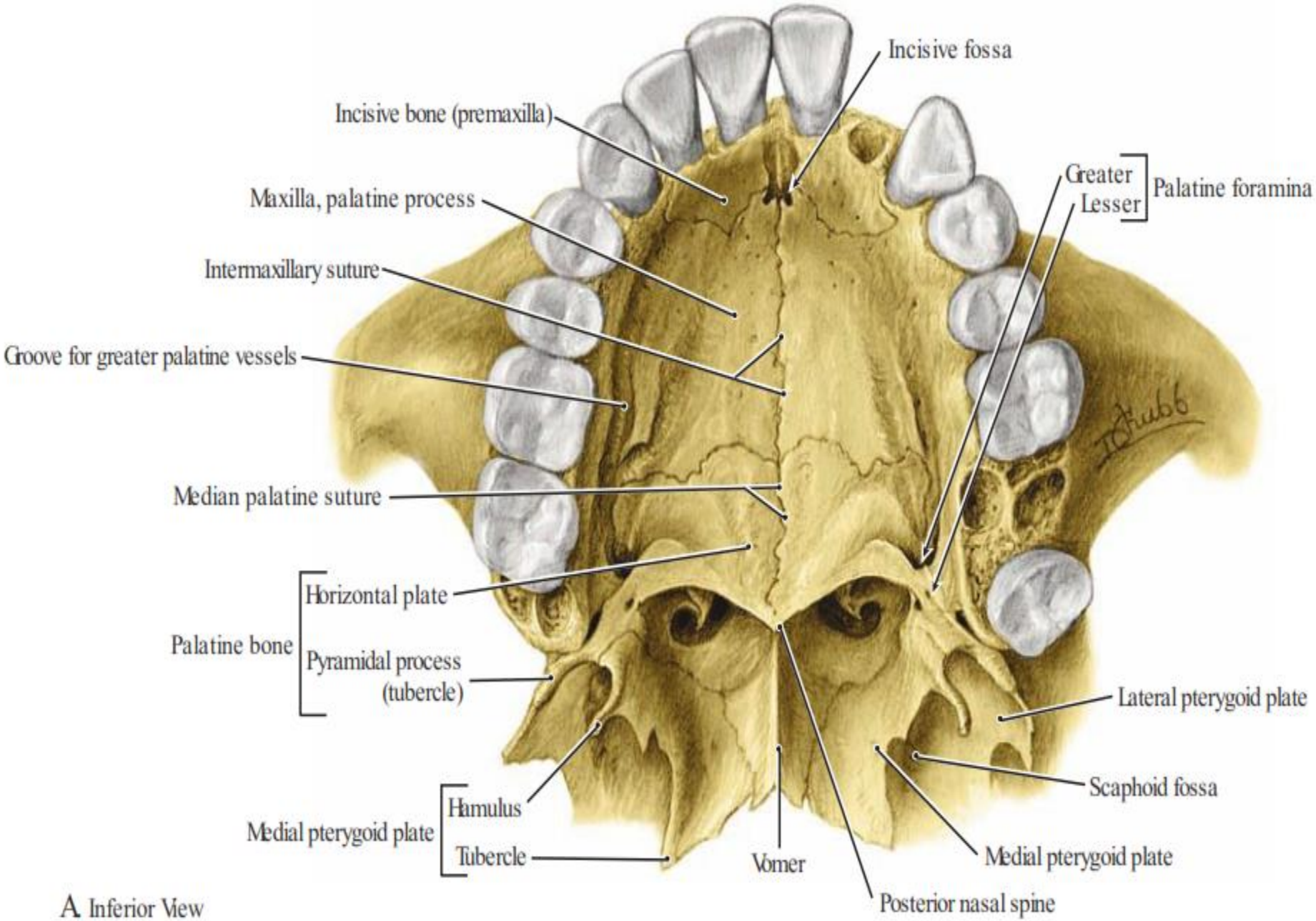

A. Inferior View

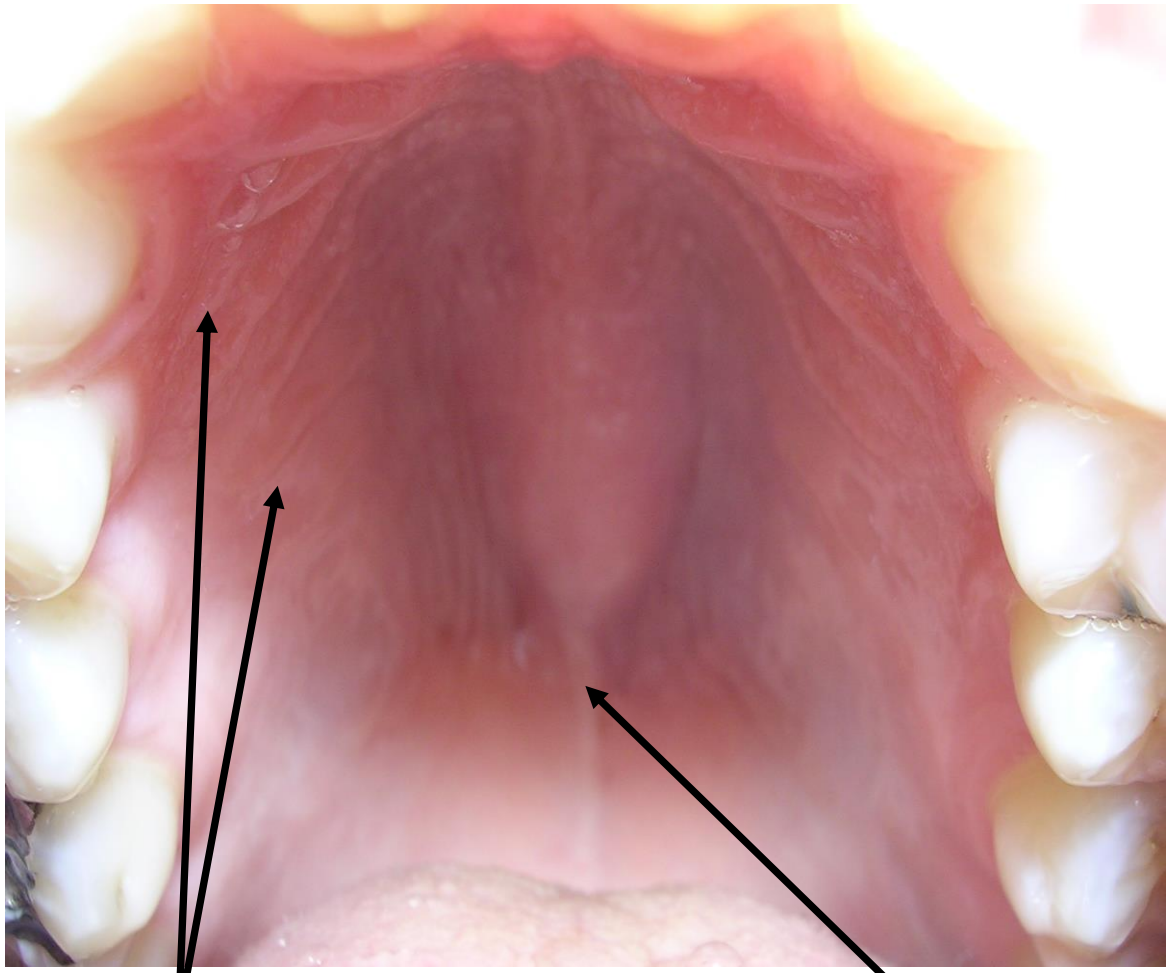

Transverse rugae

Palatine raphe

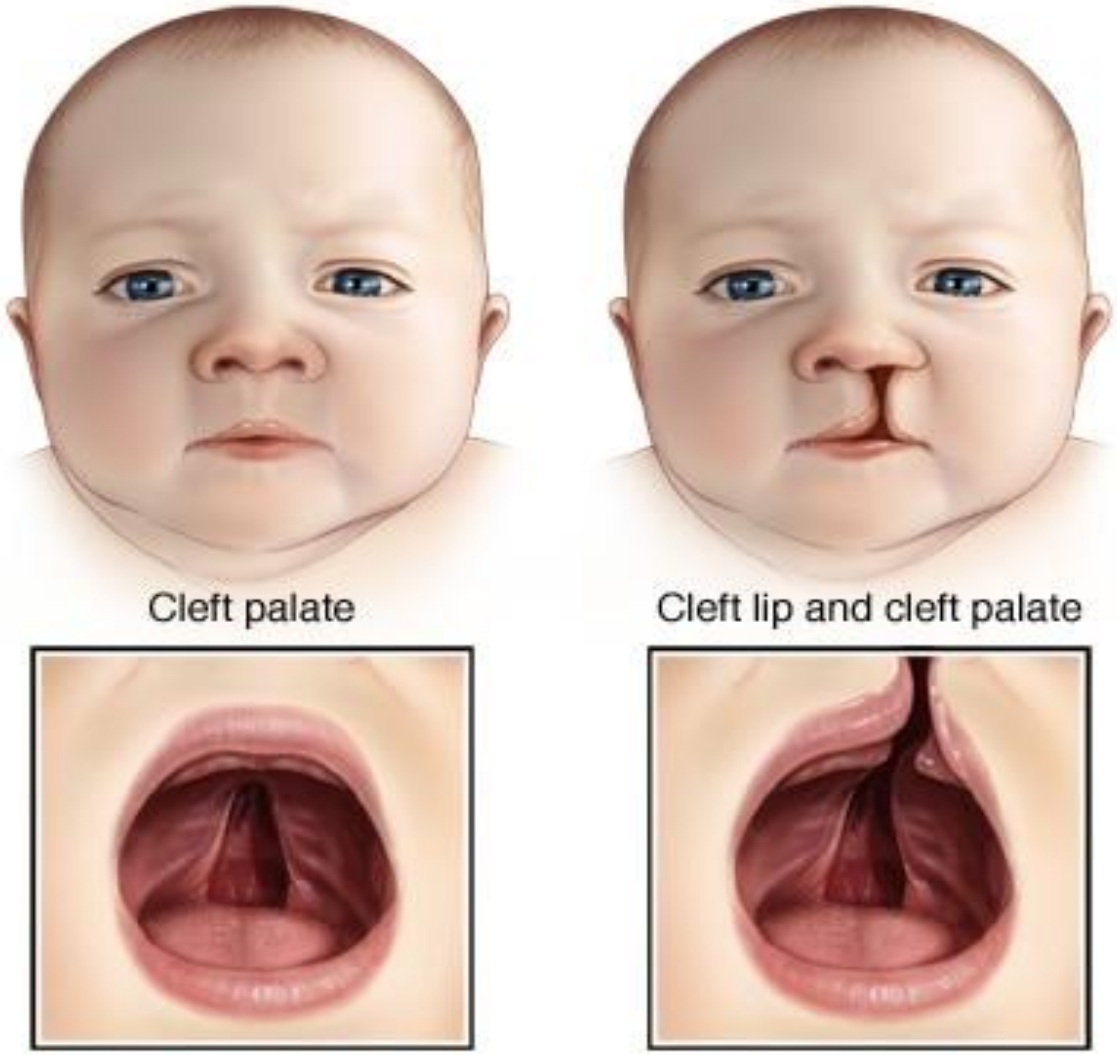

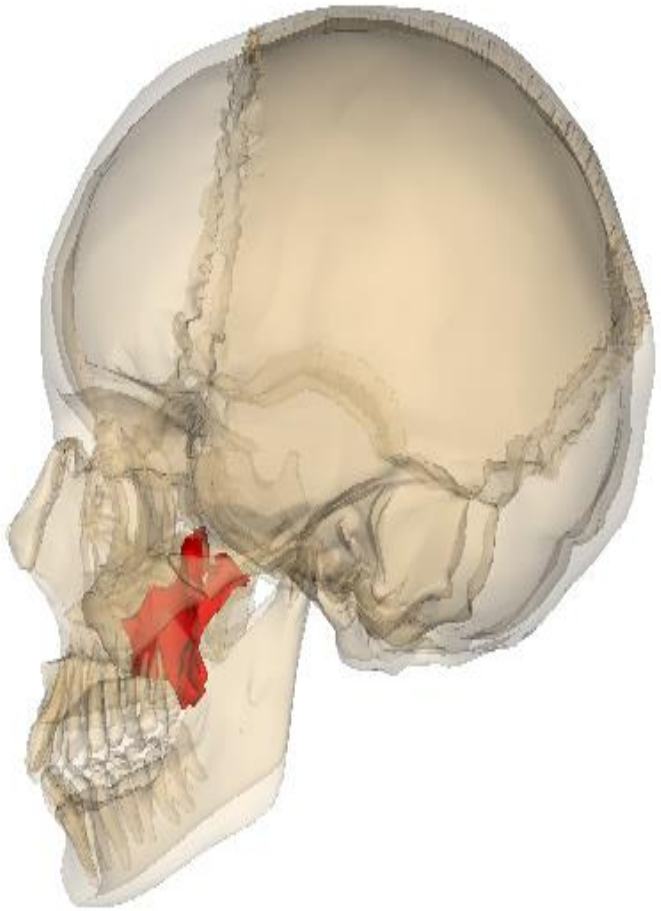

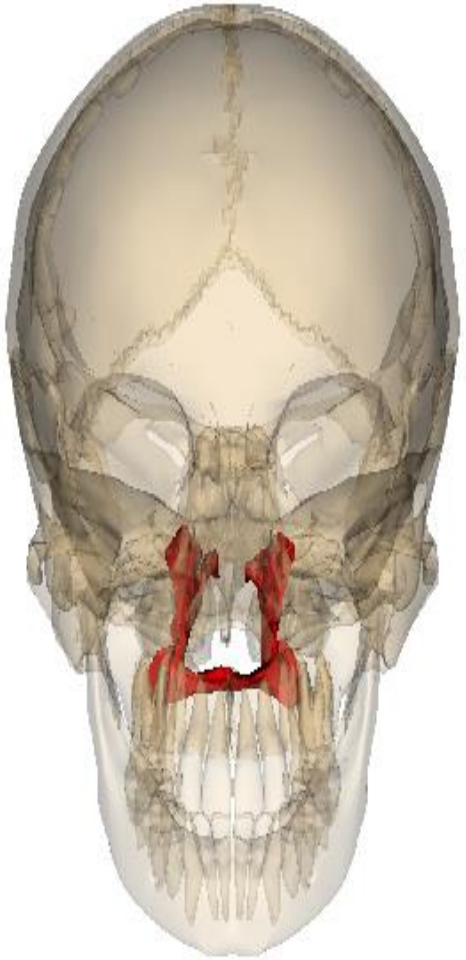

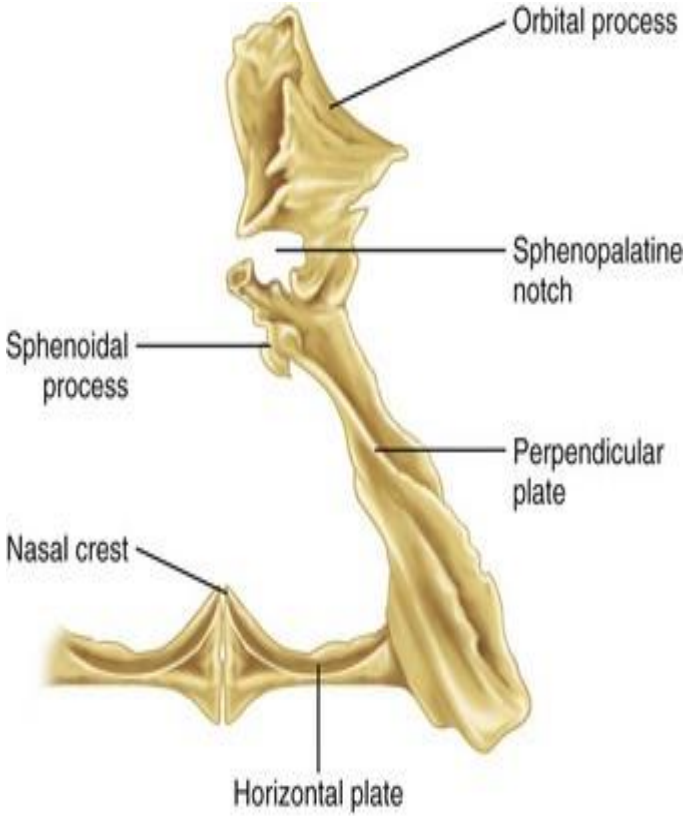

Posterior view, right palatine bone

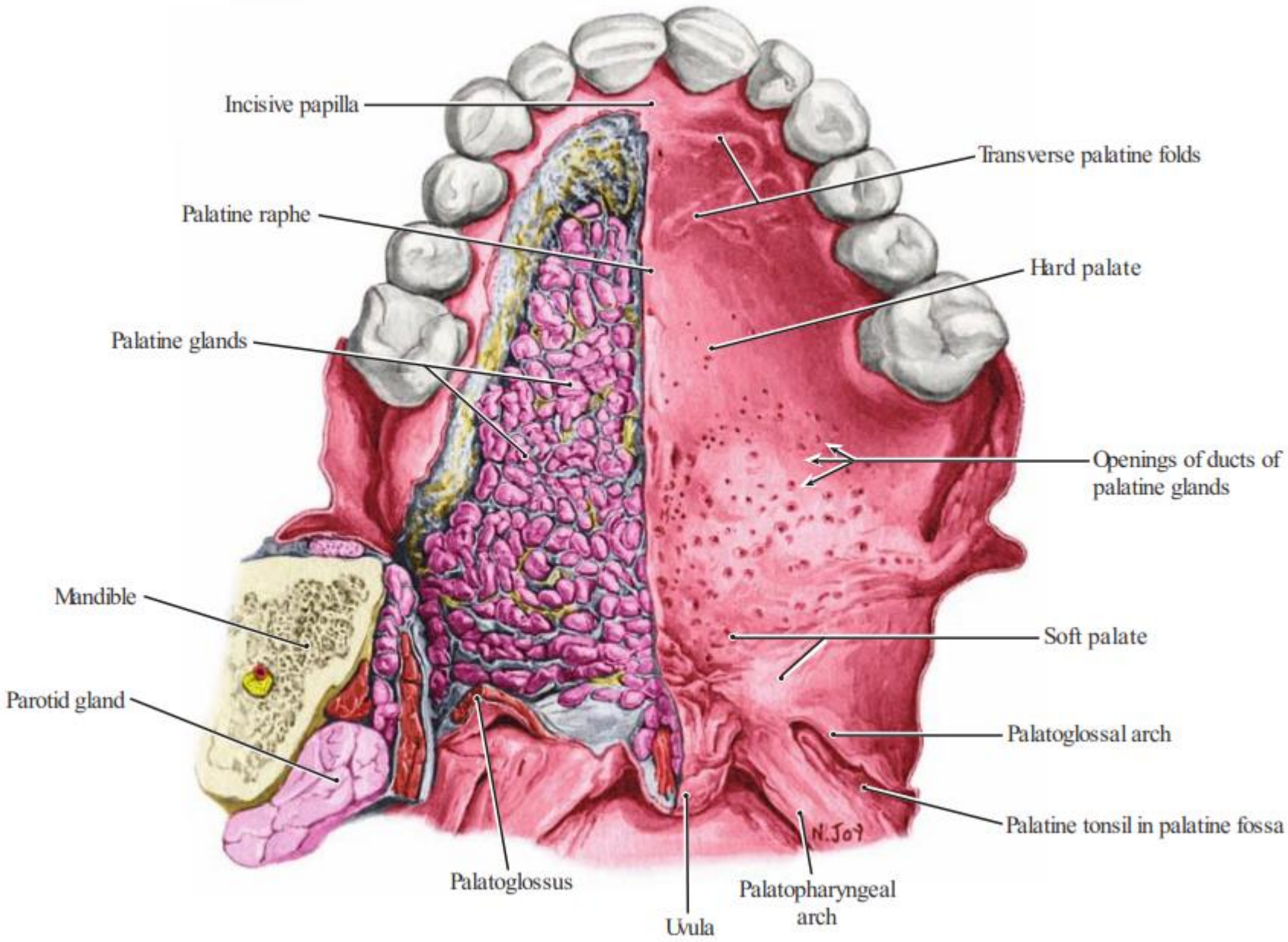

B. Inferior View

Soft Palate

The soft palate is a mobile fold attached to the posterior border of the hard palate (Fig. 11.81). Its free posterior border presents in the midline a conical projection called the **uvula.** The soft palate is continuous at the sides with the lateral wall of the pharynx.

The soft palate is composed of mucous membrane, palatine aponeurosis, and muscles.

Mucous Membrane

The mucous membrane covers the upper and lower surfaces of the soft palate.

Palatine Aponeurosis

The palatine aponeurosis is a fibrous sheet attached to the posterior border of the hard palate. It is the expanded tendon of the tensor veli palatini muscle.

Muscles of the Soft Palate

The muscles of the soft palate are the tensor veli palatini, the levator veli palatini, the palatoglossus, the palatopharyngeus, and the musculus uvulae (Fig. 11.81).

The muscle fibers of the tensor veli palatini converge as they descend from their origin to form a narrow tendon, which turns medially around the pterygoid hamulus. The tendon, together with the tendon of the opposite side, expands to form the palatine aponeurosis. When the muscles of the two sides contract, the soft palate is tightened so that the soft palate may be moved upward or downward as a tense sheet.

The muscles of the soft palate, their origins, insertions, nerve supply, and actions are summarized in Table 11.9.

TABLE 11.9 Muscles of the Soft Palate

Muscle	Origin	Insertion	Nerve Supply	Action
Tensor veli palatini	Spine of sphenoid, auditory tube	With muscle of other side, forms palatine aponeurosis	Nerve to medial pterygoid from mandibular nerve	Tenses soft palate
Levator veli palatini	Petrous part of temporal bone, auditory tube	Palatine aponeurosis	Pharyngeal plexus	Raises soft palate
Palatoglossus	Palatine aponeurosis	Side of tongue	Pharyngeal plexus	Pulls root of tongue upward and backward, narrows oropharyngeal isthmus
Palatopharyngeus	Palatine aponeurosis	Posterior border of thyroid cartilage	Pharyngeal plexus	Elevates wall of pharynx, pulls palatopharyngeal folds medially
Musculus uvulae	Posterior border of hard palate	Mucous membrane of uvula	Pharyngeal plexus	Elevates uvula

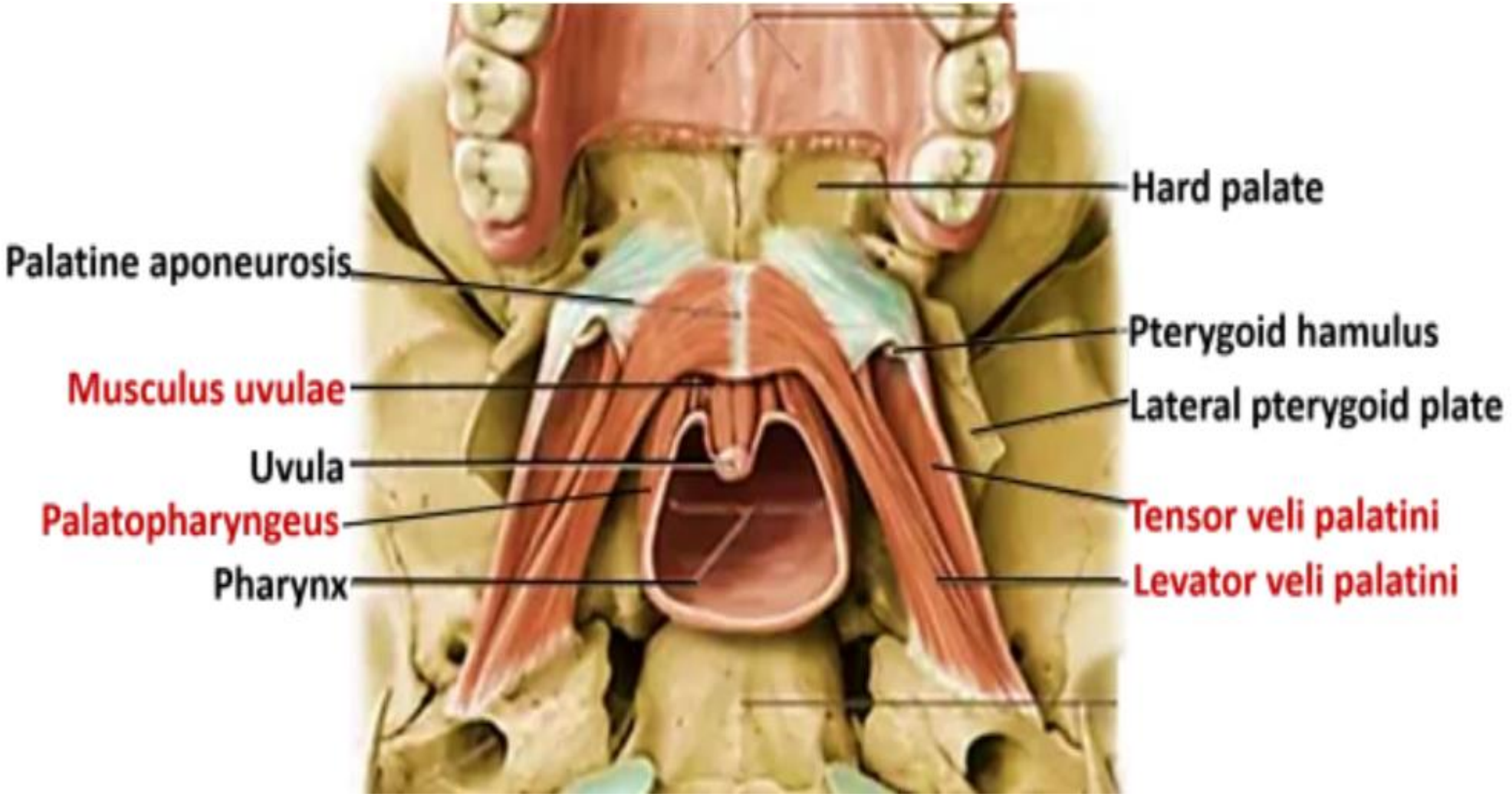
Hard palate
Palatine aponeurosis
Pterygoid hamulus
Musculus uvulae
Lateral pterygoid plate
Uvula
Tensor veli palatini
Palatopharyngeus
Pharynx
Levator veli palatini

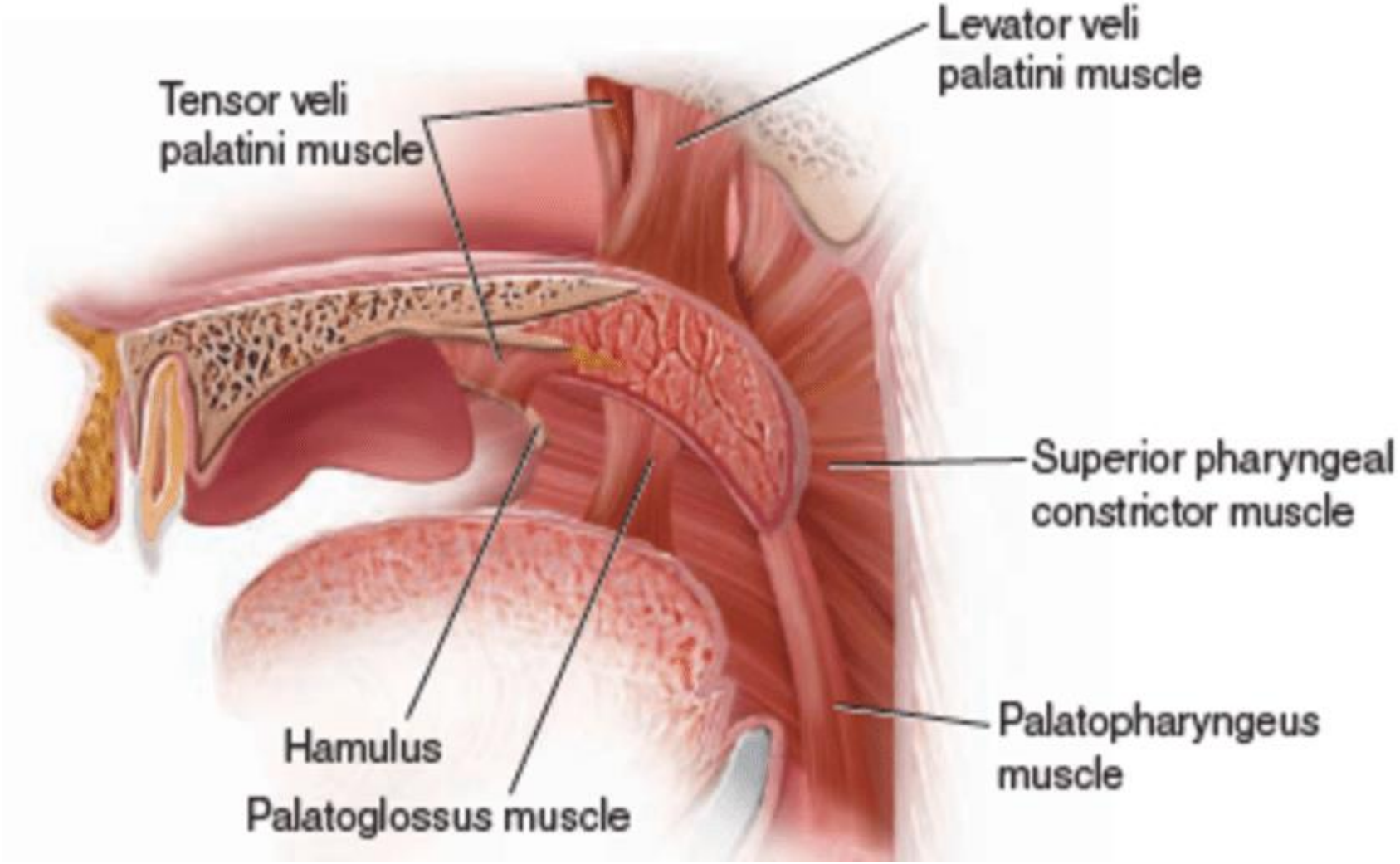
Levator veli
palatini muscle
Tensor veli
palatini muscle
Superior pharyngeal
constrictor muscle
Palatopharyngeus
muscle
Hamulus
Palatoglossus muscle

Nerve Supply of the Palate

The greater and lesser palatine nerves from the maxillary division of the trigeminal nerve enter the palate through the greater and lesser palatine foramina (Fig. 11.74). The nasopalatine nerve, also a branch of the maxillary nerve, enters the front of the hard palate through the incisive foramen. The glossopharyngeal nerve also supplies the soft palate.

Blood Supply of the Palate

The greater palatine branch of the maxillary artery, the ascending palatine branch of the facial artery, and the ascending pharyngeal artery

Movements of the Soft Palate

The pharyngeal isthmus (the communicating channel between the nasal and oral parts of the pharynx) is closed by raising the soft palate. Closure occurs during the production of explosive consonants in speech.

The soft palate is raised by the contraction of the levator veli palatini on each side. At the same time, the upper fibers of the superior constrictor muscle contract and pull the posterior pharyngeal wall forward. The palatopharyngeus muscles on both sides also contract so that the palatopharyngeal arches are pulled medially, like side curtains. By this means, the nasal part of the pharynx is closed off from the oral part.

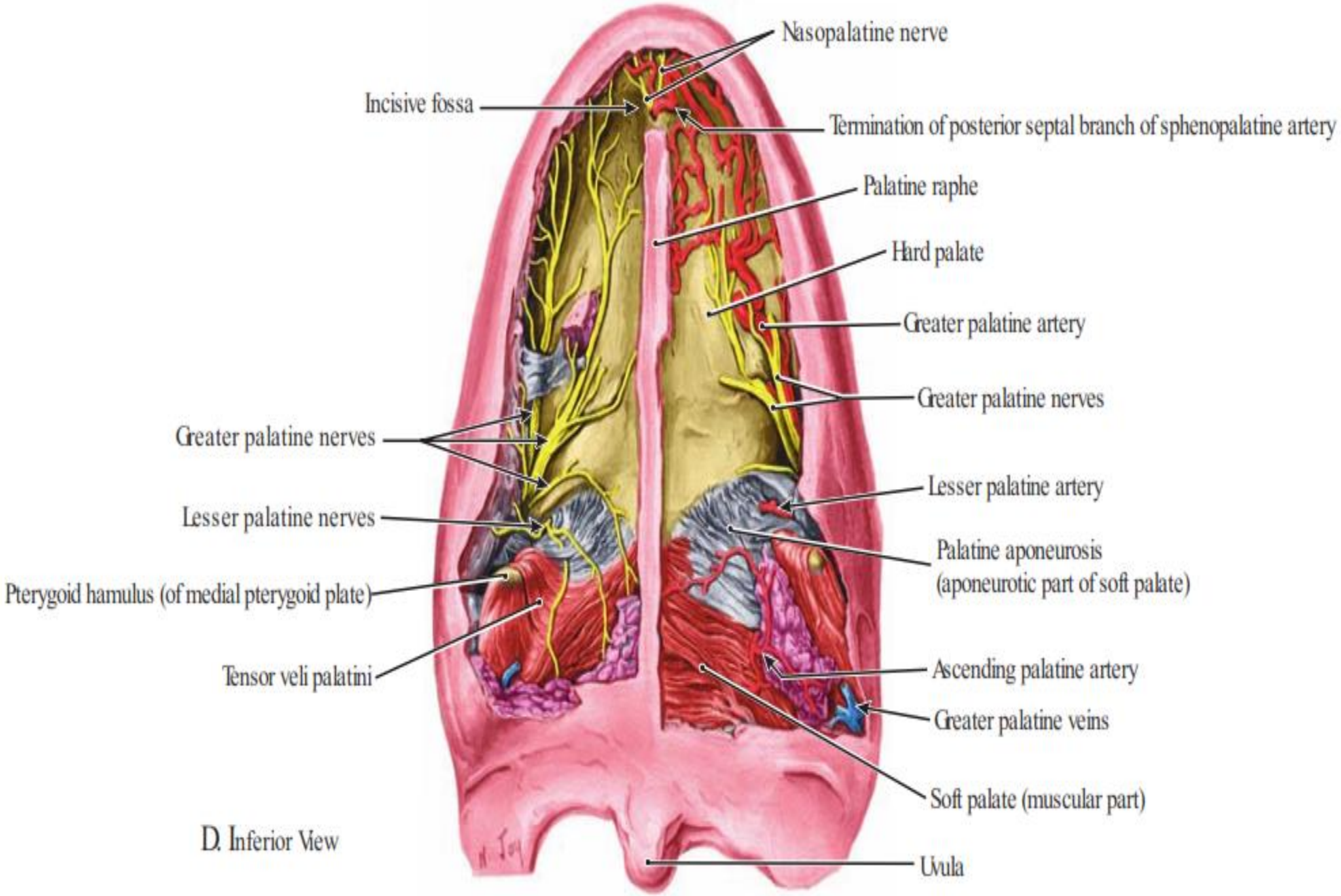
Nasopalatine nerve
Incisive fossa
Termination of posterior septal branch of sphenopalatine artery
Palatine raphe
Hard palate
Greater palatine artery
Greater palatine nerves
Greater palatine nerves
Lesser palatine artery
Lesser palatine nerves
Palatine aponeurosis
(aponeurotic part of soft palate)
Pterygoid hamulus (of medial pterygoid plate)
Tensor veli palatini
Ascending palatine artery
Greater palatine veins
Soft palate (muscular part)
D. Inferior View
Uvula

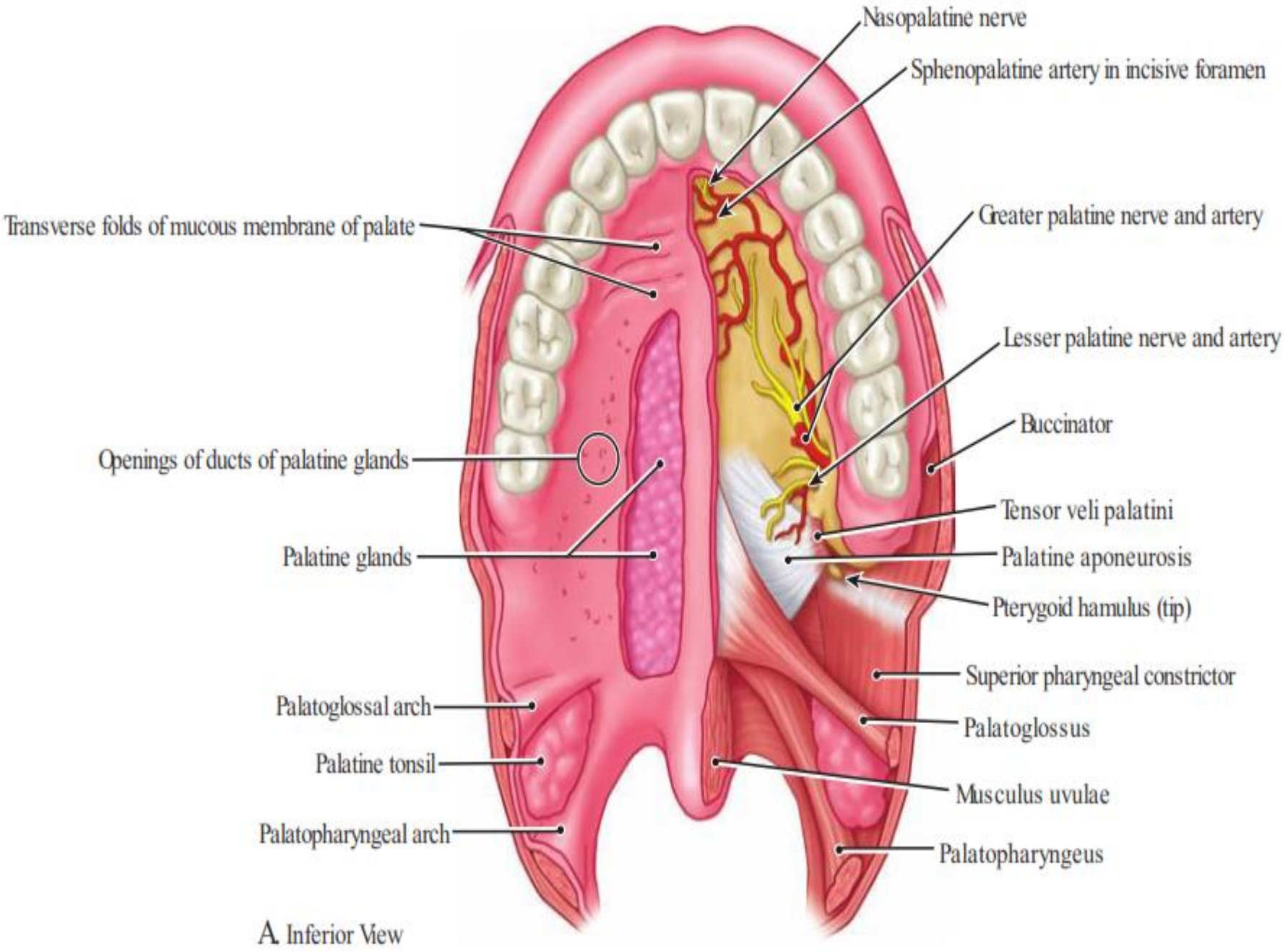
Nasopalatine nerve
Sphenopalatine artery in incisive foramen
Transverse folds of mucous membrane of palate
Greater palatine nerve and artery
Lesser palatine nerve and artery
Buccinator
Openings of ducts of palatine glands
Tensor veli palatini
Palatine glands
Palatine aponeurosis
Pterygoid hamulus (tip)
Superior pharyngeal constrictor
Palatoglossal arch
Palatoglossus
Palatine tonsil
Musculus uvulae
Palatopharyngeal arch
Palatopharyngeus
A. Inferior View

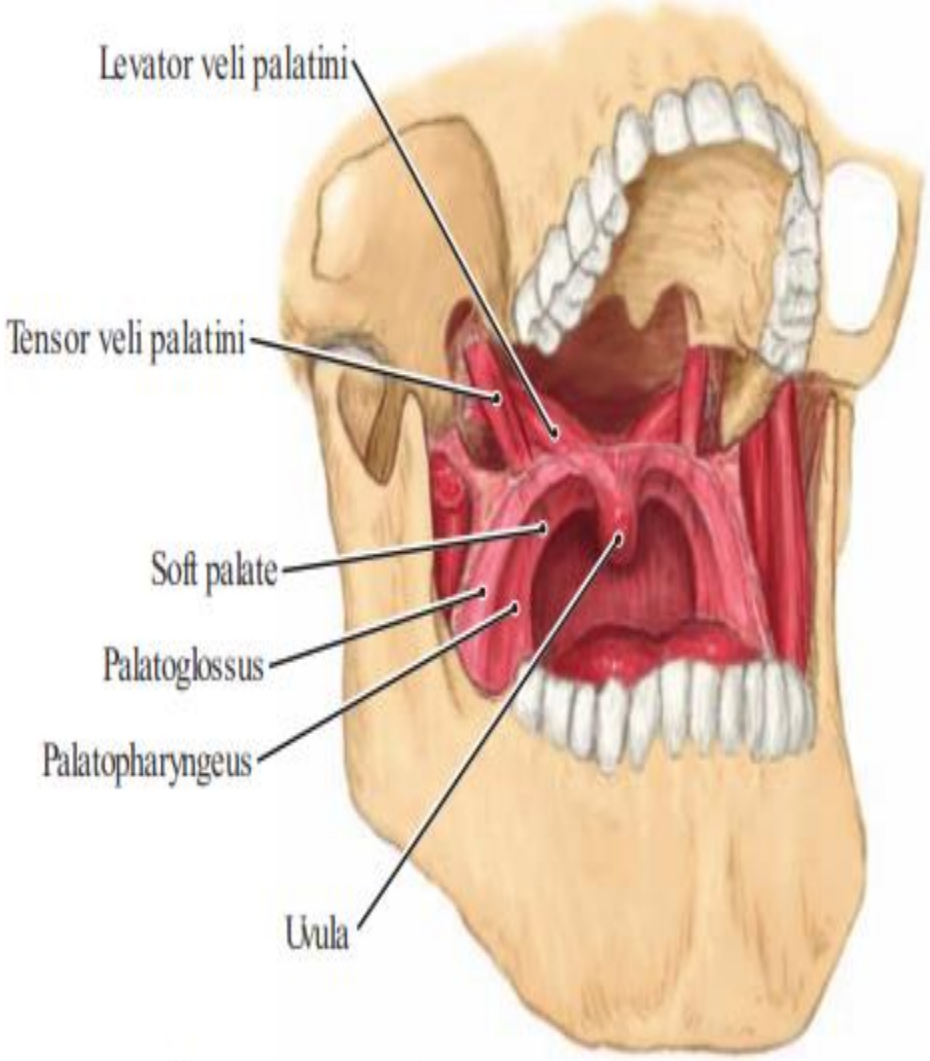

B. Anterolateral View

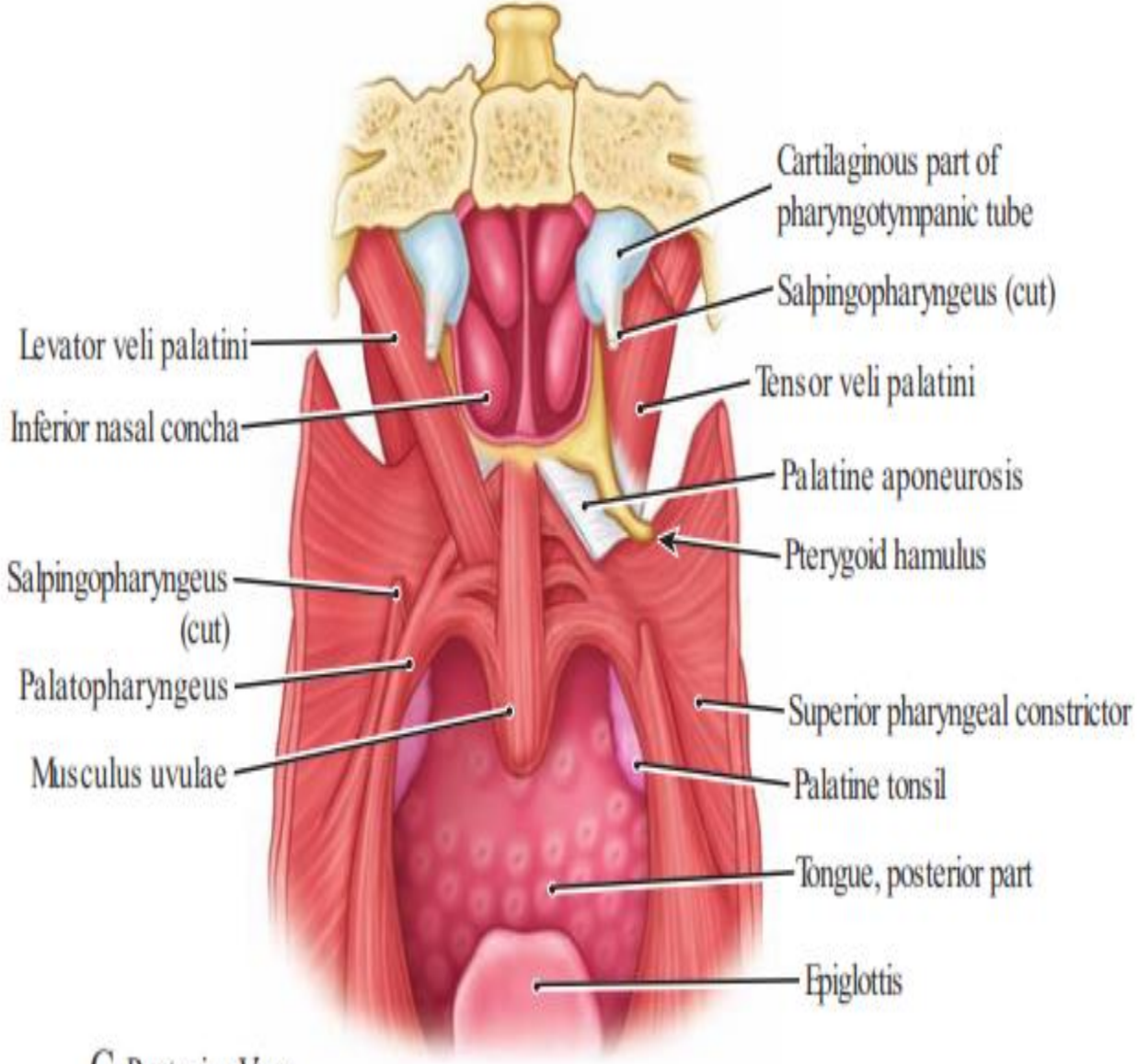

C. Posterior View

Gingiva

The Gingiva (gums) are part of the soft tissue lining of the mouth. They surround the teeth and provide a seal around them. Unlike the soft tissue linings of the lips and cheeks, most of the gums are tightly bound to the underlying bone which helps resist the friction of food passing over them. Thus when healthy, it presents an effective barrier to the barrage of periodontal insults to deeper tissue.

Changes in color, particularly increased redness, together with swelling and an increased tendency to bleed, suggest an inflammation that is possibly due to the accumulation of bacterial plaque. Overall, the clinical appearance of the tissue reflects the underlying histology, both in health and disease. When gum tissue is not healthy, it can provide a diagnosis for periodontal disease to advance into the deeper tissue of the periodontium.

The gums are divided anatomically into marginal, attached and interdental areas.

PAROTID GLAND

Position:

- It lies below the external auditory (acoustic) meatus, between the mandible and sternomastoid muscle.
- Anteriorly, it overlaps the posterior part of masseter.
- Posteriorly, it overlaps the anterior border of sternomastoid muscle.
- Its lower end lies behind and below the angle of the mandible.

Capsule:

- It is derived from the investing deep cervical fascia.

Shape: It has upper end, lower end, lateral (superficial) surface, anteromedial and posteromedial surfaces.

Relations :

Lateral (superficial) surface: It is covered by the skin, superficial fascia, branches of great auricular nerve, parotid lymph nodes and platysma.

Anteromedial surface: It is related to masseter, posterior border of the ramus of the mandible and medial pterygoid.

Posteromedial surface: It is related to the mastoid process, sternomastoid posterior belly of digastric.

Styloid process and structures attached to it and the carotid sheath and its contents .

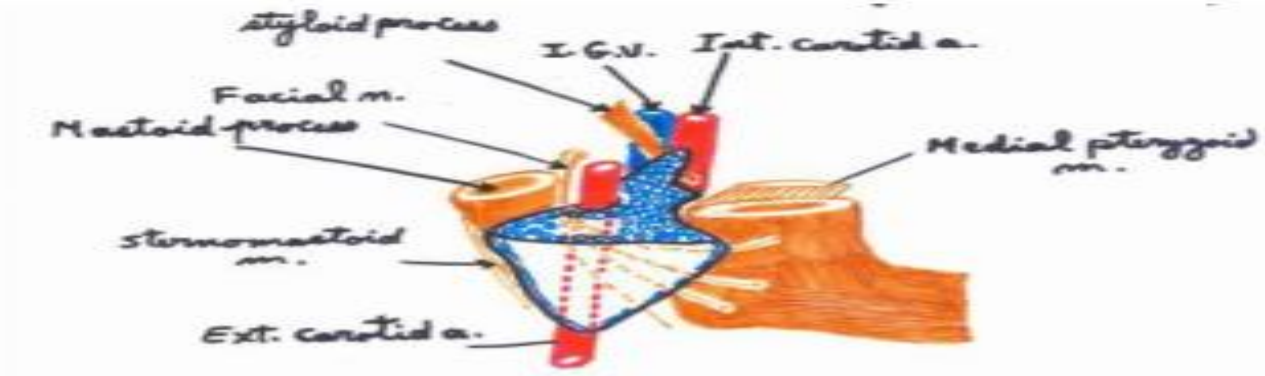

Relations of the anteromedial & posteromedial surfaces

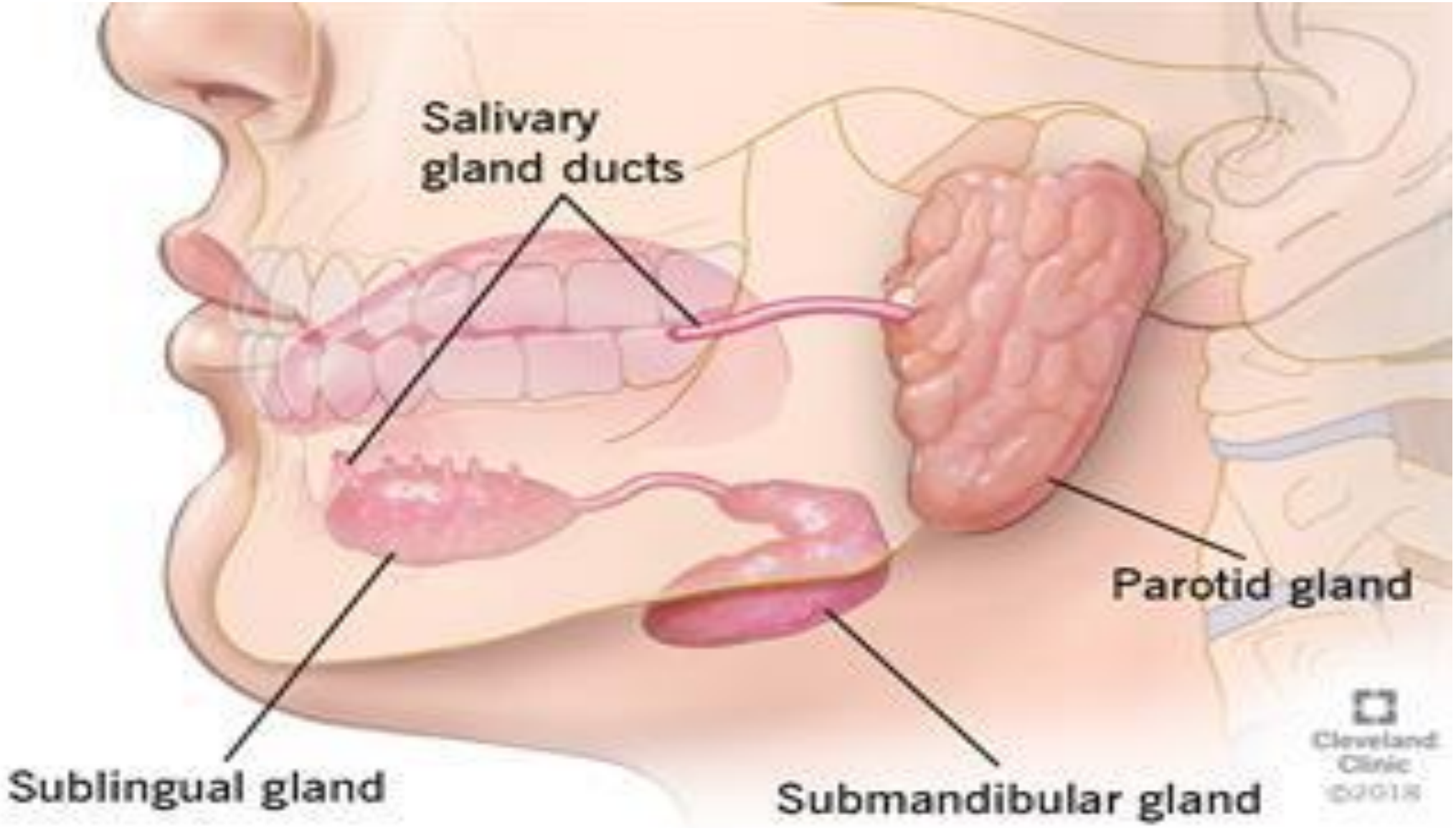
Salivary
gland ducts
Parotid gland
Sublingual gland
Submandibular gland
Cleveland
Clinic
©2018

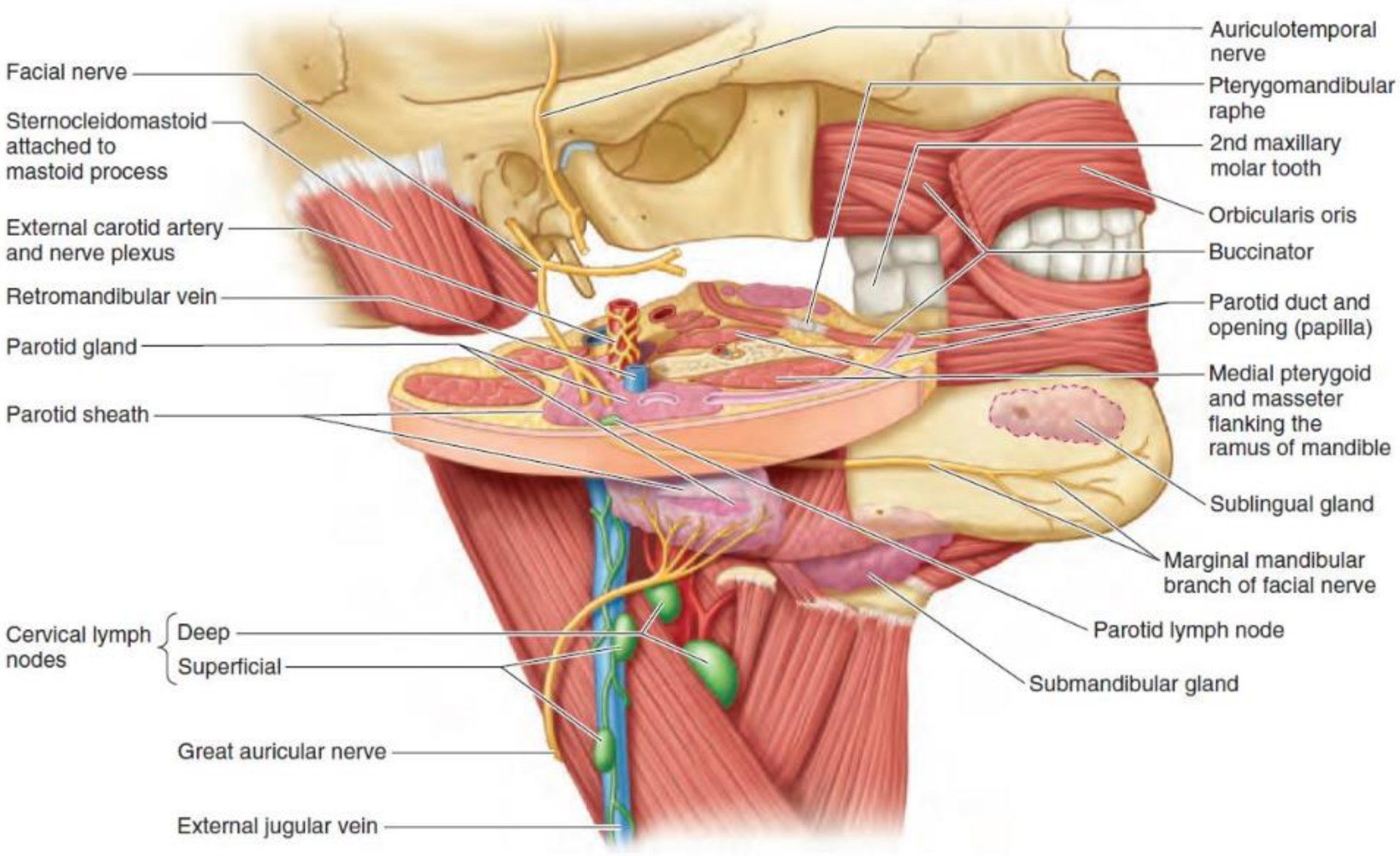

Relationships of parotid gland.

Structures within the parotid gland:

1. Facial nerve : it is the most superficial structure, it enters the gland through its posteromedial surface, divides inside the gland into 5 terminal branches which exit from the upper, anterior & lower borders .

2. Retromandibular vein : it is intermediate in position, it is formed inside the gland by the union of the superficial temporal & maxillary veins , it divides at the lower border of the gland into anterior & posterior divisions .

3. External carotid artery : it is the deepest structure, it enters the gland through its posteromedial wall, and divides in the gland into 2 terminal branches :

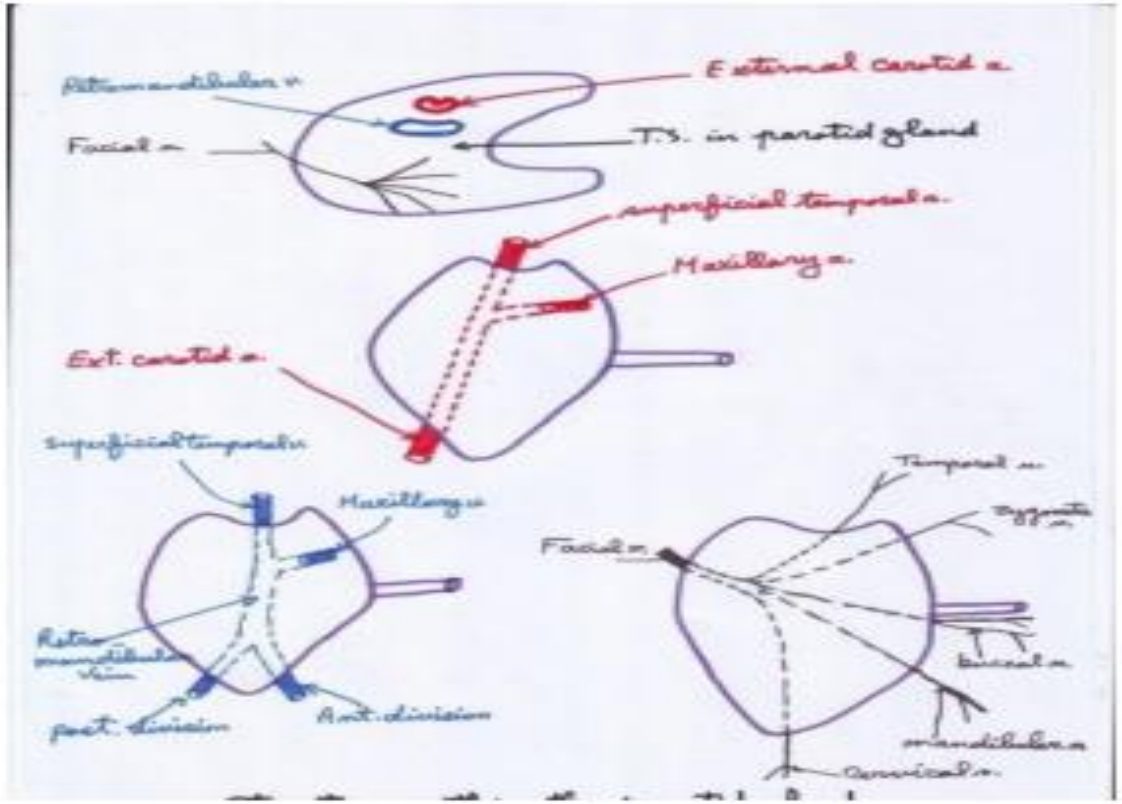

a) Maxillary artery, which exits through the anteromedial surface .
b) Superficial temporal artery, which emerges at the upper border of the gland .

4. Auriculo-temporal nerve : it enters the gland through the upper part of the anteromedial surface, and supplies the gland by sensory & parasympathetic fibers, and exit of the gland at its upper border .

5- Deep parotid lymph nodes : few lymph nodes in the gland .

Parotid duct:

- It is about 5 cm long. It arises from the anterior part of the gland, and runs forward on the masseter a finger breadth below & parallel to the zygomatic arch ., and pierces the buccinator to open in the vestibule of the mouth opposite the upper 2nd. molar tooth.
- The accessory part of the gland lies above the duct.

Surface anatomy:

It corresponds to the middle 1/3 of a horizontal line drawn from the tragus of the ear to a point midway between the ala of the nose and the angle of the mouth.

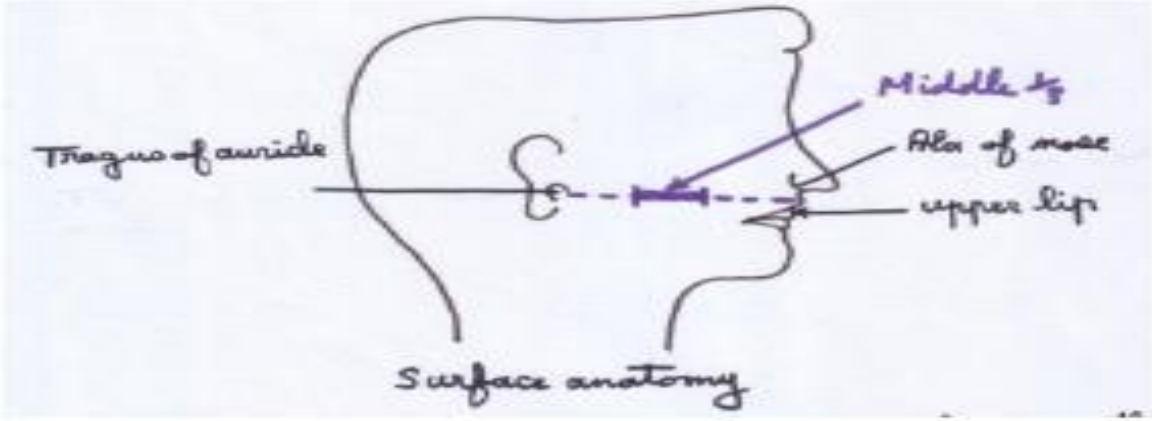

Blood supply of the parotid gland:

- Arterial supply by twigs from the terminal part of the external carotid artery.
- Venous blood drain into retromandibular vein.
- Lymphatic drainage into the deep & superficial parotid lymph nodes .

Nerve supply:

1. Sensory: a) great auricular nerve, supplies the capsule .
b) auriculotemporal nerve, supplies the gland interstitial tissue.
2. Sympathetic fibers from plexus around the external carotid artery.
3. Parasympathetic (secretomotor) fibers from the otic ganglia

Submandibular Salivary Gland

- It lies in the digastric triangle overlapping its boundaries. It consists of:
1. Large superficial part.
2. Smaller deep part.

The superficial part has 3 surfaces:
1. Inferolateral surface: covered by skin, superficial fascia, platysma and deep fascia. Cervical branch of facial nerve , facial vein .
2. Lateral surface: it is related to the submandibular fossa of the mandible and medial pterygoid muscle and the facial artery.
3. Medical surface: it is related to:

a) Mylohyoid muscle . b) Hyoglossus.
c) Structures on the hyoglossus muscle: lingual nerve, submandibular ganglion, hypoglossal nerve and deep lingual vein.

- The deep part lies between the mylohyoid and hyoglossus.

- The submandibular duct:
- It is 5 cm long. It begins from the medial surface of the superficial part. It runs between the mylohyoid and hyoglossus through the deep part, then, it passes between the sublingual salivary gland and genioglossus to open in the floor of the mouth, at the summit of the sublingual fold.
- On the hyoglossus, it lies between the lingual and hypoglossal nerves. Anteriorly, the lingual nerve turns around its lateral side, to become medial to it.

- Arterial supply: facial artery and lingual artery.

- Nerve supply:
1. Parasympathetic secretomotor fibers from the submandibular ganglion.
2. Sympathetic plexus around the facial artery.
3. Sensory fibers from the lingual nerve.

Sublingual Salivary Gland

- It lies in the sublingual fossa of the mandible under cover of the mucous membrane of the mouth.

Relations:

- Superiorly: mucous membrane of the floor of the mouth.
- Inferiorly: mylohyoid muscle.
- Laterally: sublingual fossa of the mandible.
- Medially: genioglossus.
- Sublingual ducts: 10-20 ducts which open on the summit of the sublingual fold.

- Arterial supply: sublingual artery from the lingual artery.

- Nerve supply:

1. Parasympathetic secretory fibers from the submandibular ganglion.
2. Sympathetic plexus around the nearest arteries.
3. Sensory fibers from the lingual nerve.

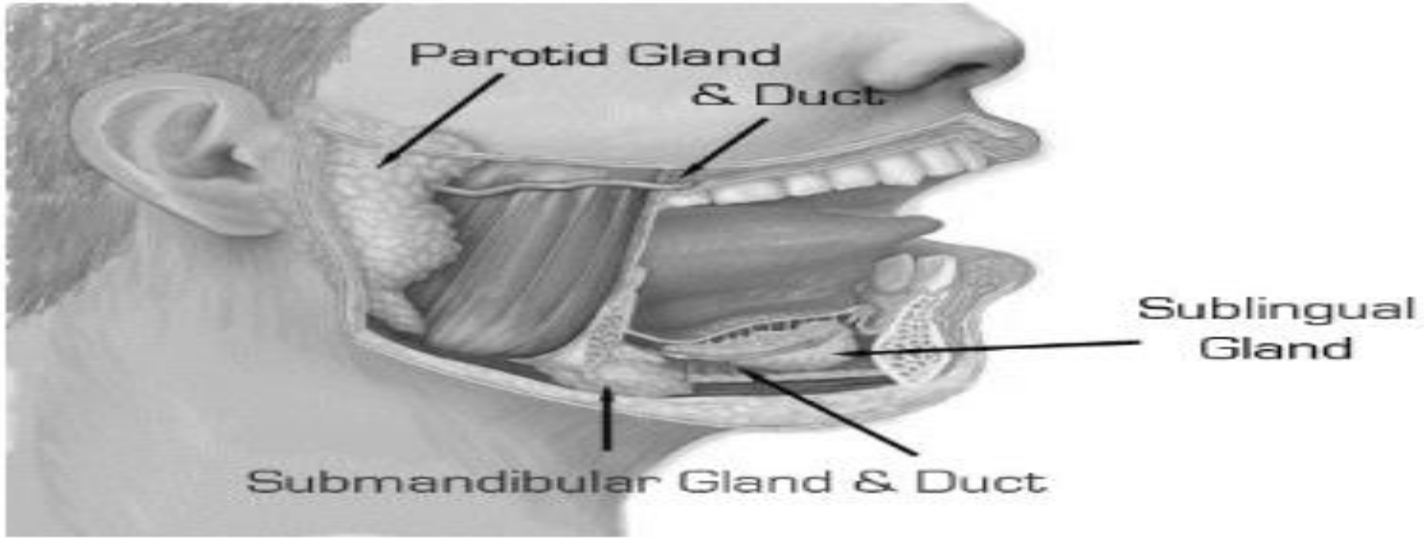

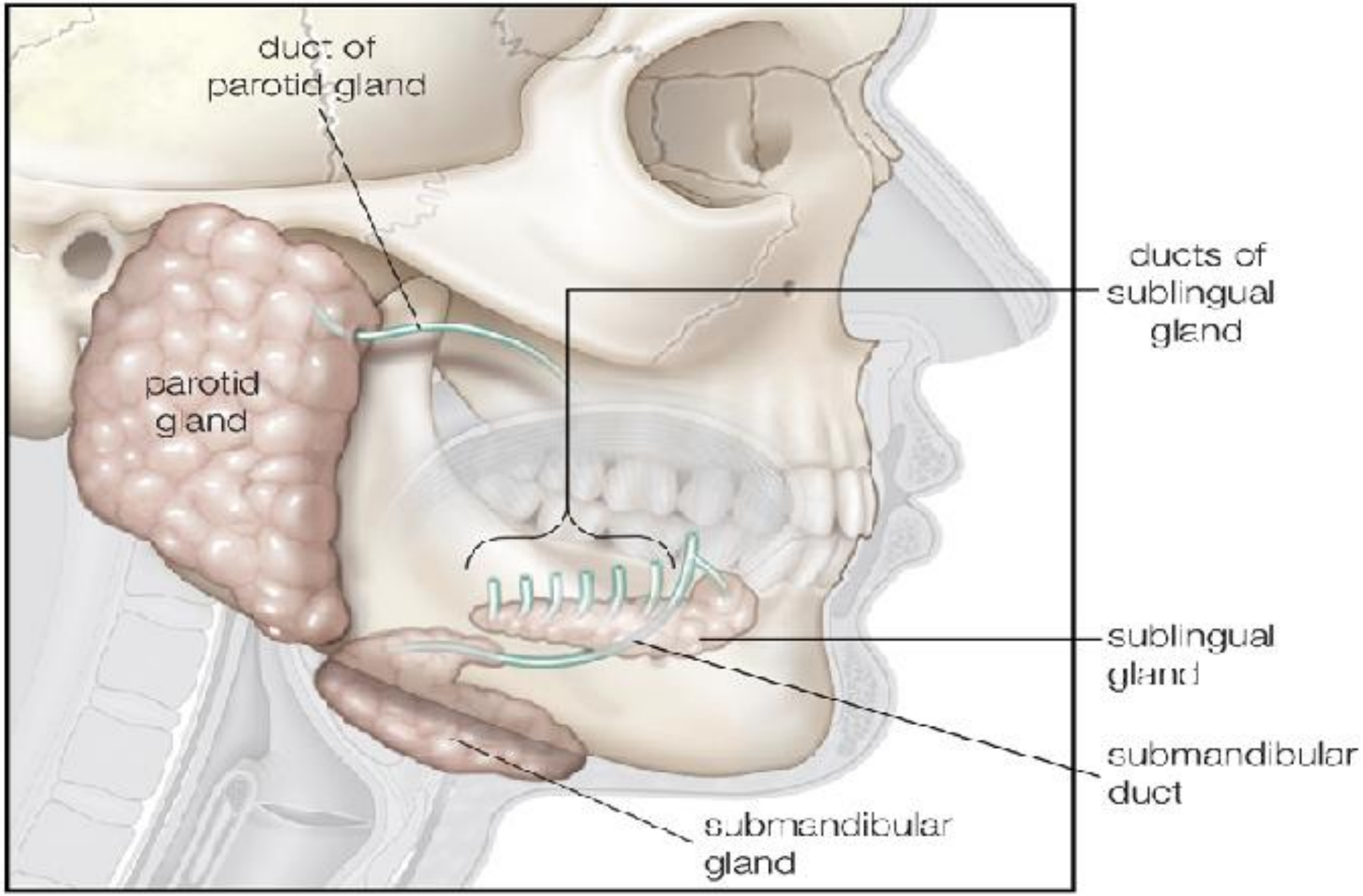
duct of
parotid gland
parotid
gland
ducts of
sublingual
gland
sublingual
gland
submandibular
duct
submandibular
gland

THANK YOU

THE EYE

PREPARED BY:

Dr. REYADH AL-RASHIDI

Vision or Sight

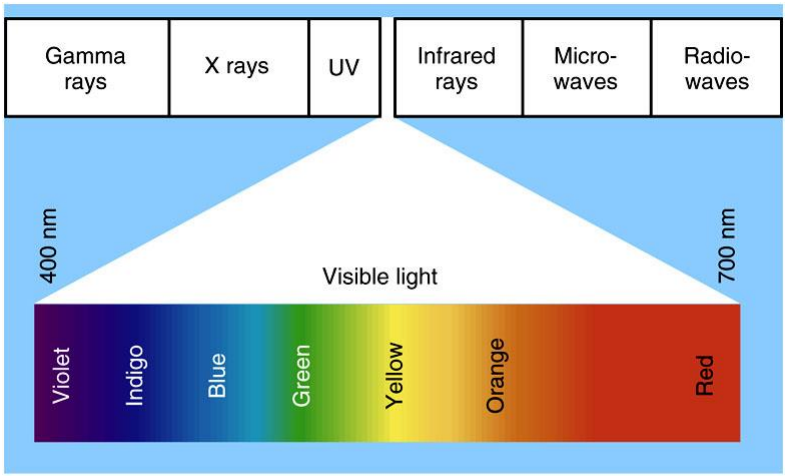

(a) Electromagnetic spectrum

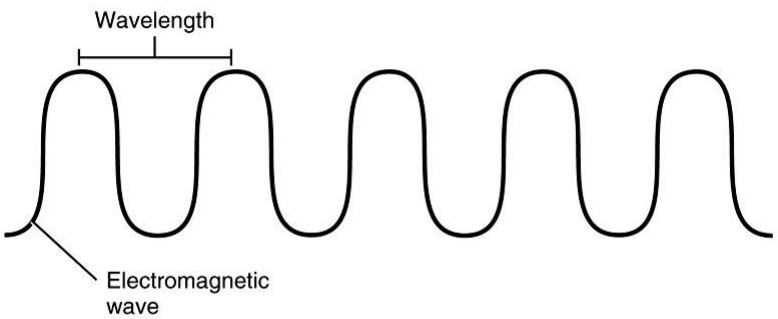

(b) An electromagnetic wave

- Visible light: 400-700 nm.

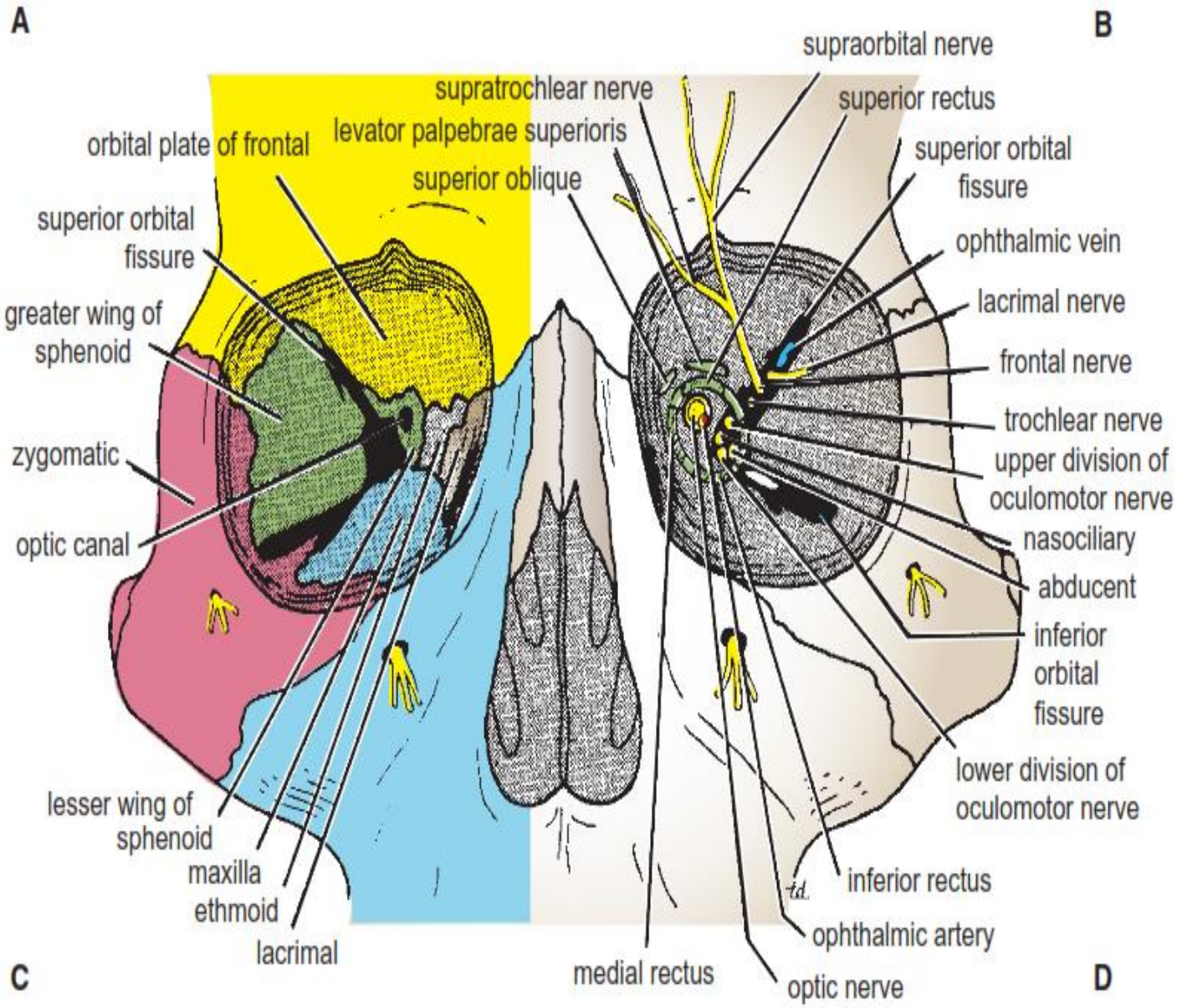

FIGURE 11.18 **A.** Right eyeball exposed from in front. **B.** Muscles and nerves of the left orbit as seen from in front. **C.** Bones forming the walls of the right orbit. **D.** The optic canal and the superior and inferior orbital fissures on the left side.

Accessory Structures of the Eye

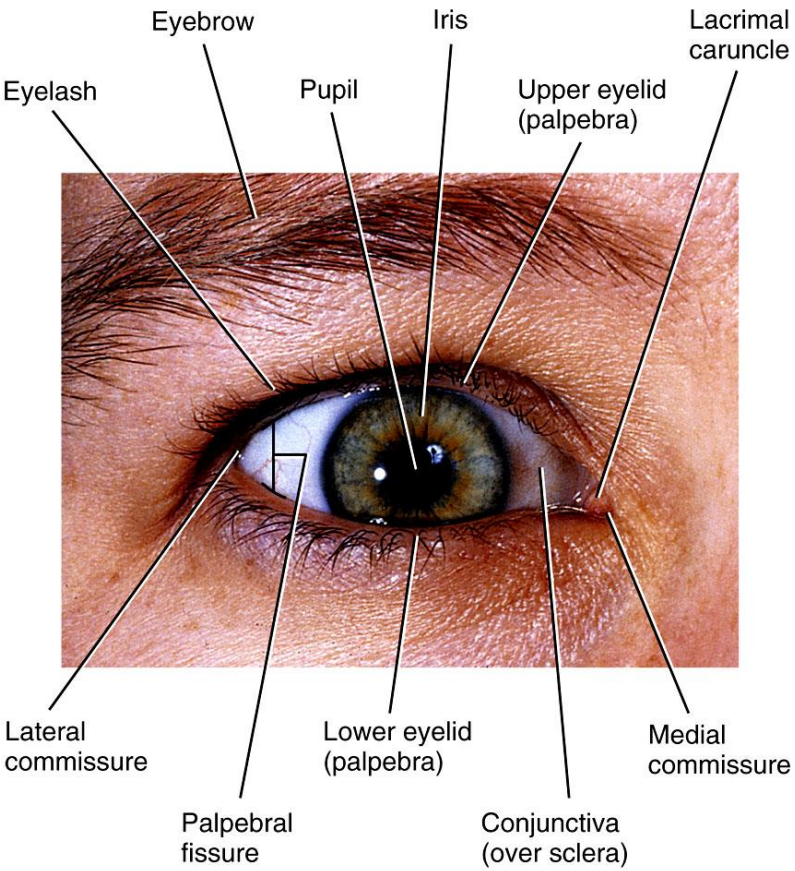

- Eyelids or palpebrae-
- Eyelashes and eyebrows-
- Extrinsic eye muscles-

Anatomy of the Eyeball

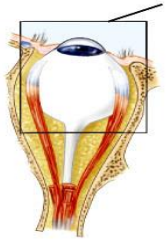

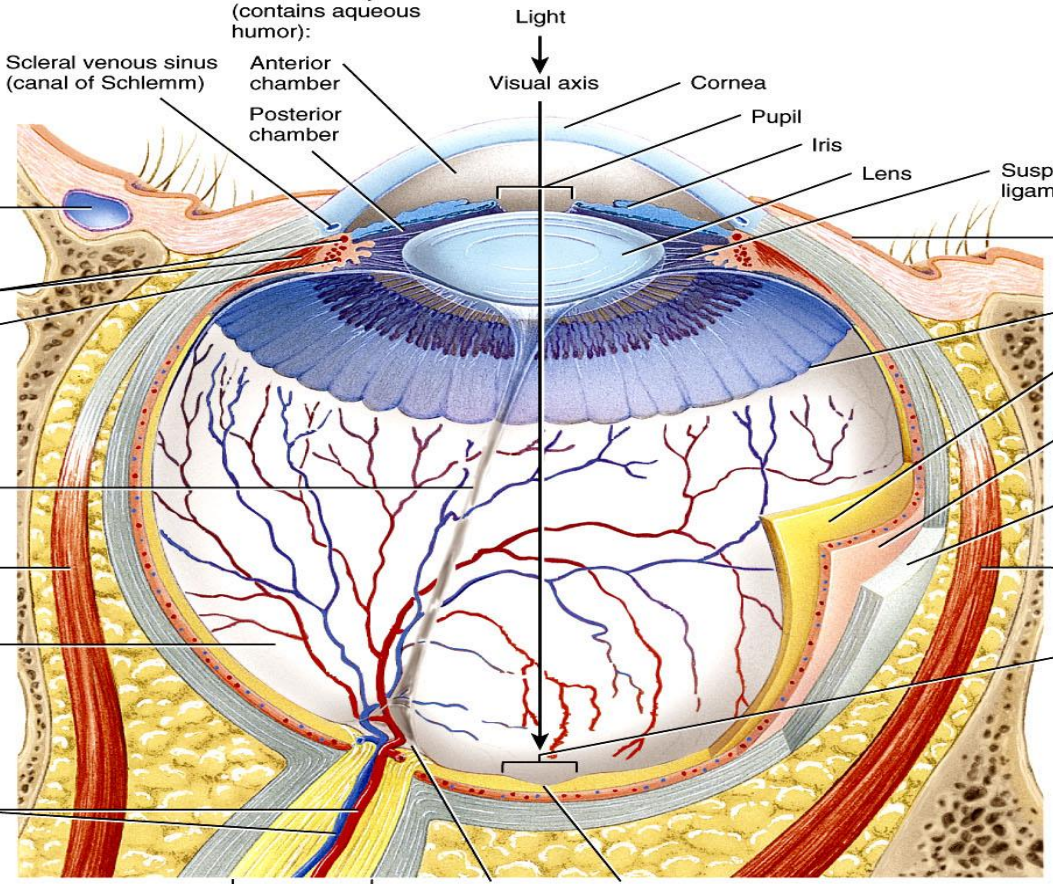

Superior view of transverse section of right eyeball

Accessory Structures of the Eye

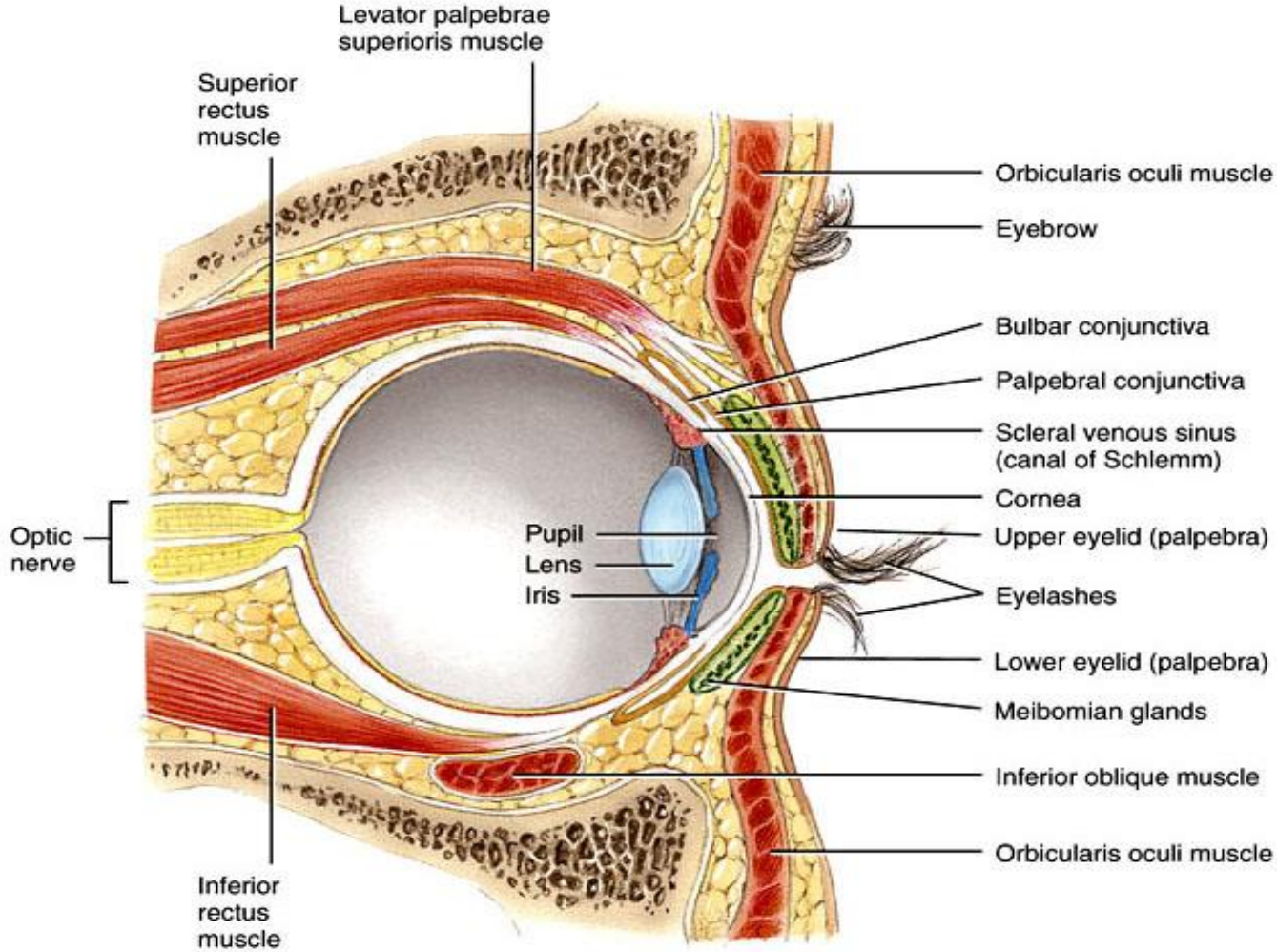

(a) Sagittal section of eye and its accessory structures

The Lacrimal Apparatus

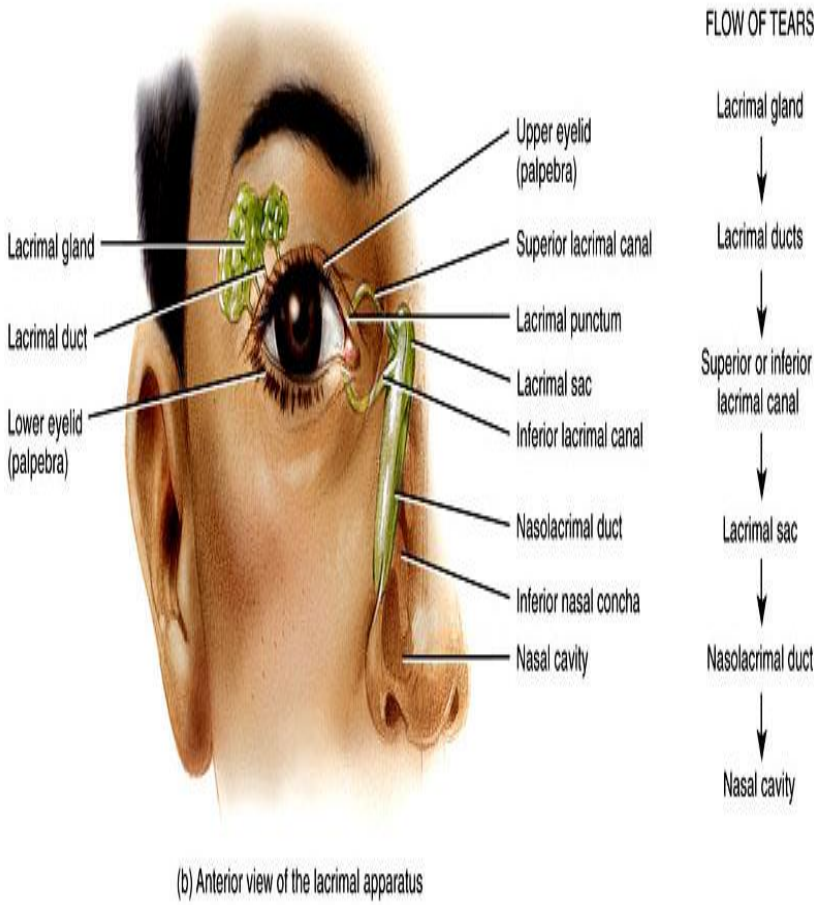

(b) Anterior view of the lacrimal apparatus

- Tears from the lacrimal glands→ lacrimal canals→ lacrimal sac → nasolacrimal duct → nasal cavity

Wall of the Eyeball

- Three layers:
  - outer layer
    - Sclera
    - Cornea
  - middle layer
    - Choroid
    - Ciliary body consists of ciliary processes and ciliary muscle
    - Iris

    inner layer
    - Retina
    - Optic disc & fovea centralis

Note : Lens is not considered to be part of one of the layers of the eye.

Responses of the Pupil to Light

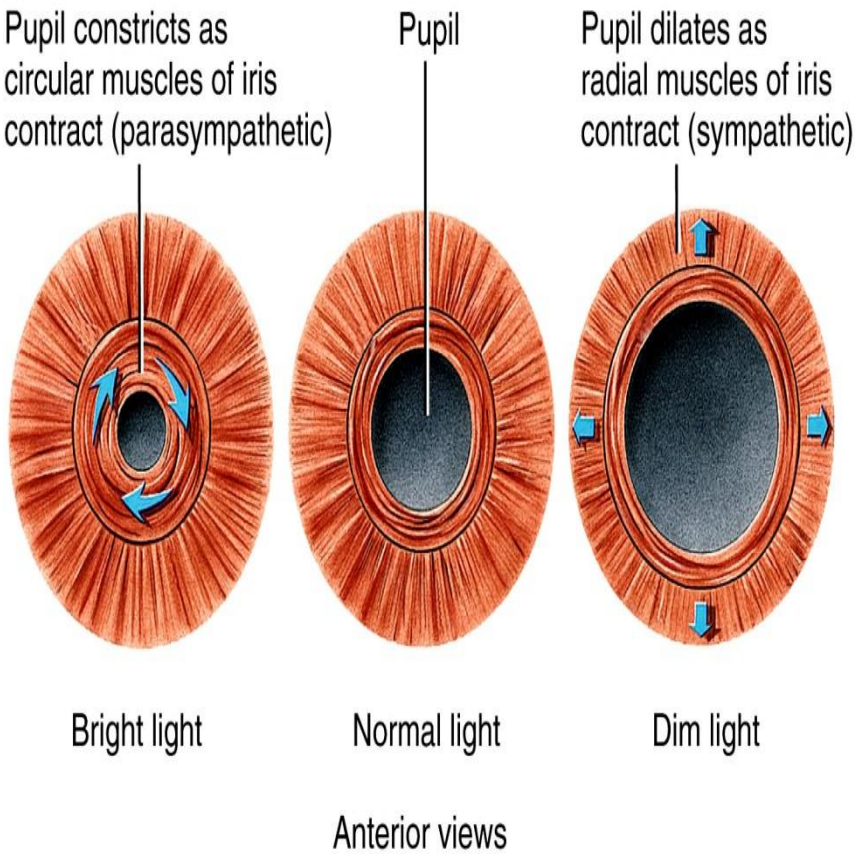

- Pupil is an opening in the center of the iris.
- Contraction of the circular muscles of the iris causes constriction of the pupil.
- Contraction of the radial muscles causes dilation of the pupil.

Interior of the Eyeball

- Lens-
  - lack blood vessels, consists of a capsule with proteins (crystallins) in layers; transparent.
- Lens divides the eyeball into two cavities: anterior and posterior.
- Anterior cavity- further divided into anterior and posterior chambers. Both are filled with aqueous humor.
- Posterior cavity (vitreous chamber)-filled with vitreous humor.

Accommodation and the Near Point of Vision

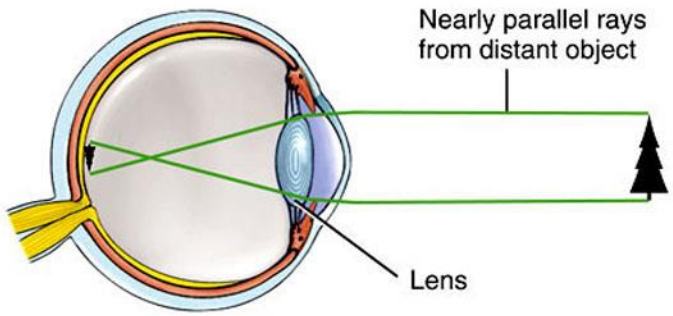

(b) Viewing distant object

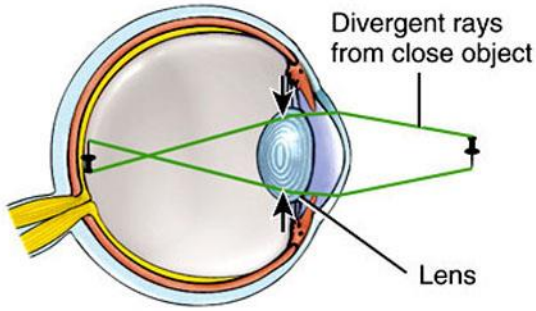

(c) Accommodation

- Increase in the curvature of the lens for near vision is called accommodation.
- Near point of vision is the minimum distance from the eye that an object can be clearly focused.

Refraction Abnormalities and their Correction

- Nearsightedness (myopia)- close objects seen clearly. Image is focused in front of the retina. Correction- use of concave lens.
- Farsightedness (hyperopia)- distant objects seen clearly. Image is focused behind the retina. Correction- use of convex lens.

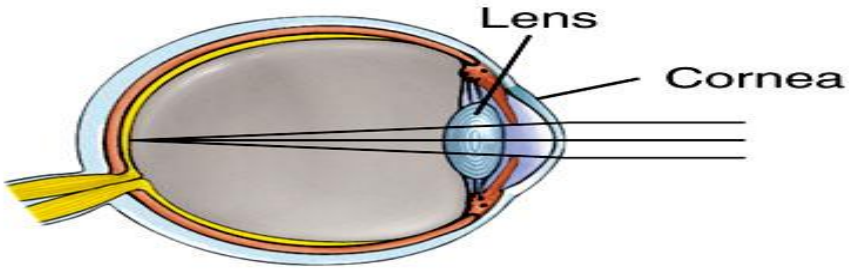

(a) Normal (emmetropic) eye

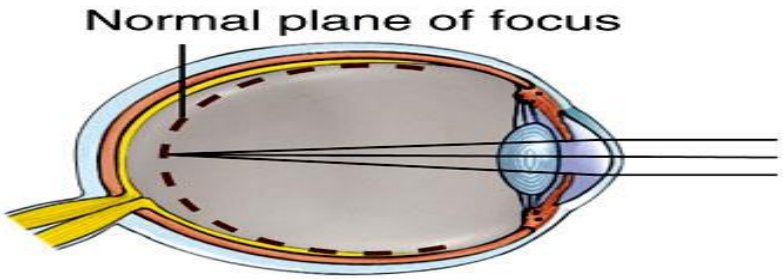

(b) Nearsighted (myopic) eye, uncorrected

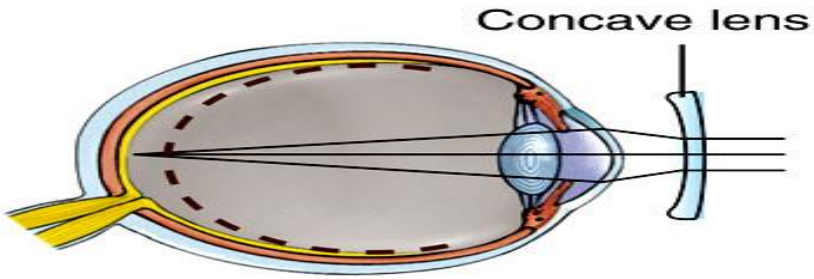

(c) Nearsighted (myopic) eye, corrected

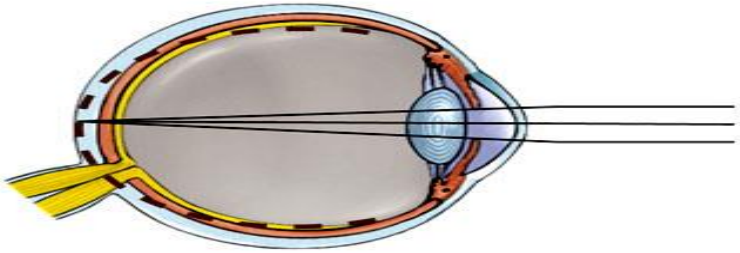

(d) Farsighted (hyperopic) eye, uncorrected

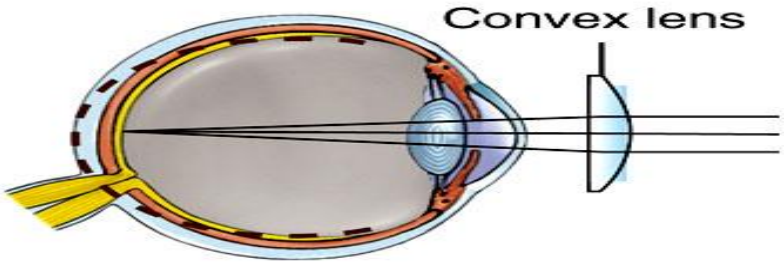

(e) Farsighted (hyperopic) eye, corrected

Structure of Rod and Cone Photoreceptors

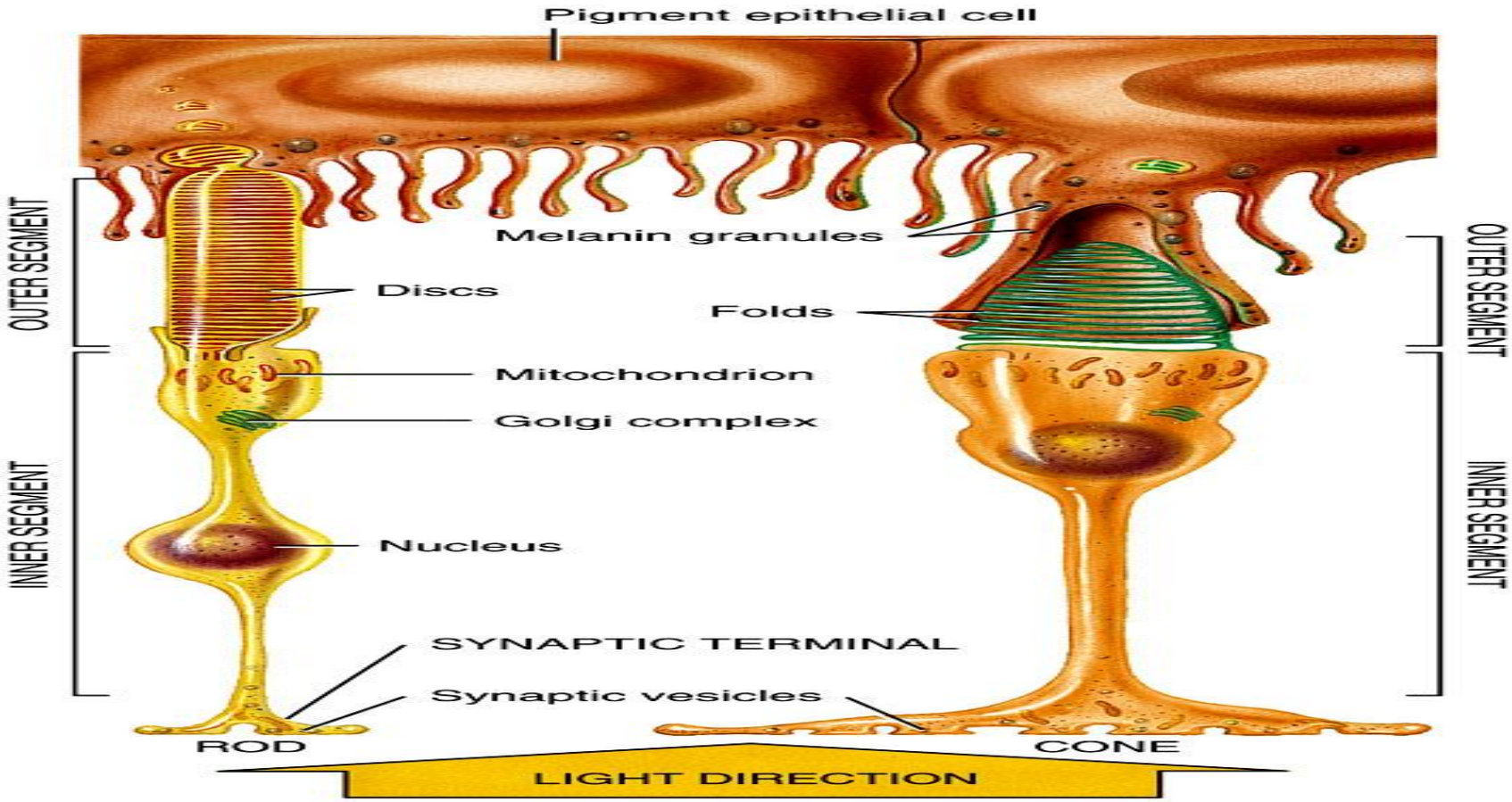

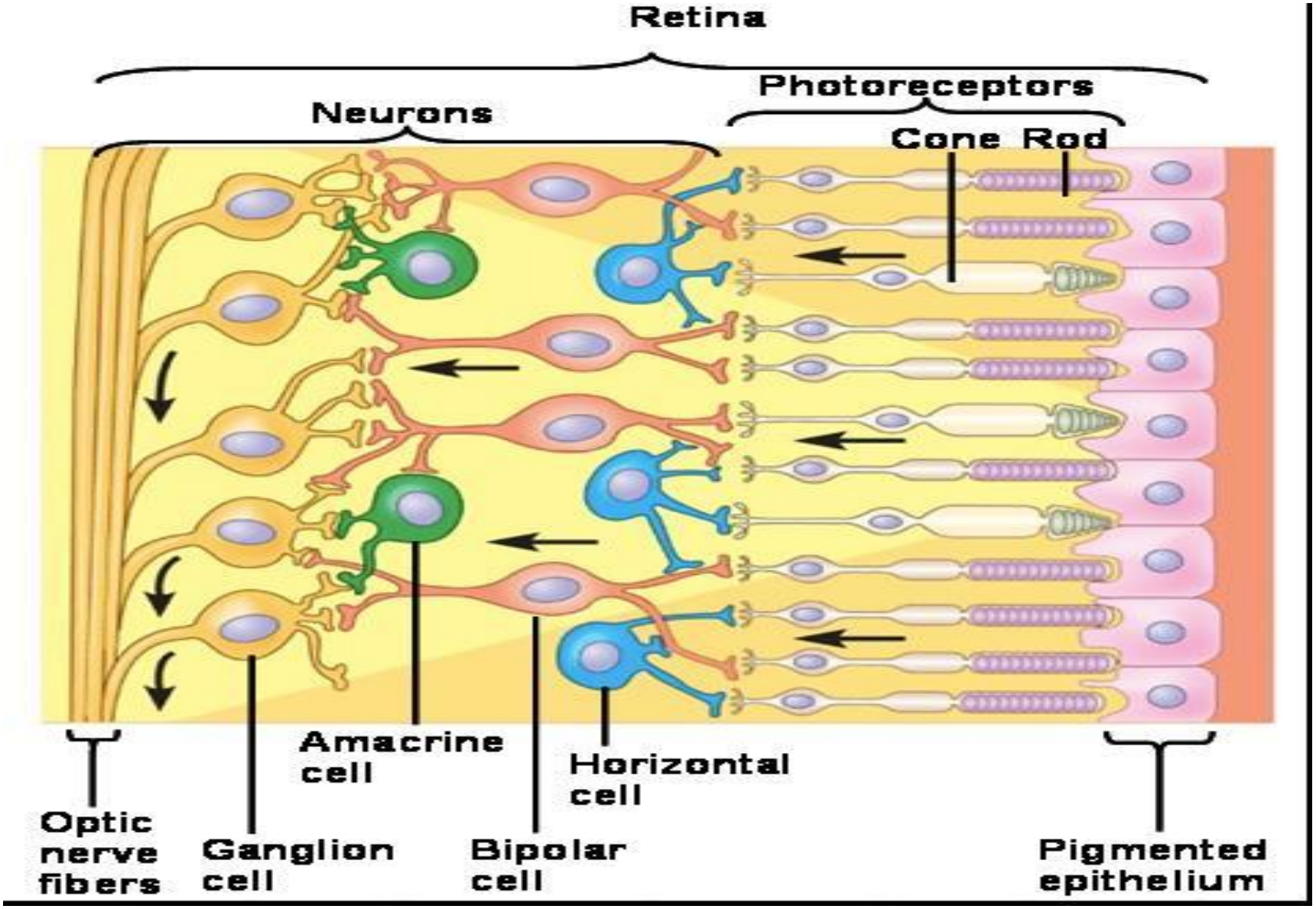
Retina
Photoreceptors
Neurons
Cone
Rod
Amacrine cell
Horizontal cell
Optic nerve fibers
Ganglion cell
Bipolar cell
Pigmented epithelium

Rods and Cones

- Named after the shapes of their outer segments.
- Rod- one type-
- Cones- three types: red, green and blue.

Color Blindness and Night Blindness

- Color blindness- inherited inability to distinguish between certain colors.
  - Result from the absence of one of the three types of cones.
  - Most common type: red-green color blindness.
- Night blindness or Nyctalopia- vitamin A deficiency.

The visual pathway

- Photons → Cornea → aqueous humor → pupil → Lens → vitreous humor – Retina → Photoreceptor stimulation (rods and cones) → action potentials in bipolar neurons → ganglion cells → optic nerve→ optic chiasm→ optic tract→ thalamus→ primary visual area of cerebral cortex (occipital lobe).

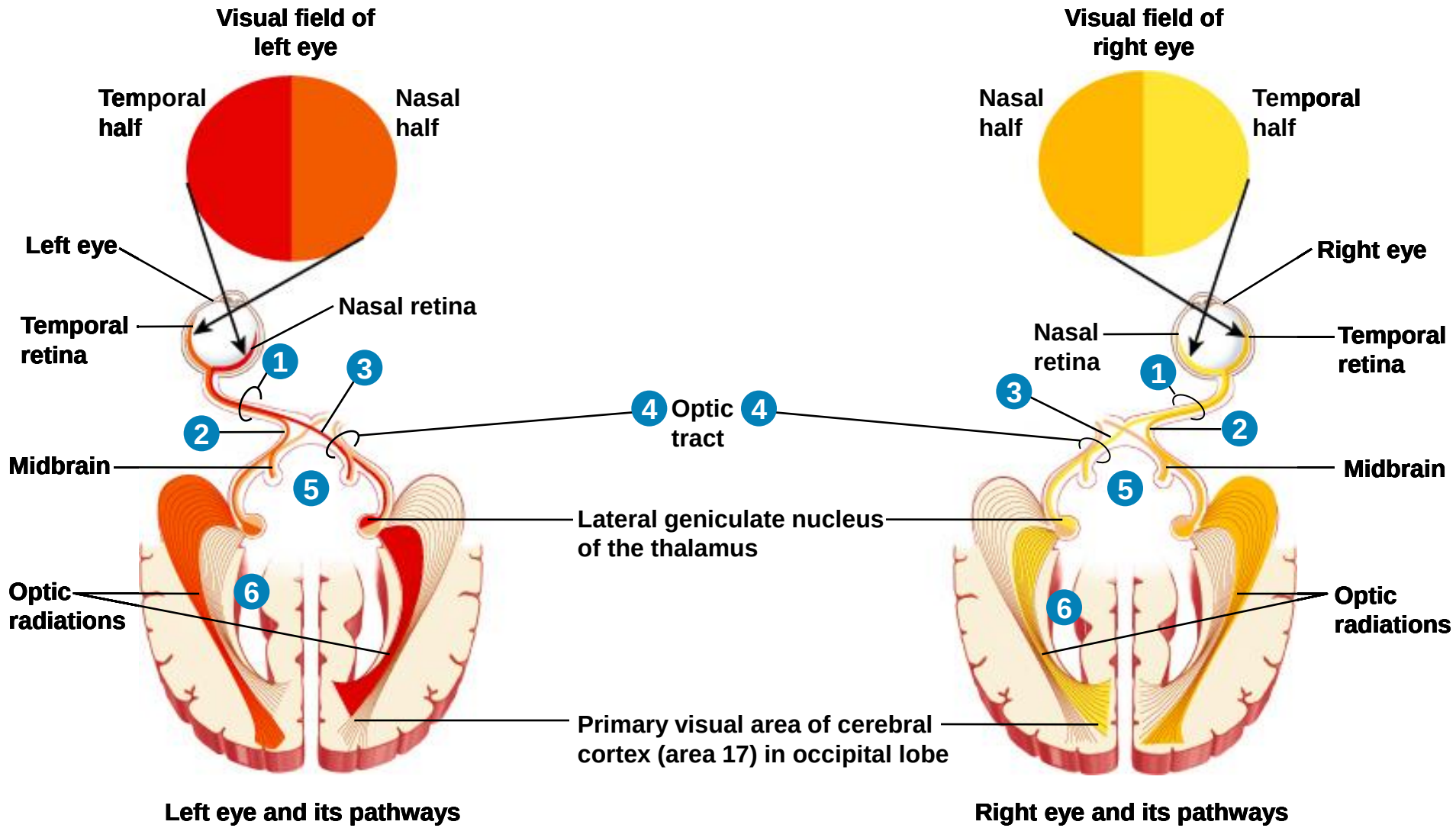

Left eye and its pathways

Right eye and its pathways

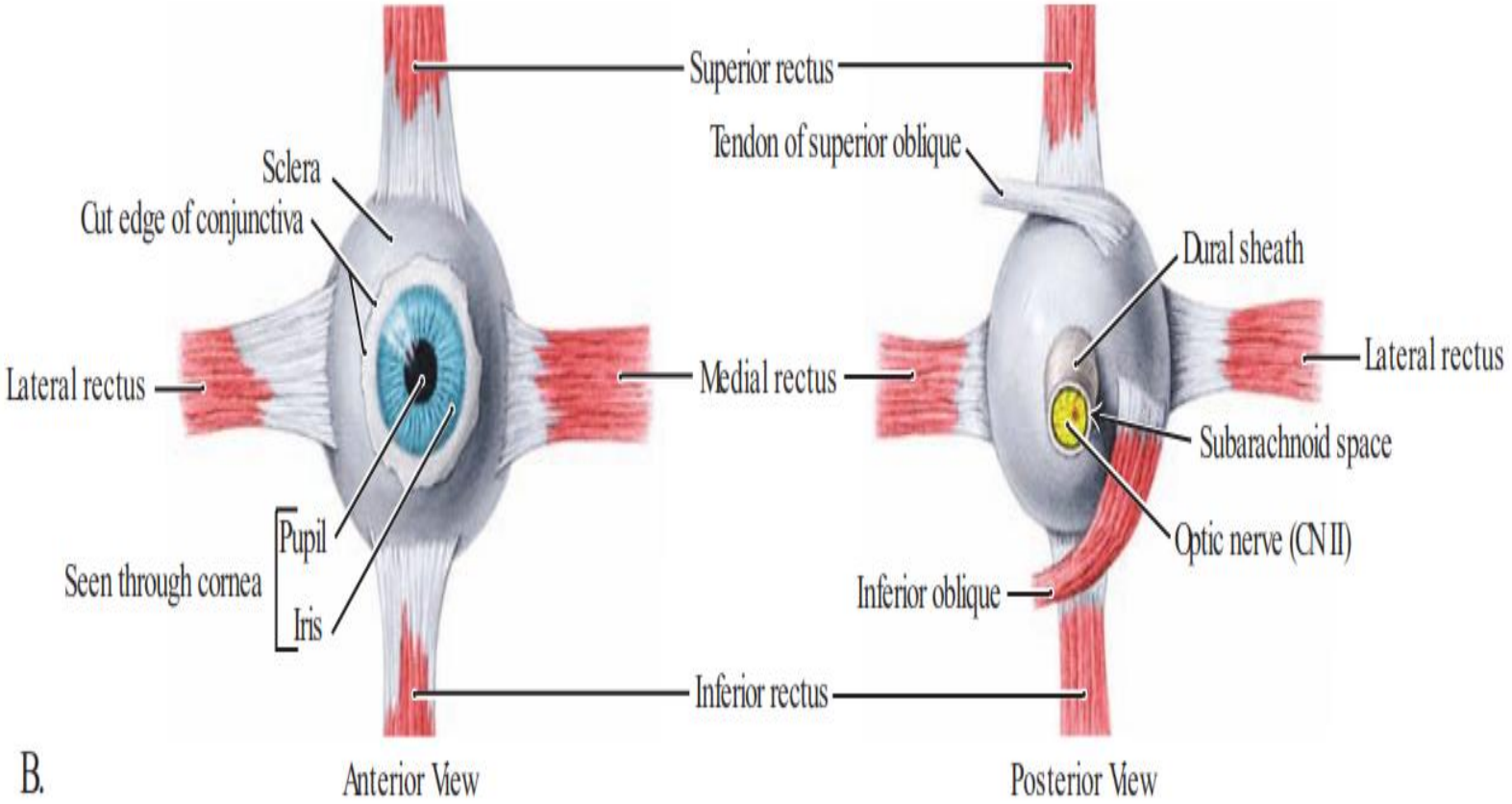
Superior rectus
Tendon of superior oblique
Sclera
Cut edge of conjunctiva
Dural sheath
Lateral rectus
Medial rectus
Lateral rectus
Subarachnoid space
Pupil
Seen through cornea
Iris
Optic nerve (CN II)
Inferior oblique
Inferior rectus
B.
Anterior View
Posterior View

TABLE 11.2 Muscles of the Eyeball and Eyelids

Muscle	Origin	Insertion	Nerve Supply	Action
Extrinsic Muscles of Eyeball (Striated Skeletal Muscle)				
Superior rectus	Tendinous ring on posterior wall of orbital cavity	Superior surface of eyeball just posterior to corneoscleral junction	Oculomotor nerve (3rd cranial nerve)	Raises cornea upward and medially
Inferior rectus	Tendinous ring on posterior wall of orbital cavity	Inferior surface of eyeball just posterior to corneoscleral junction	Oculomotor nerve (3rd cranial nerve)	Depresses cornea downward and medially
Medial rectus	Tendinous ring on posterior wall of orbital cavity	Medial surface of eyeball just posterior to corneoscleral junction	Oculomotor nerve (3rd cranial nerve)	Rotates eyeball so that cornea looks medially
Lateral rectus	Tendinous ring on posterior wall of orbital cavity	Lateral surface of eyeball just posterior to corneoscleral junction	Abducent nerve (6th cranial nerve)	Rotates eyeball so that cornea looks laterally
Superior oblique	Posterior wall of orbital cavity	Passes through pulley and is attached to superior surface of eyeball beneath superior rectus	Trochlear nerve (4th cranial nerve)	Rotates eyeball so that cornea looks downward and laterally
Inferior oblique	Floor of orbital cavity	Lateral surface of eyeball deep to lateral rectus	Oculomotor nerve (3rd cranial nerve)	Rotates eyeball so that cornea looks upward and laterally

THANK YOU

THE EAR

PREPARED BY:
Dr. REYADH AL-RASHIDI
SCHOOL OF PHARMACY
MANAGEMENT & SCIENCE UNIVERISTY

Anatomy of the Ear

- Three main regions:
  - External (outer) ear- auricle or pinna, external auditory canal, and tympanic membrane.

    Ceruminous glands-
  - Middle ear- auditory ossicles: malleus, incus and stapes.

    Auditory (eustachian) tube.
  - Internal (inner) ear- Labyrinth: bony and membranous. Bony labyrinth- perilymph and membranous labyrinth- endolymph. Oval window and round window- membranous regions.

Anatomy of the Ear

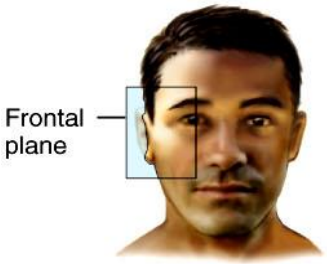

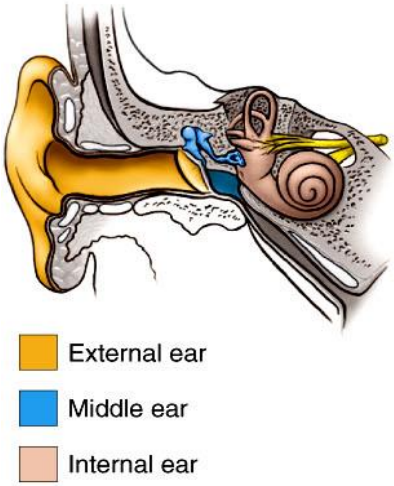

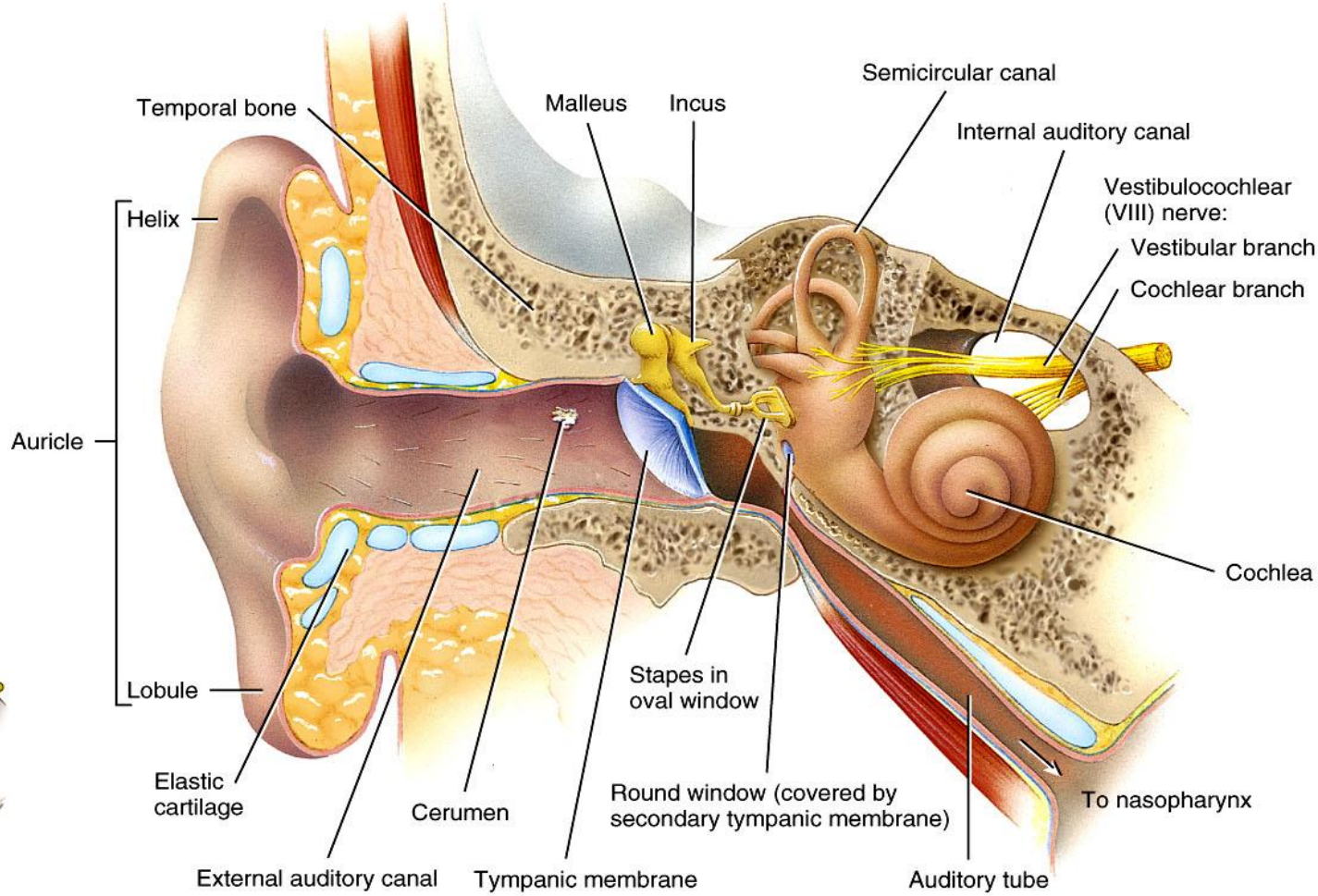

Frontal section through the right side of the skull showing the three principal regions of the ear

The Middle Ear and the Auditory Ossicles

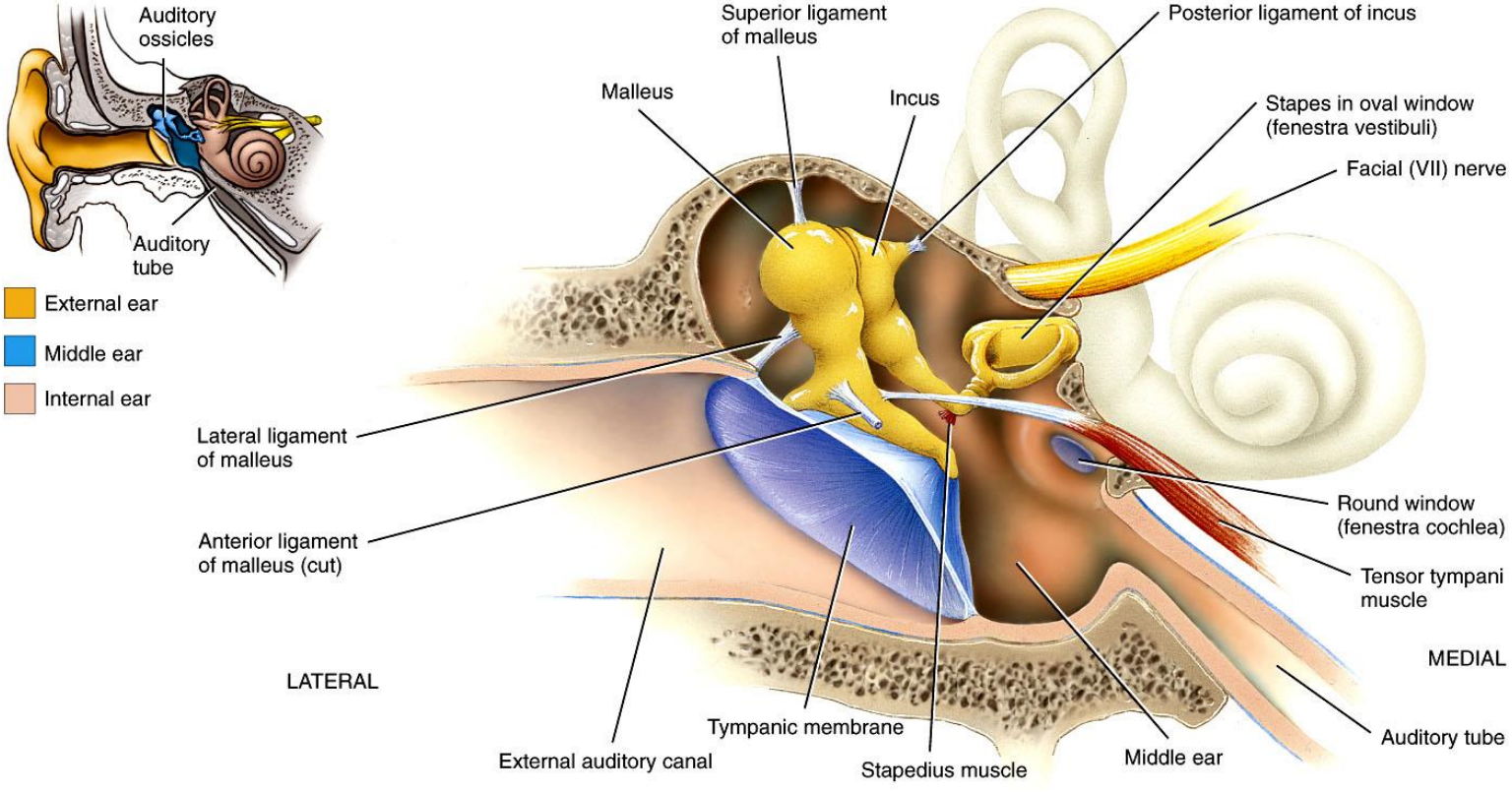

(a) Frontal section showing location of auditory ossicles

The Internal Ear

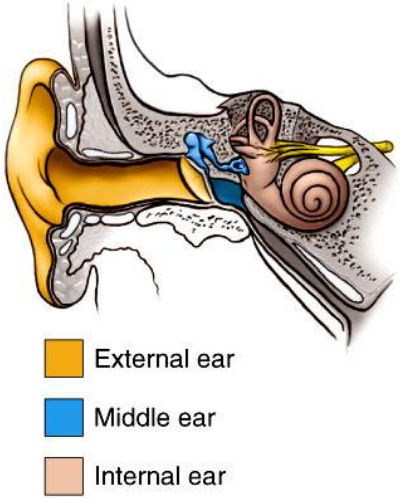

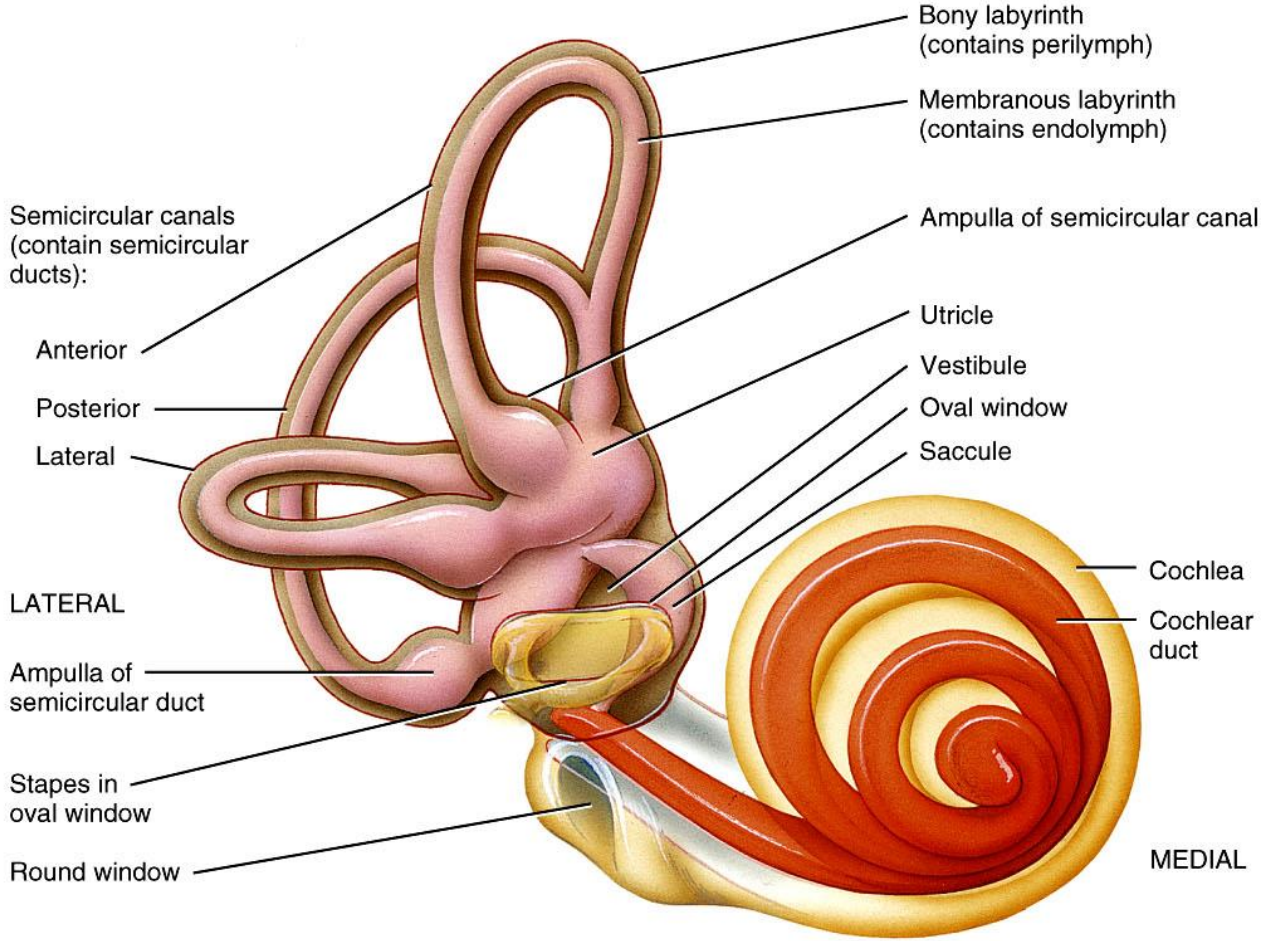

(a) Components of the right internal ear

The Internal Ear

- Three parts: the semicircular canals, the vestibule (both contain receptors for equilibrium) and the cochlea (contains receptors for hearing).
- Semicircular canals: anterior, posterior and lateral.

  Ampulla-
- Vestibule consists of two sacs: utricle and saccule.

Semicircular Canals, Vestibule and Cochlea

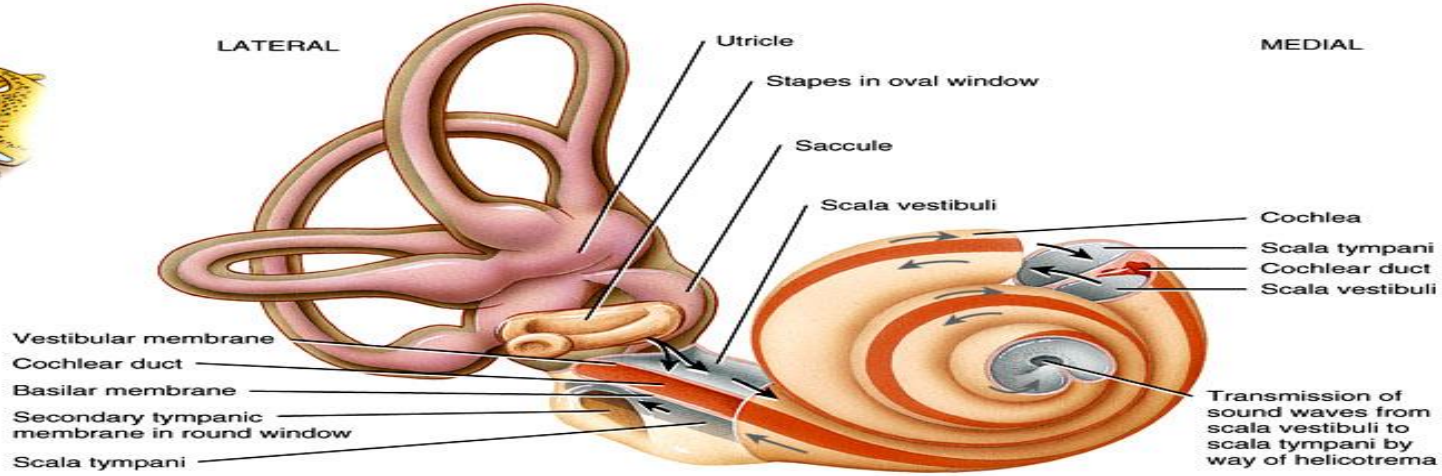

(a) Sections through the cochlea

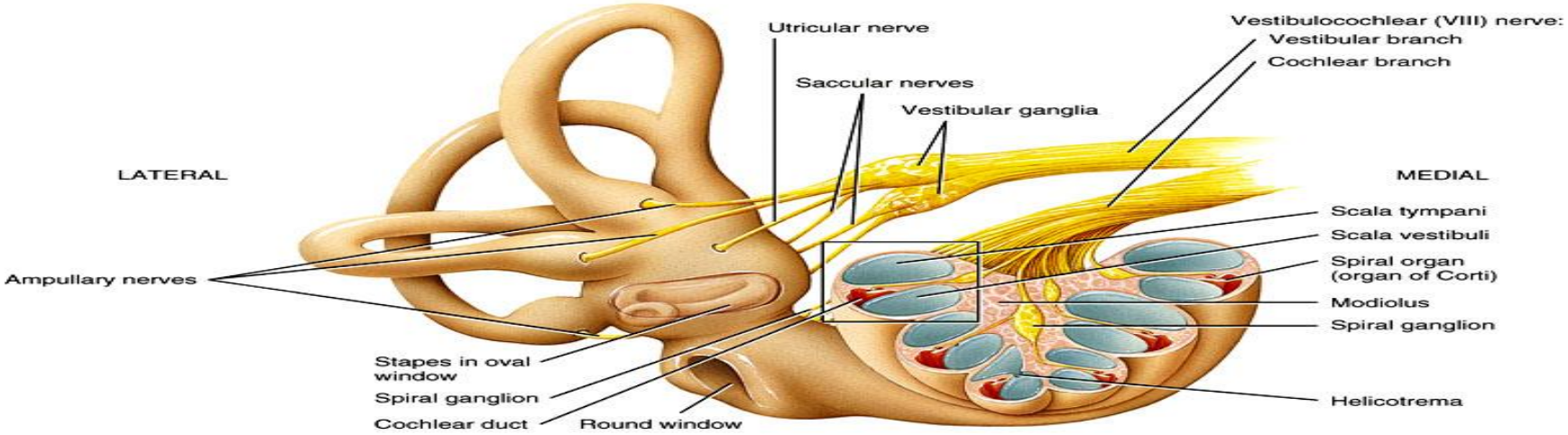

(b) Components of the vestibulocochlear nerve (cranial nerve VIII)

Cochlea

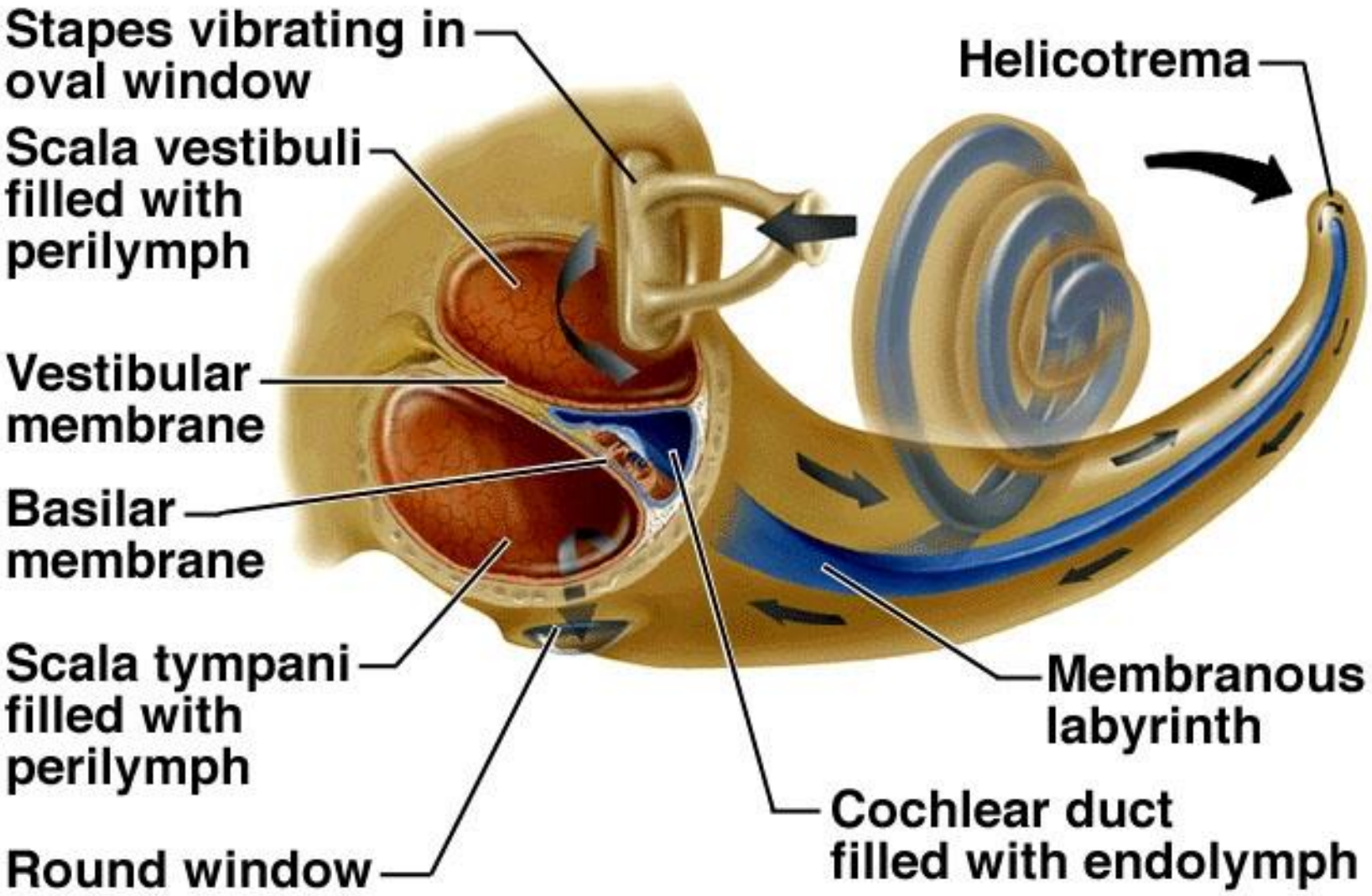
Stapes vibrating in oval window
Scala vestibuli filled with perilymph
Vestibular membrane
Basilar membrane
Scala tympani filled with perilymph
Round window
Helicotrema
Membranous labyrinth
Cochlear duct filled with endolymph

Cochlea—Cross Section

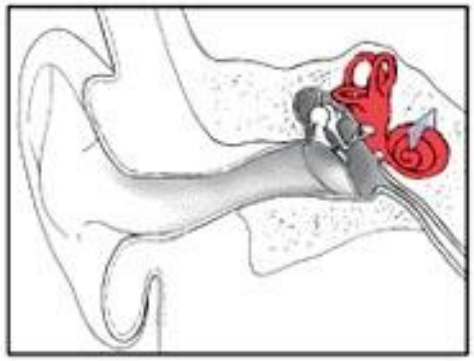

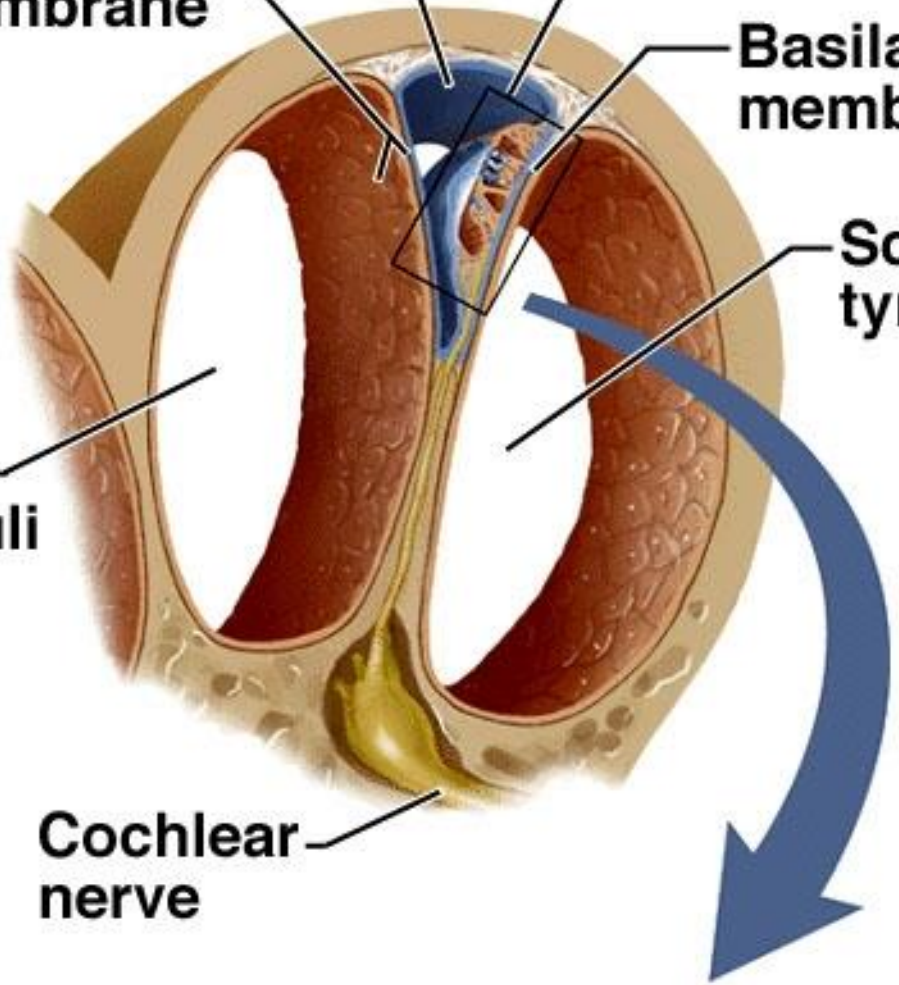

Organ of Corti

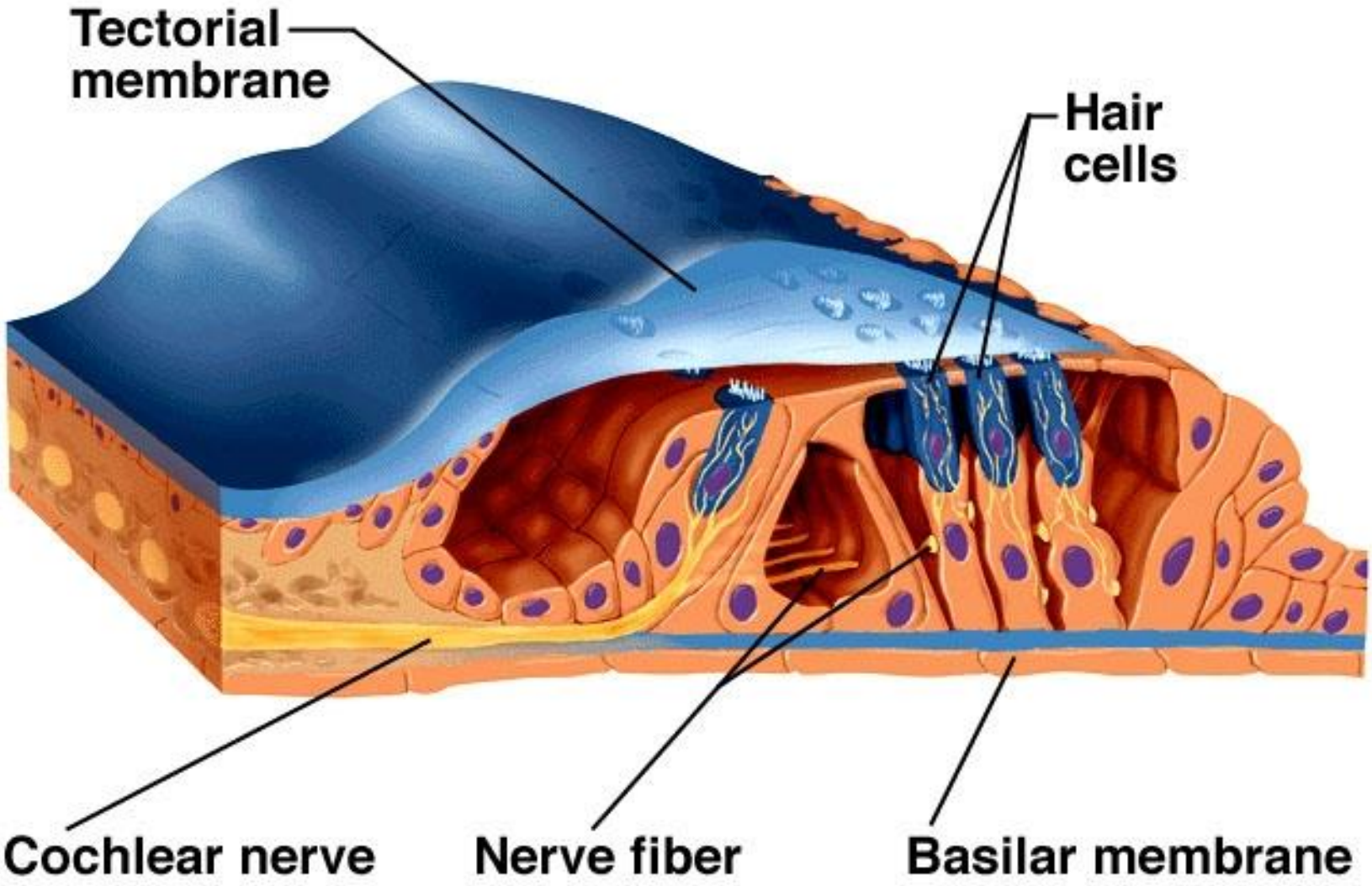

Cochlea

- Snail-shaped.
- Section through the cochlea shows three channels: cochlear duct, scala vestibuli and scala tympani.
- Vestibular membrane
- Basilar membrane
- Spiral organ or Organ of Corti- hair cells.

Physiology of Hearing

- Audible sound range: 20-20,000 Hz.
- Sound waves→ auricle→ external auditory canal→ tympanic membrane→ malleus→ incus→ stapes→ cochlea → hair cells (receptors) → action potential in cochlear branch of the vestibulocochlear nerve → Brainstem → Thalamus → The primary auditory area of cerebral cortex (temporal lobe)

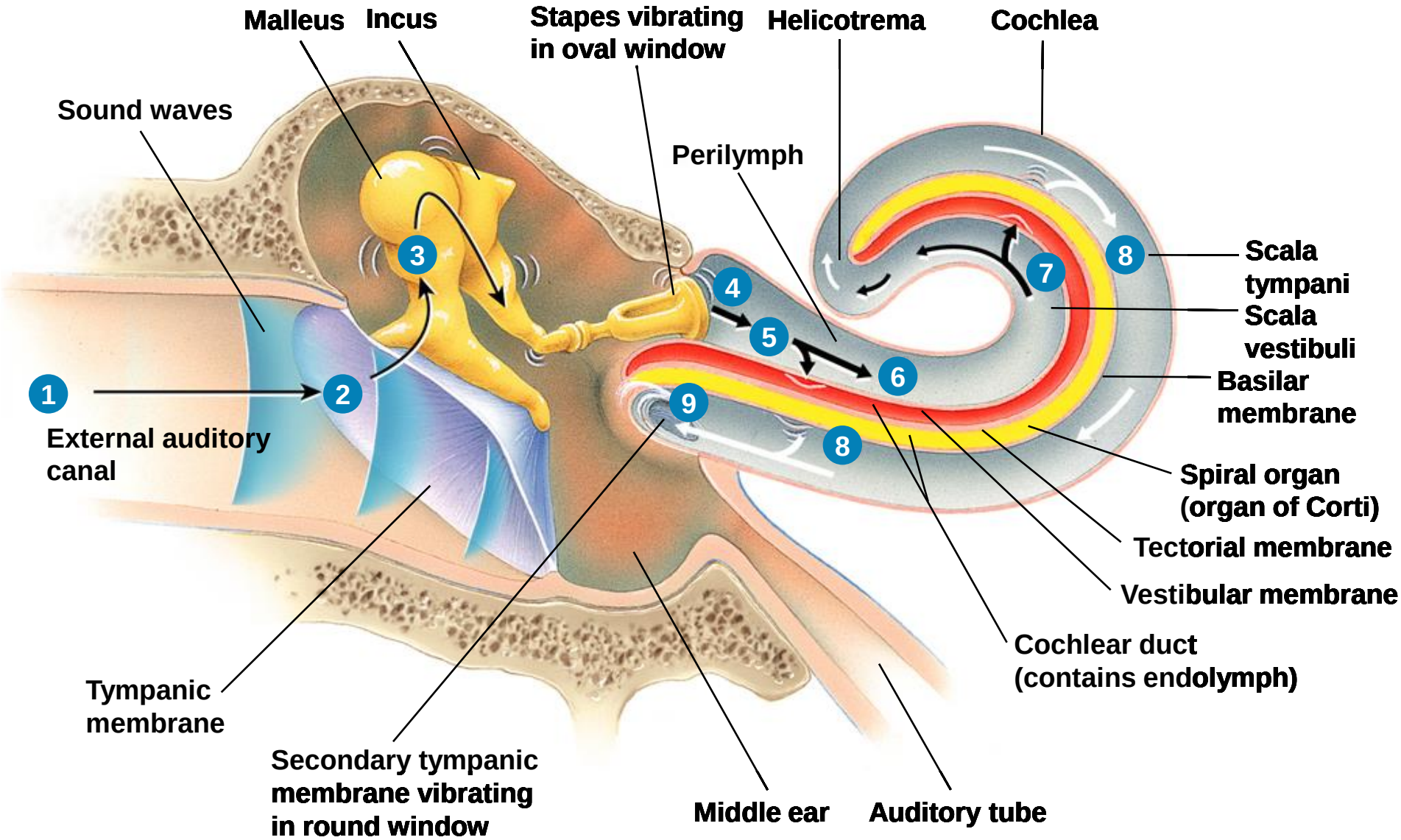
Malleus
Incus
Stapes vibrating in oval window
Helicotrema
Cochlea
Sound waves
Perilymph
Scala tympani
Scala vestibuli
Basilar membrane
Spiral organ (organ of Corti)
Tectorial membrane
Vestibular membrane
Cochlear duct (contains endolymph)
External auditory canal
Tympanic membrane
Secondary tympanic membrane vibrating in round window
Middle ear
Auditory tube
1
2
3
4
5
6
7
8
8
9

Physiology of Equilibrium

- Two types of equilibrium:

  Static- maintenance of the body position relative to the force of gravity.

  Dynamic- maintenance of body position (mainly head) in response to rotational acceleration and deceleration.
- Receptors for equilibrium are hair cells in the utricle, saccule and semicircular canals and are collectively called vestibular apparatus.

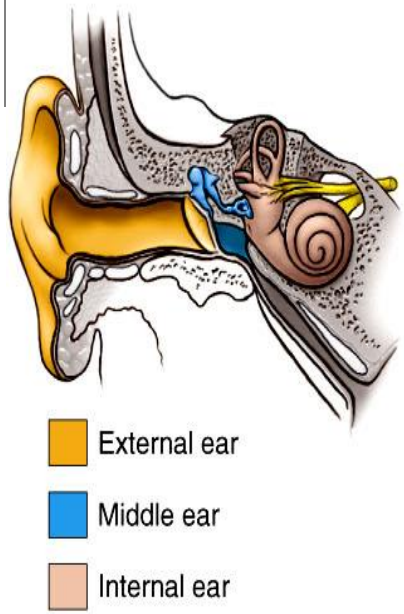

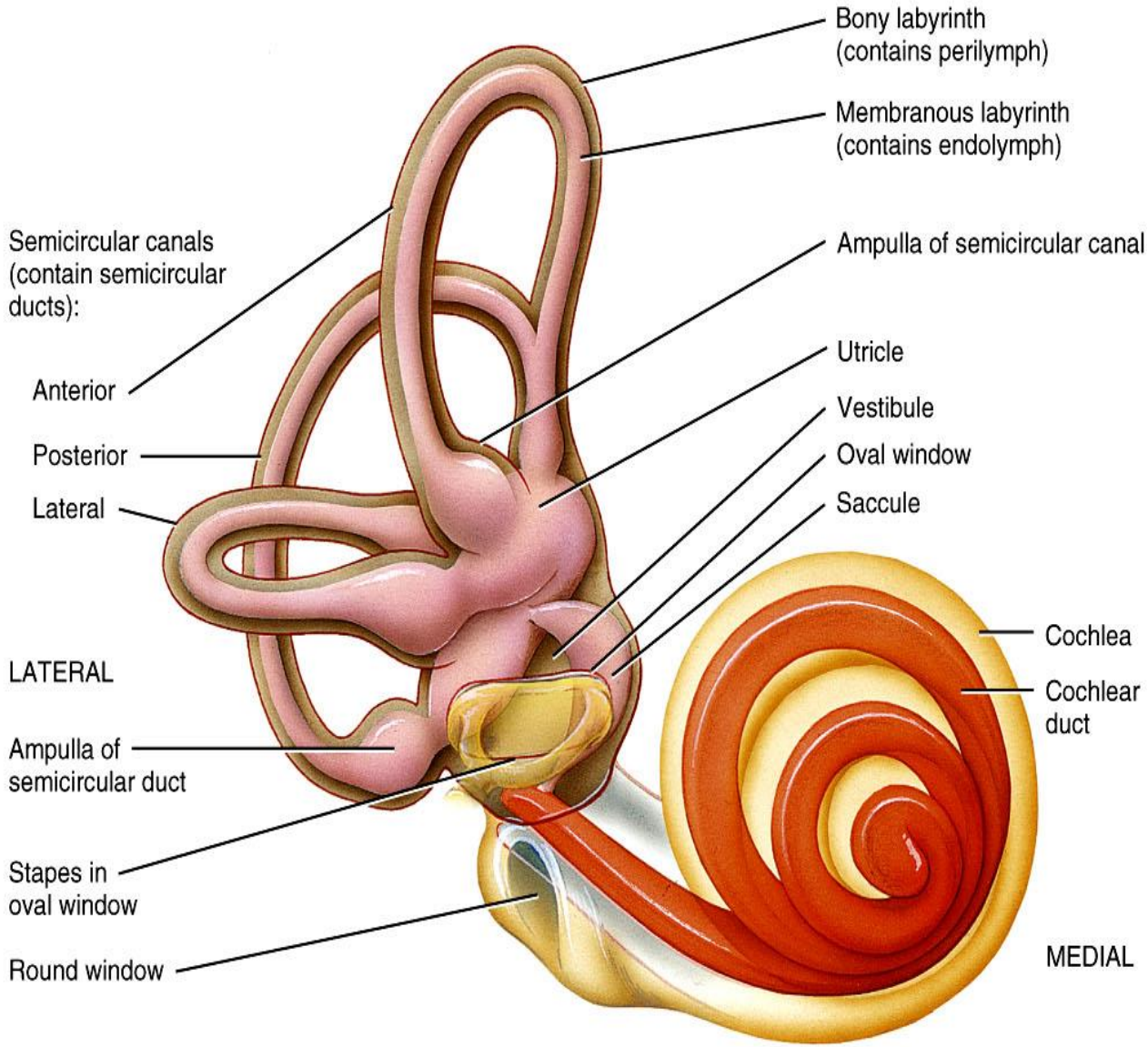

(a) Components of the right internal ear

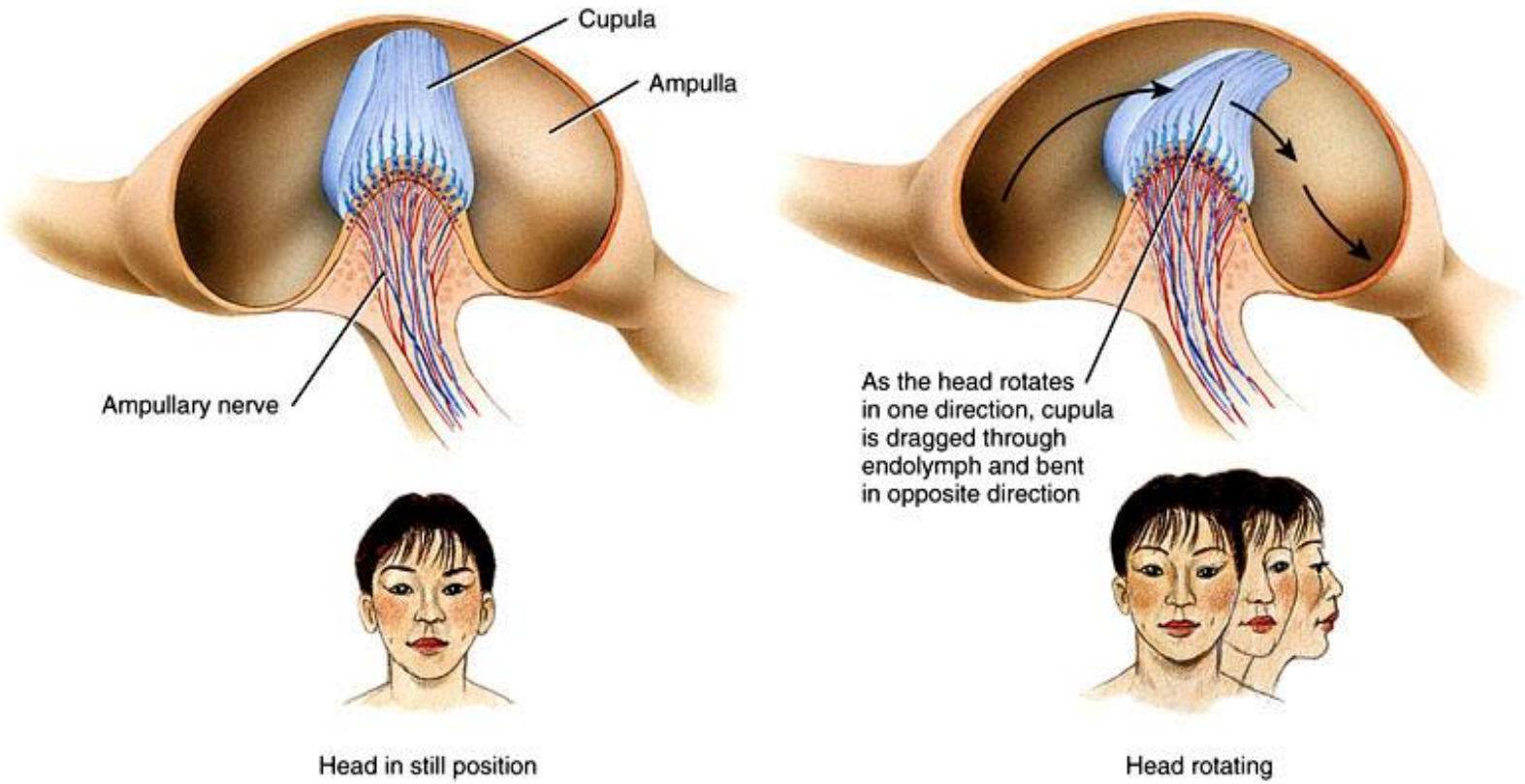

(b) Position of a cupula with the head in the still position (left) and when the head rotates (right)

Location and Structure of the Semicircular Ducts

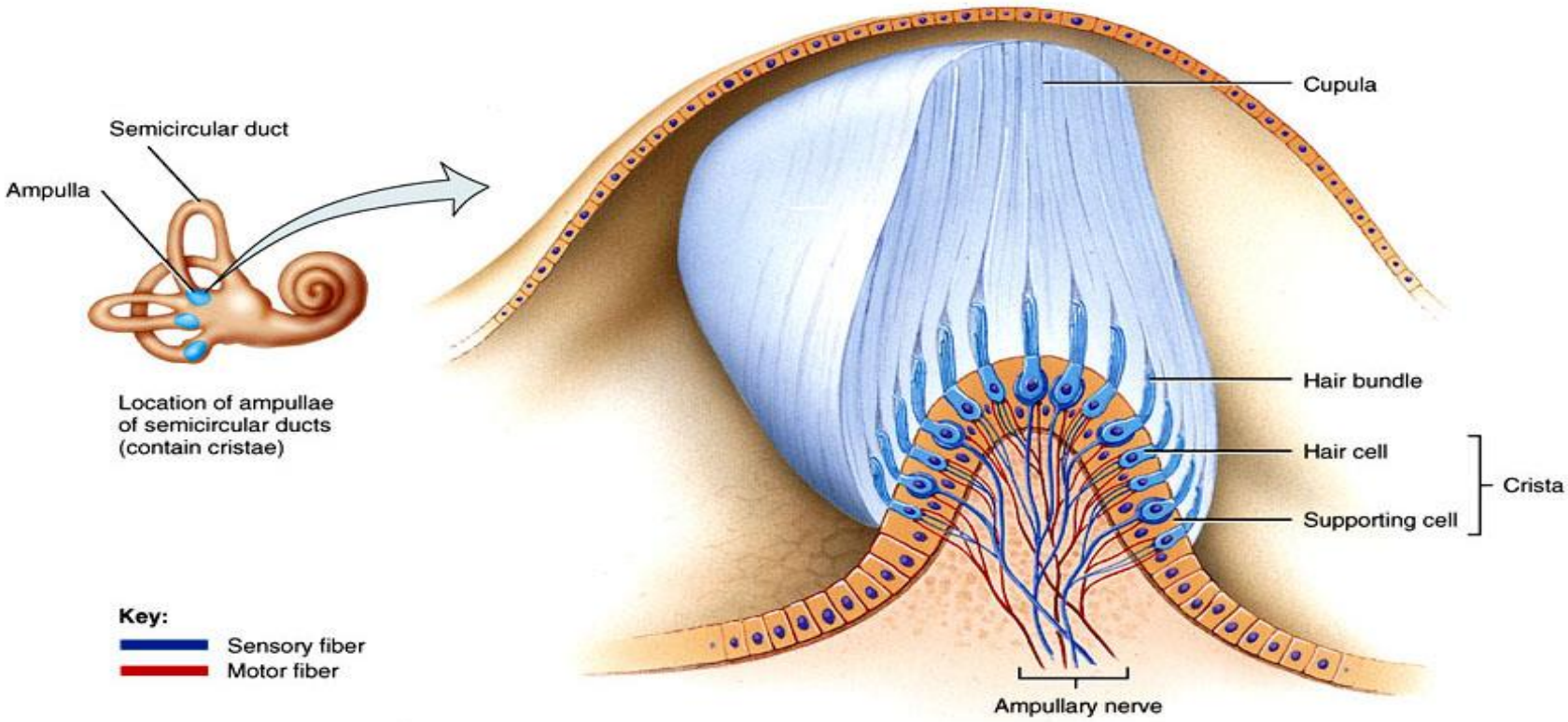

(a) Details of a crista

Semicircular Ducts

- Crista, a small elevation in the ampulla contain hair cells and supporting cells.
- Cupula, a mass of gelatinous material covering the crista.
- Head movement→ semicircular ducts and hair cells move with it→ hair bundles bend→ receptor potential→ nerve impulses→ vestibular branch of the vestibulocochlear nerve.

THANK YOU

The Nose and Pharynx

PREPARED BY:

Dr. REYADH AL-RASHIDI

Nasal Cavity

The nasal cavity extends from the nostrils in front to the **posterior nasal apertures** or **choanae** behind, where the nose opens into the nasopharynx. The **nasal vestibule** is the area of the nasal cavity lying just inside the nostril (Fig. 11.93). The nasal cavity is divided into right and left halves by the **nasal septum** (Fig. 11.92). The septum is made up of the **septal cartilage,** the **vertical plate of the ethmoid,** and the **vomer.**

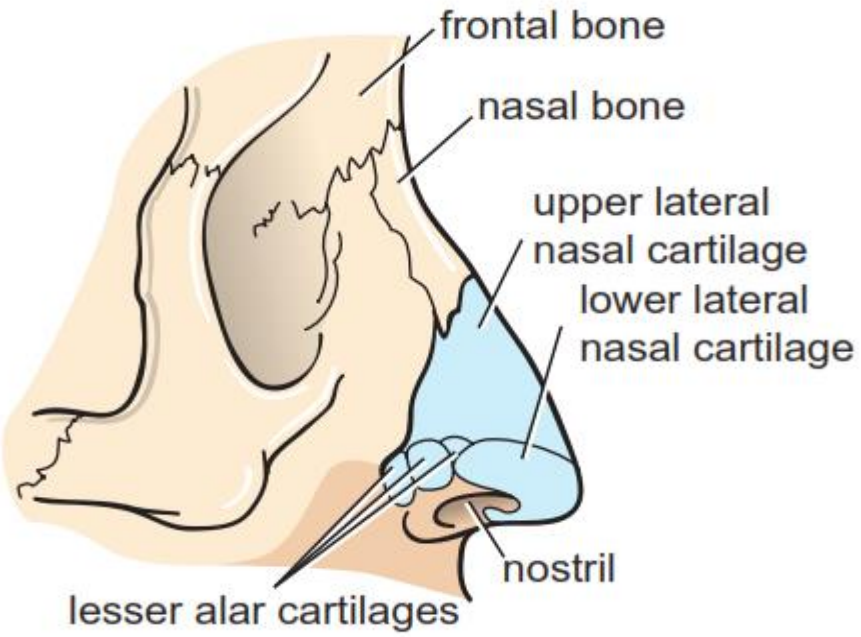

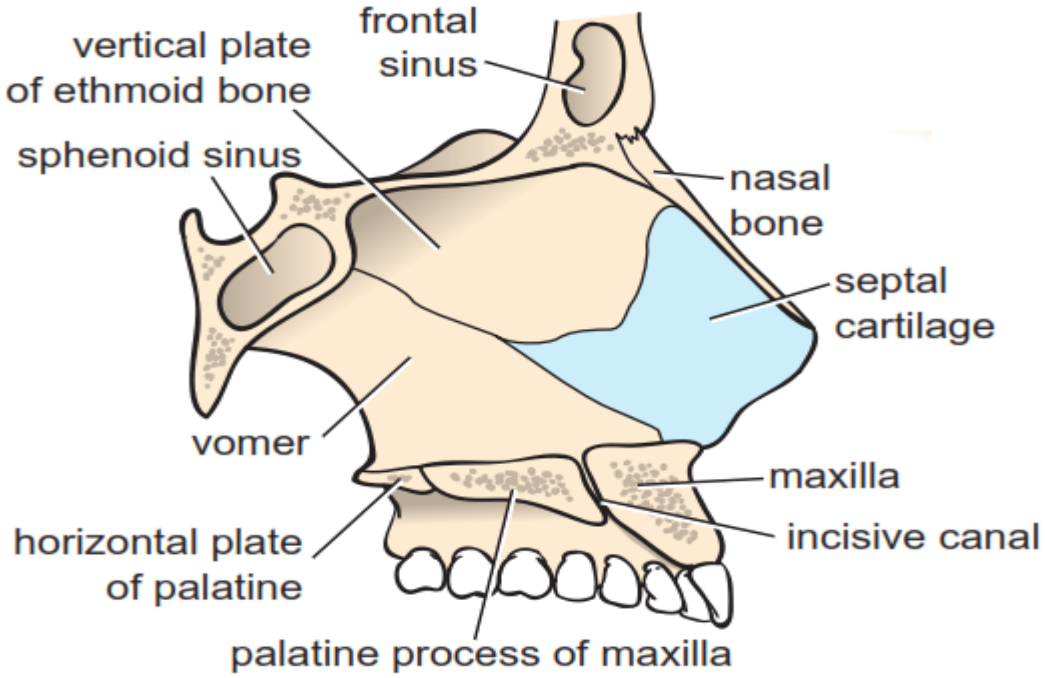

Walls of the Nasal Cavity

Each half of the nasal cavity has a floor, a roof, a lateral wall, and a medial or septal wall.

Floor

The palatine process of the maxilla and the horizontal plate of the palatine bone (Fig. 11.92)

Roof

The roof is narrow and is formed anteriorly beneath the bridge of the nose by the nasal and frontal bones, in the middle by the cribriform plate of the ethmoid, located beneath the anterior cranial fossa, and posteriorly by the downward sloping body of the sphenoid (Fig. 11.93).

Medial Wall

The medial wall is formed by the nasal septum. The upper part is formed by the vertical plate of the ethmoid and the vomer (Fig. 11.92). The anterior part is formed by the septal cartilage. The septum rarely lies in the midline, thus increasing the size of one half of the nasal cavity and decreasing the size of the other.

Lateral Wall

The lateral wall has three projections of bone called the **superior, middle,** and **inferior nasal conchae** (Fig. 11.93). The space below each concha is called a **meatus.**

Sphenoethmoidal Recess The sphenoethmoidal recess is a small area above the superior concha. It receives the opening of the **sphenoid air sinus** (Fig. 11.93).

Superior Meatus The superior meatus lies below the superior concha (Fig. 11.93). It receives the openings of the **posterior ethmoid sinuses.**

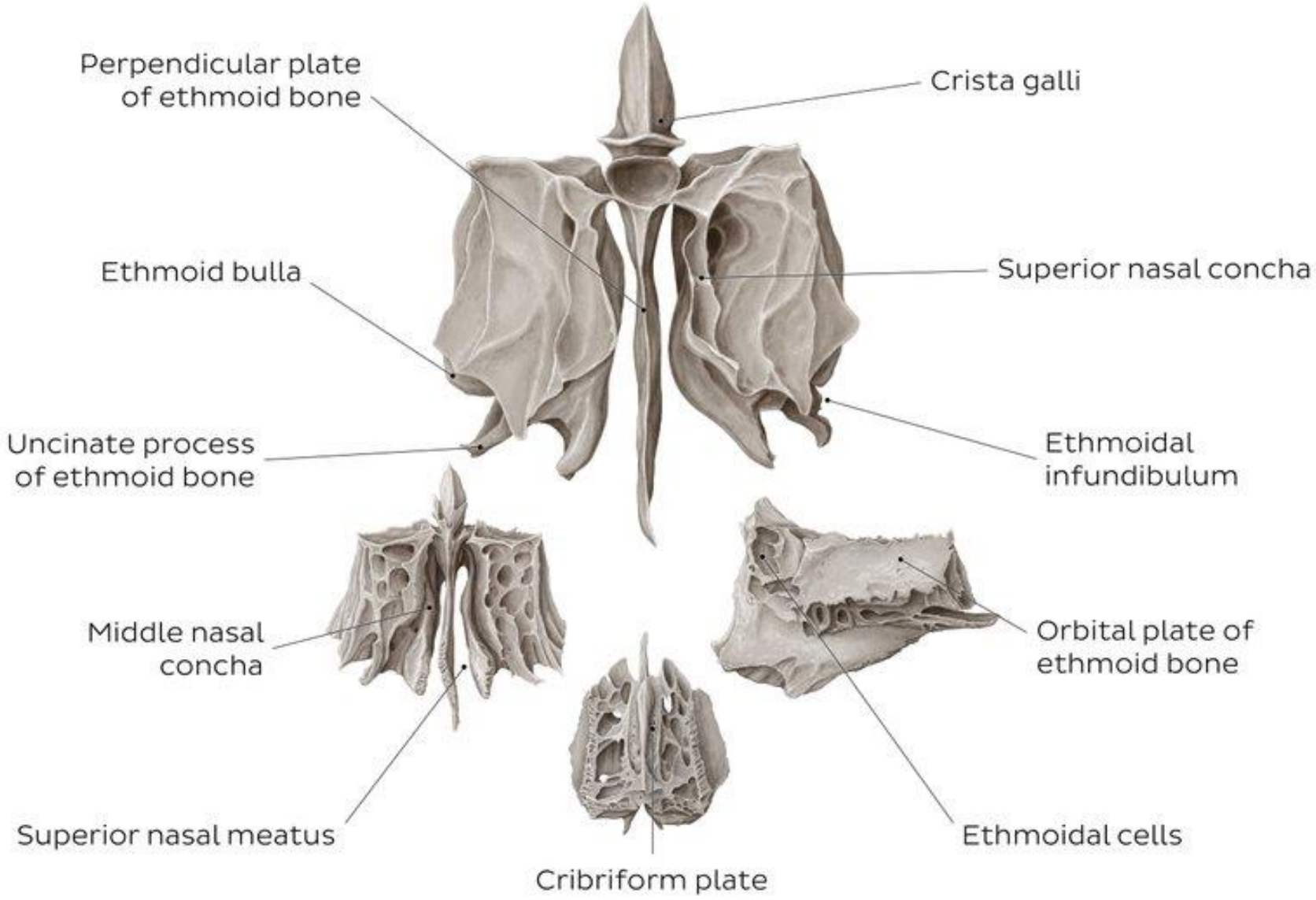
Perpendicular plate of ethmoid bone
Crista galli
Ethmoid bulla
Superior nasal concha
Uncinate process of ethmoid bone
Ethmoidal infundibulum
Middle nasal concha
Orbital plate of ethmoid bone
Superior nasal meatus
Ethmoidal cells
Cribriform plate

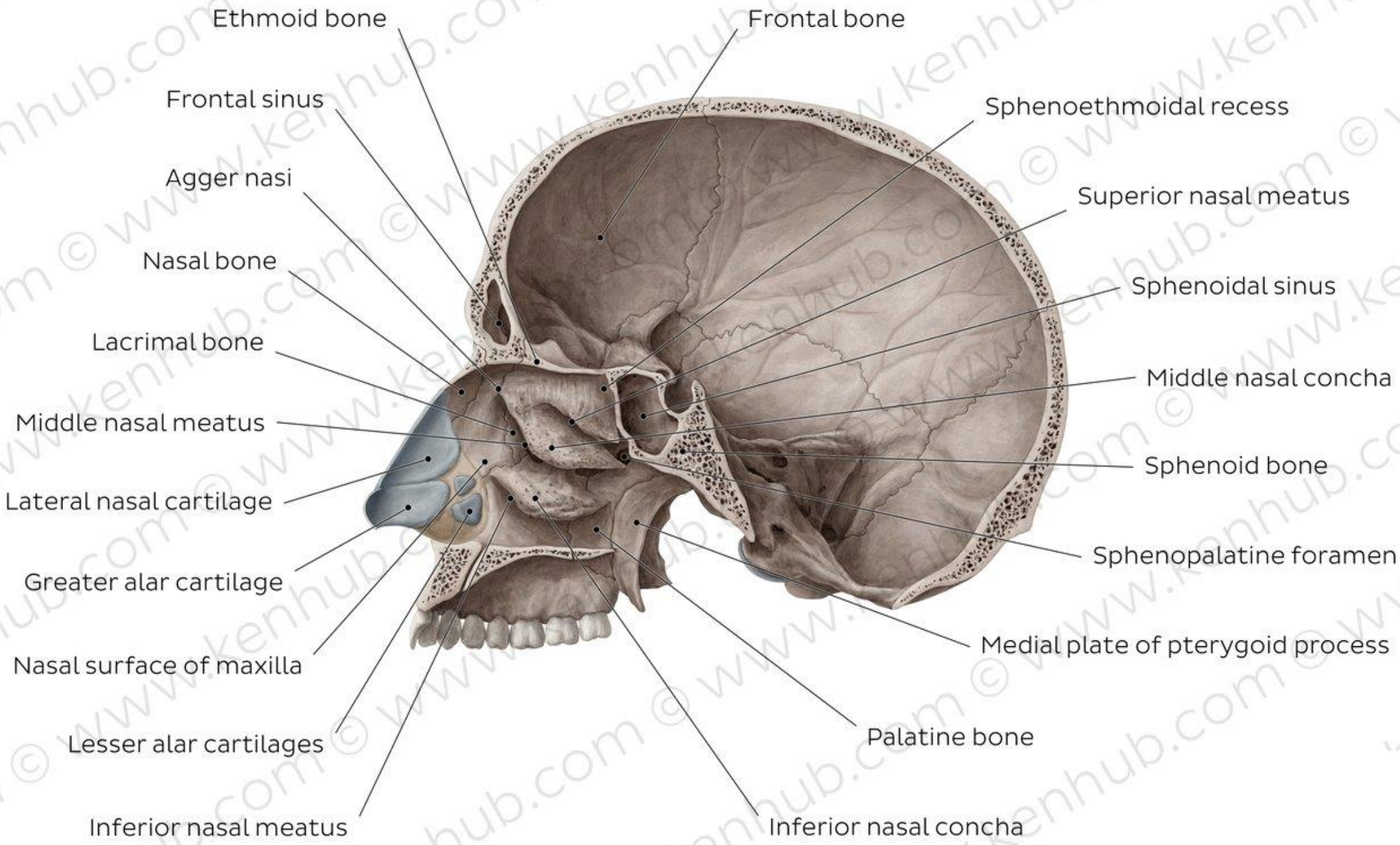
Ethmoid bone
Frontal bone
Frontal sinus
Sphenoethmoidal recess
Agger nasi
Superior nasal meatus
Nasal bone
Sphenoidal sinus
Lacrimal bone
Middle nasal concha
Middle nasal meatus
Sphenoid bone
Lateral nasal cartilage
Sphenopalatine foramen
Greater alar cartilage
Medial plate of pterygoid process
Nasal surface of maxilla
Lesser alar cartilages
Palatine bone
Inferior nasal meatus
Inferior nasal concha

Middle Meatus The middle meatus lies below the middle concha. It has a rounded swelling called the **bulla ethmoidalis** that is formed by the **middle ethmoidal air sinuses,** which open on its upper border. A curved opening, the **hiatus semilunaris,** lies just below the bulla (Fig. 11.93). The anterior end of the hiatus leads into a funnel-shaped channel called the **infundibulum,** which is continuous with the **frontal sinus.** The **maxillary sinus** opens into the middle meatus through the **hiatus semilunaris.**

Inferior Meatus The inferior meatus lies below the inferior concha and receives the opening of the lower end of the **nasolacrimal duct,** which is guarded by a fold of mucous membrane (Fig. 11.93).

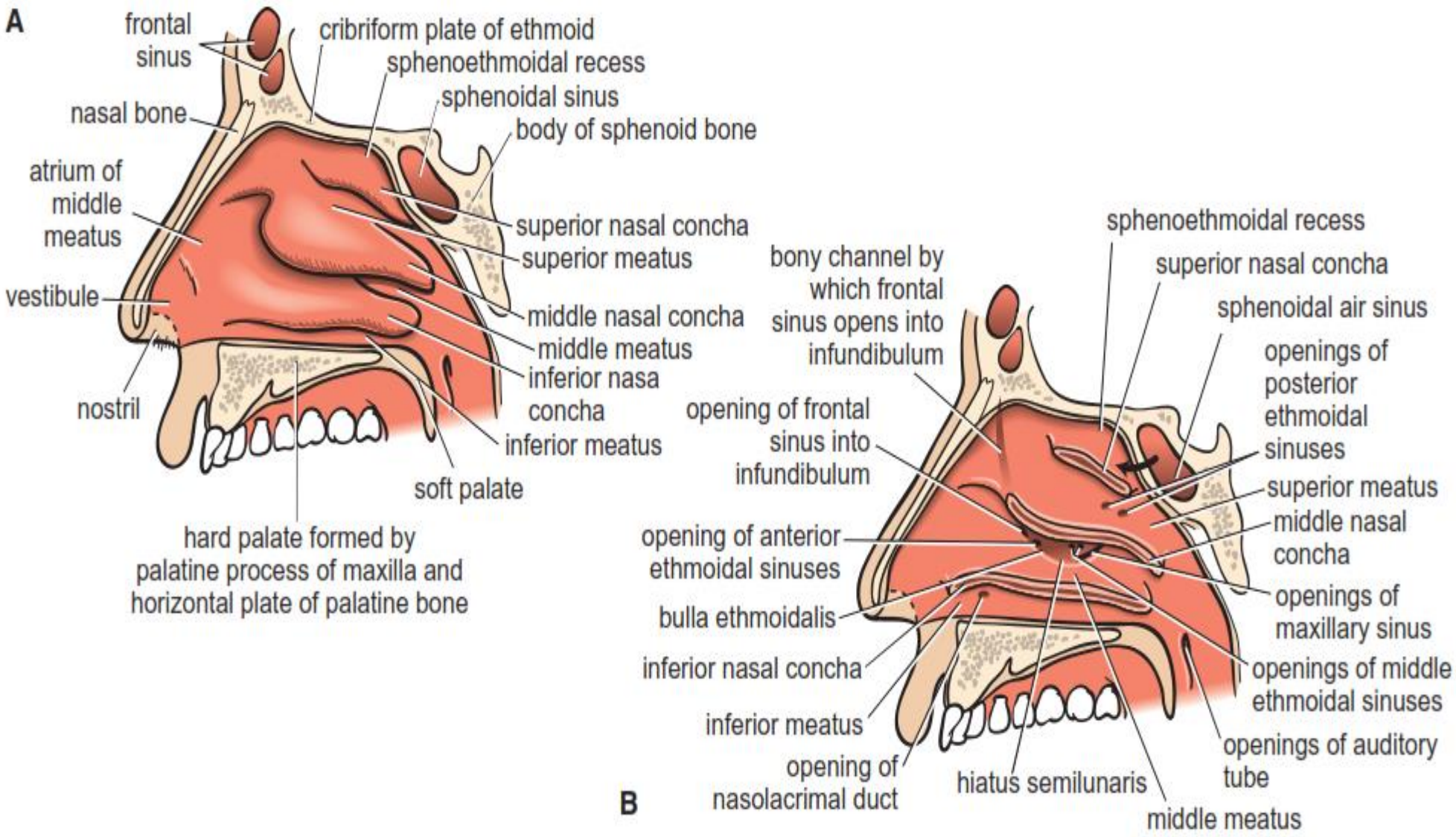

FIGURE 11.93 **A.** Lateral wall of the right nasal cavity. **B.** Lateral wall of the right nasal cavity; the superior, middle, and inferior conchae have been partially removed to show openings of the paranasal sinuses and the nasolacrimal duct into the meati.

Nerve Supply of the Nasal Cavity

The olfactory nerves from the olfactory mucous membrane ascend through the cribriform plate of the ethmoid bone to the olfactory bulbs (Fig. 11.94). The nerves of ordinary sensation are branches of the ophthalmic division (V1) and the maxillary division (V2) of the trigeminal nerve (Fig. 11.94).

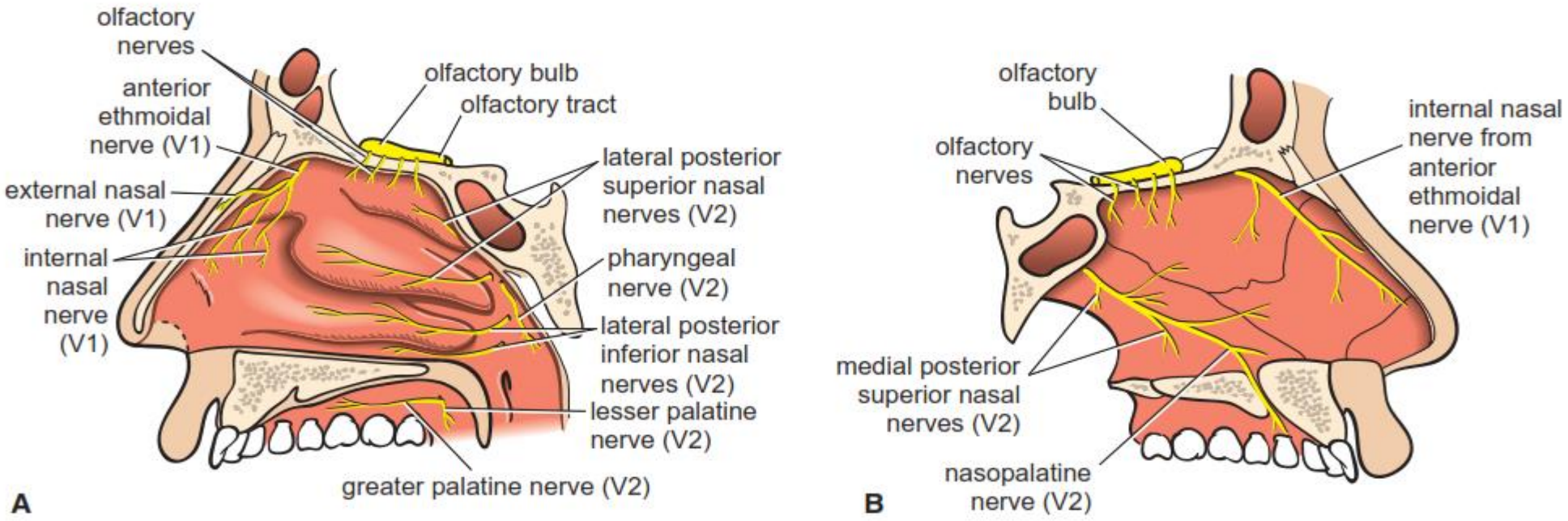

FIGURE 11.94 **A.** Lateral wall of nasal cavity showing sensory innervation of mucous membrane. **B.** Nasal septum showing sensory innervation of mucous membrane.

Blood Supply to the Nasal Cavity

The arterial supply to the nasal cavity is from branches of the maxillary artery, one of the terminal branches of the external carotid artery. The most important branch is the sphenopalatine artery (Fig. 11.95). The sphenopalatine artery anastomoses with the septal branch of the superior labial branch of the facial artery in the region of the vestibule. The submucous venous plexus is drained by veins that accompany the arteries.

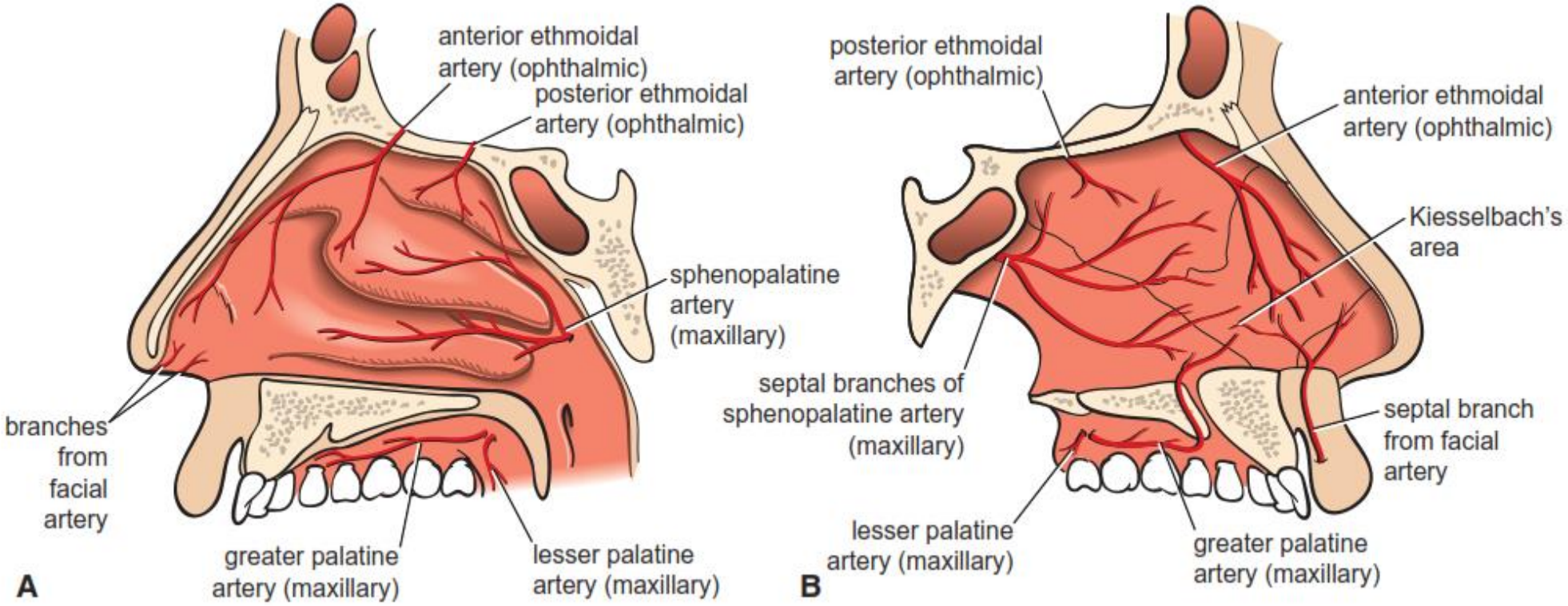

FIGURE 11.95 **A.** Lateral wall of nasal cavity showing the arterial supply of the mucous membrane. **B.** Nasal septum showing the arterial supply of the mucous membrane.

TABLE 11.11 Paranasal Sinuses and Their Site of Drainage into the Nose*

Sinus	Site of Drainage
Maxillary sinus	Middle meatus through hiatus semilunaris
Frontal sinuses	Middle meatus via infundibulum
Sphenoidal sinuses	Sphenoethmoidal recess
Ethmoidal sinuses	
Anterior group	Infundibulum and into middle meatus
Middle group	Middle meatus on or above bulla ethmoidalis
Posterior group	Superior meatus

Paranasal Sinuses

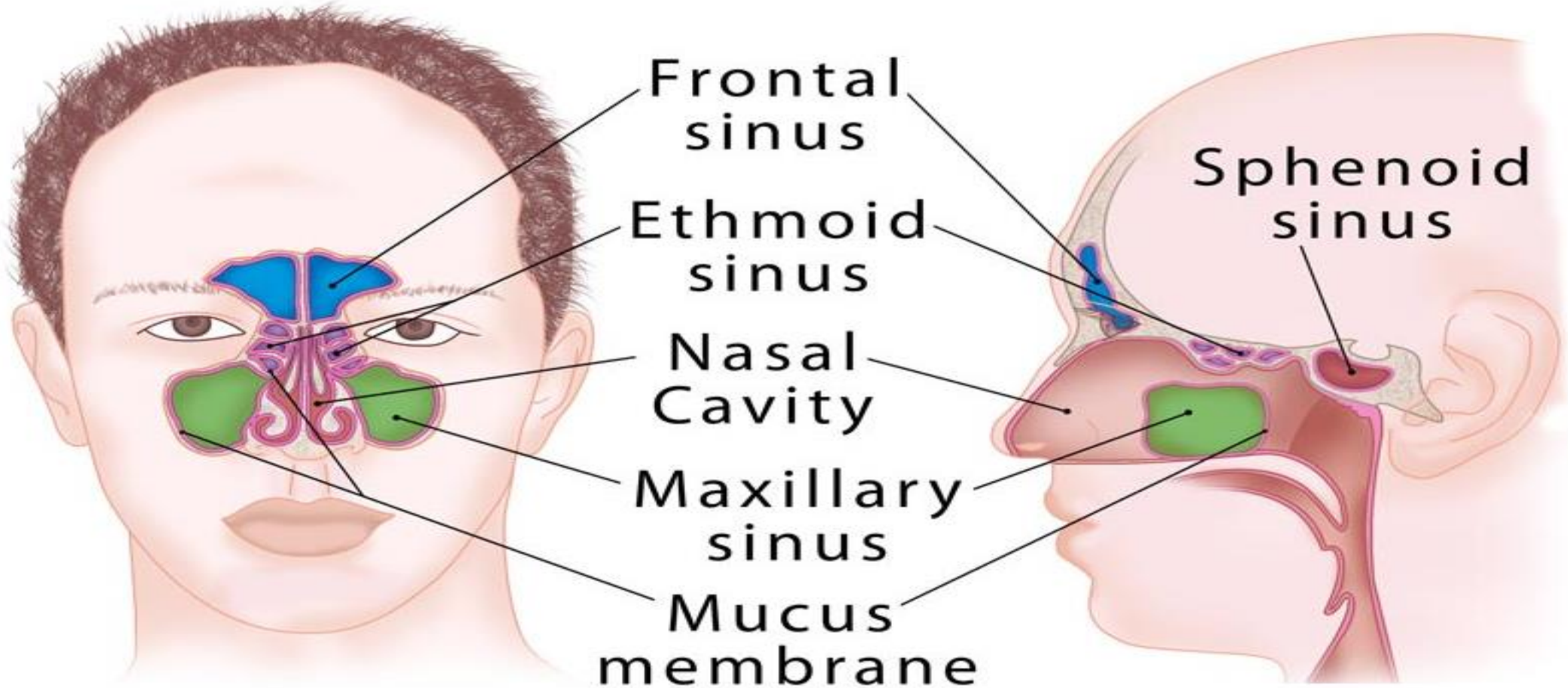

The Pharynx

The pharynx is situated behind the nasal cavities, the mouth, and the larynx (Fig. 11.87) and may be divided into **nasal, oral,** and **laryngeal parts.** The pharynx is funnel shaped, its upper, wider end lying under the skull and its lower, narrow end becoming continuous with the esophagus opposite the 6th cervical vertebra. The pharynx has a musculomembranous wall, which is deficient anteriorly. Here, it is replaced by the posterior openings into the nose (choanae), the opening into the mouth, and the inlet of the larynx. By means of the auditory tube, the mucous membrane is also continuous with that of the tympanic cavity.

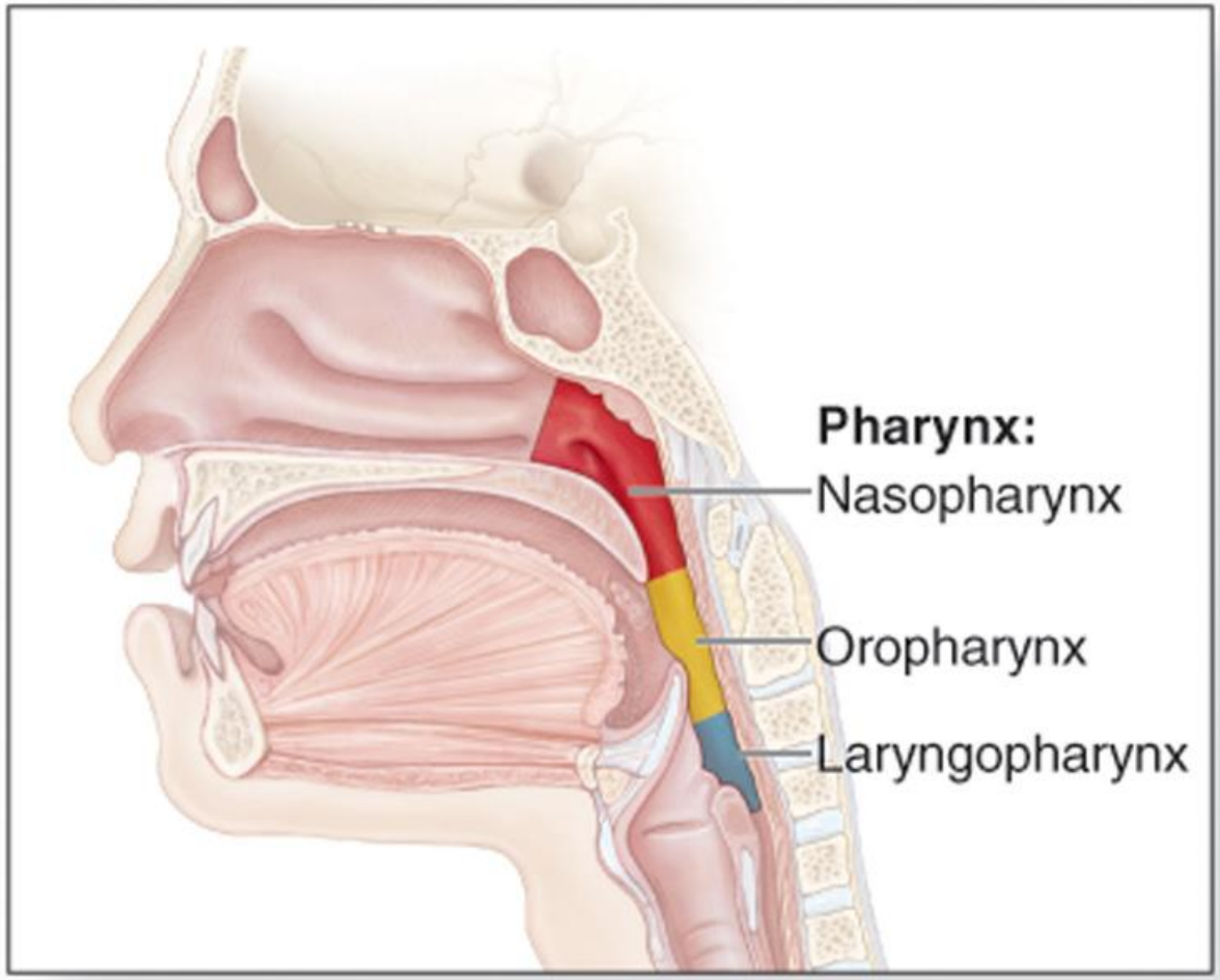

(b) Regions of pharynx

Interior of the Pharynx

The pharynx is divided into three parts: the nasal pharynx, the oral pharynx, and the laryngeal pharynx.

Nasal Pharynx

This lies above the soft palate and behind the nasal cavities (Fig. 11.87). In the submucosa of the roof is a collection of lymphoid tissue called the **pharyngeal tonsil** (Fig. 11.89). The pharyngeal isthmus is the opening in the floor between the soft palate and the posterior pharyngeal wall. On the lateral wall is the opening of the **auditory tube,** the elevated ridge of which is called the **tubal elevation** (Fig. 11.89).

The **pharyngeal recess** is a depression in the pharyngeal wall behind the tubal elevation. The **salpingopharyngeal fold** is a vertical fold of mucous membrane covering the salpingopharyngeus muscle.

Oral Pharynx

This lies behind the oral cavity (Fig. 11.87). The floor is formed by the posterior one third of the tongue and the interval between the tongue and epiglottis. In the midline is the **median glossoepiglottic fold** (Fig. 11.77), and on each side the **lateral glossoepiglottic fold.** The depression on each side of the median glossoepiglottic fold is called the **vallecula** (Fig. 11.77).

On the lateral wall on each side are the palatoglossal and the palatopharyngeal arches or folds and the palatine tonsils between them (Fig. 11.89). The palatoglossal arch is a fold of mucous membrane covering the palatoglossus muscle. The interval between the two palatoglossal arches is called the **oropharyngeal isthmus** and marks the boundary between the mouth and pharynx. The palatopharyngeal arch is a fold of mucous membrane covering the palatopharyngeus muscle. The recess between the palatoglossal and palatopharyngeal arches is occupied by the **palatine tonsil.**

Laryngeal Pharynx

This lies behind the opening into the larynx (Fig. 11.87). The lateral wall is formed by the thyroid cartilage and the thyrohyoid membrane. The **piriform fossa** is a depression in the mucous membrane on each side of the laryngeal inlet (Fig. 11.88).

Sensory Nerve Supply of the Pharyngeal Mucous Membrane

Nasal pharynx: The maxillary nerve (V2)
Oral pharynx: pharyngeal plexus
Laryngeal pharynx pharyngeal plexus

Blood Supply of the Pharynx

Ascending pharyngeal, tonsillar branches of facial arteries, and branches of maxillary and lingual arteries

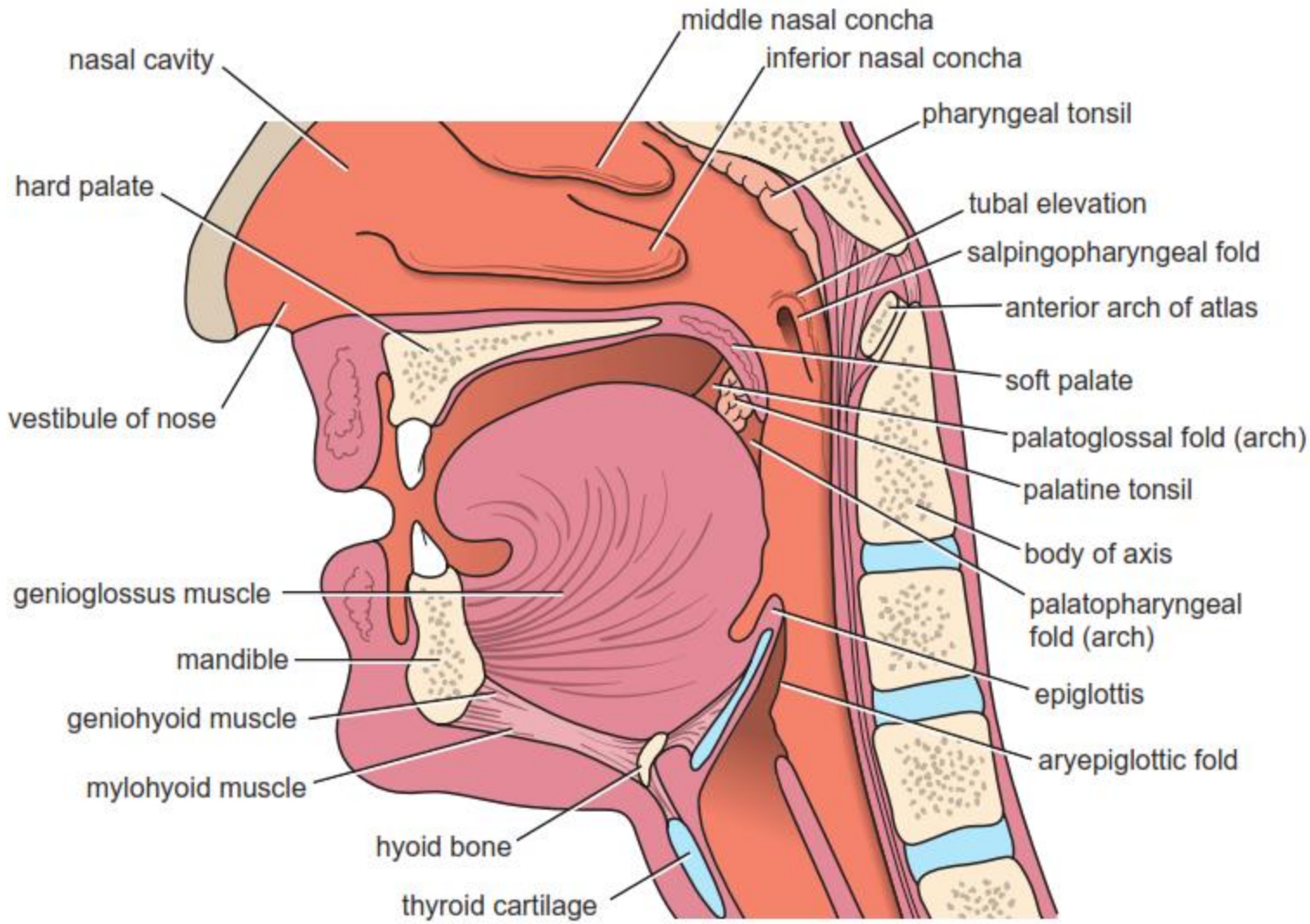

FIGURE 11.89 Sagittal section of the head and neck, showing the relations of the nasal cavity, mouth, pharynx, and larynx.

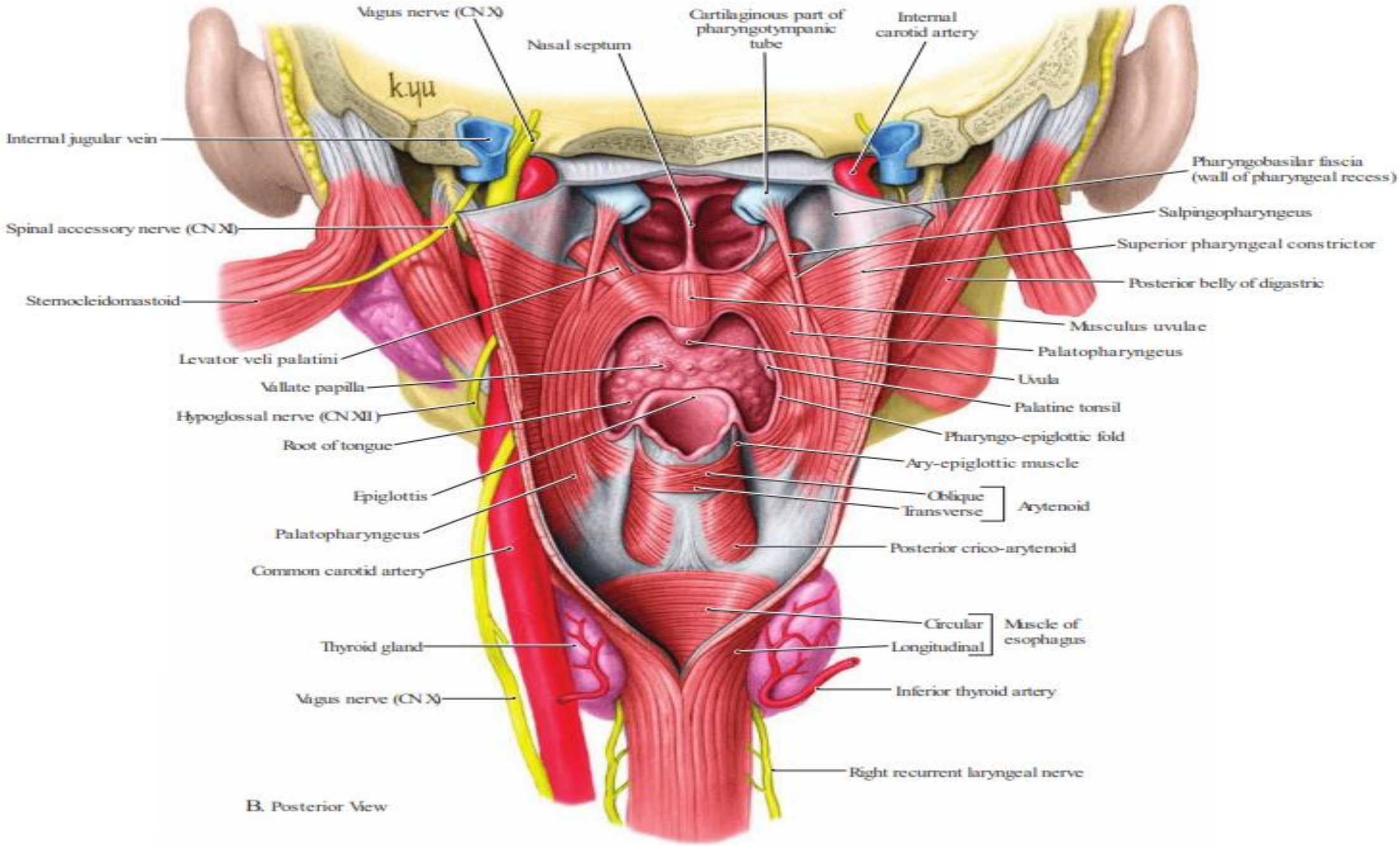

B. Posterior View

TABLE 11.10 Muscles of the Pharynx

Muscle	Origin	Insertion	Nerve Supply	Action
Superior constrictor	Medial pterygoid plate, pterygoid hamulus, pterygomandibular ligament, mylohyoid line of mandible	Pharyngeal tubercle of occipital bone, raphe in midline posteriorly	Pharyngeal plexus	Aids soft palate in closing off nasal pharynx, propels bolus downward
Middle constrictor	Lower part of stylohyoid ligament, lesser and greater cornu of hyoid bone	Pharyngeal raphe	Pharyngeal plexus	Propels bolus downward
Inferior constrictor	Lamina of thyroid cartilage, cricoid cartilage	Pharyngeal raphe	Pharyngeal plexus	Propels bolus downward
Stylopharyngeus	Styloid process of temporal bone	Posterior border of thyroid cartilage	Glossopharyngeal nerve	Elevates larynx during swallowing
Salpingopharyngeus	Auditory tube	Blends with palatopharyngeus	Pharyngeal plexus	Elevates pharynx
Palatopharyngeus	Palatine aponeurosis	Posterior border of thyroid cartilage	Pharyngeal plexus	Elevates wall of pharynx, pulls palatopharyngeal arch medially

Circular muscles

Superior constrictor muscle

Middle constrictor muscle

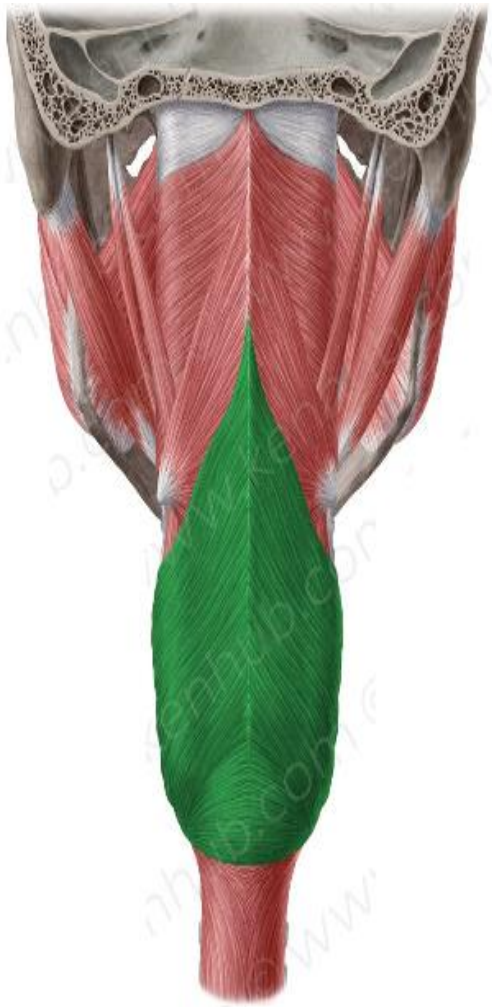

Inferior constrictor muscle

Longitudinal muscles

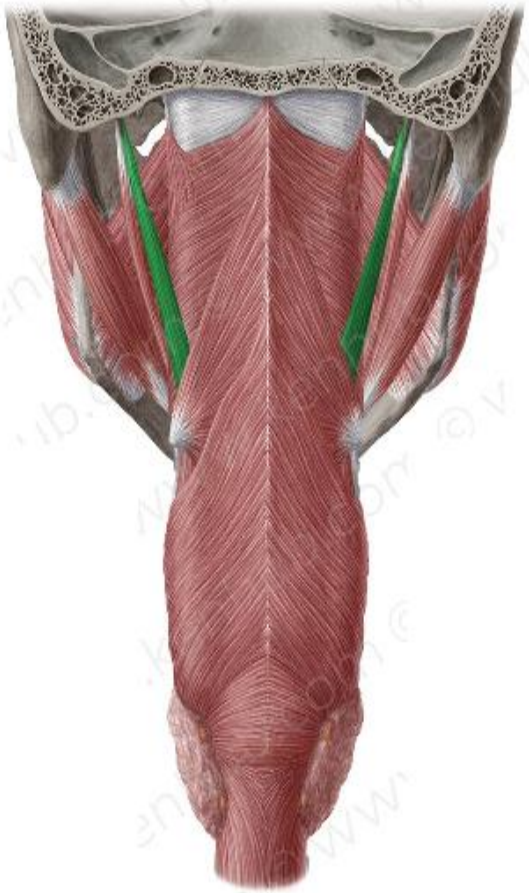

Stylopharyngeus muscle

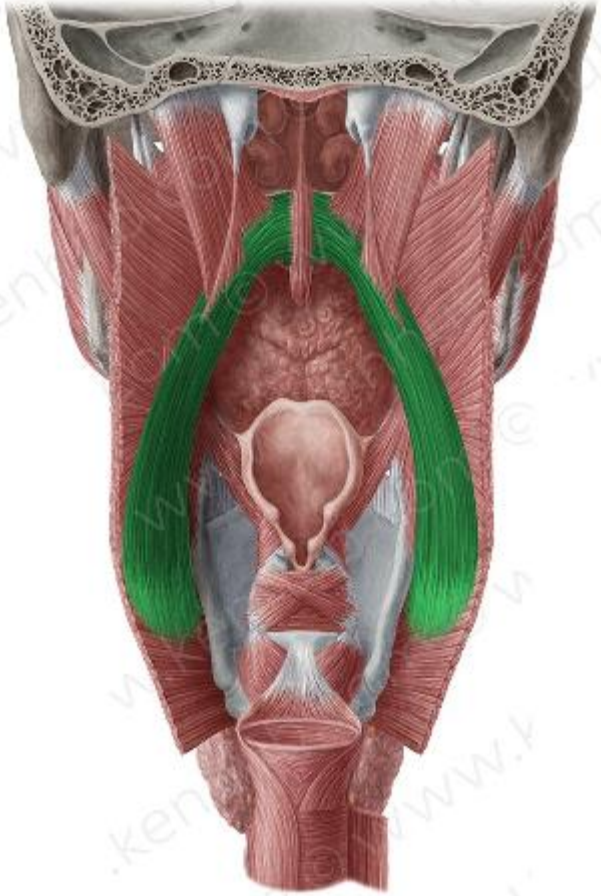

Palatopharyngeus muscle

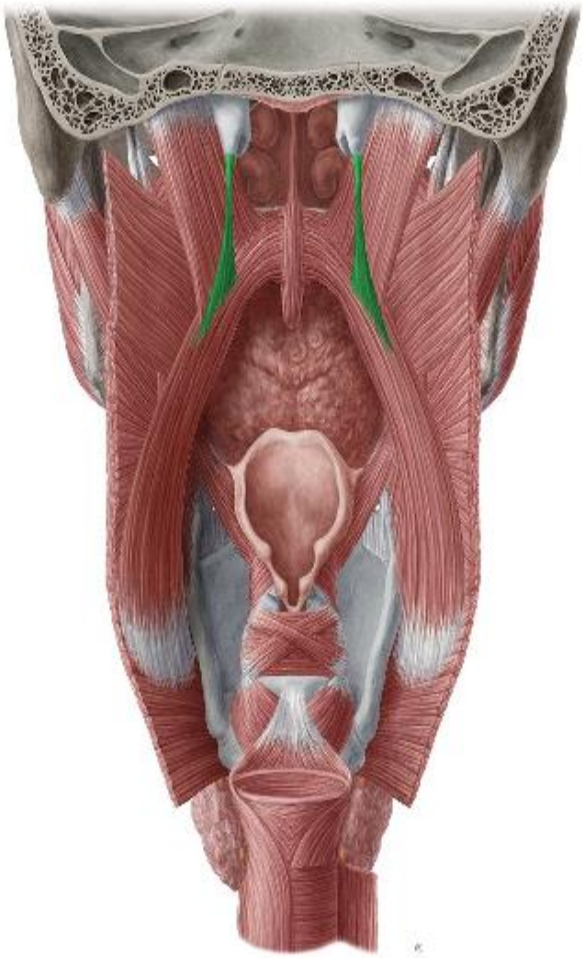

Salpingopharyngeus muscle

THANK YOU

The larynx and the pterygopalatine fossa

PREPARED BY:

Dr. REYADH AL-RASHIDI

The Larynx

The larynx is an organ that provides a protective sphincter at the inlet of the air passages and is responsible for voice production. It is situated below the tongue and hyoid bone and between the great blood vessels of the neck and lies at the level of the fourth, fifth, and sixth cervical vertebrae (Fig. 11.87). It opens above into the laryngeal part of the pharynx, and below is continuous with the trachea. The larynx is covered in front by the infrahyoid strap muscles and at the sides by the thyroid gland.

The framework of the larynx is formed of cartilages that are held together by ligaments and membranes, moved by muscles, and lined by mucous membrane.

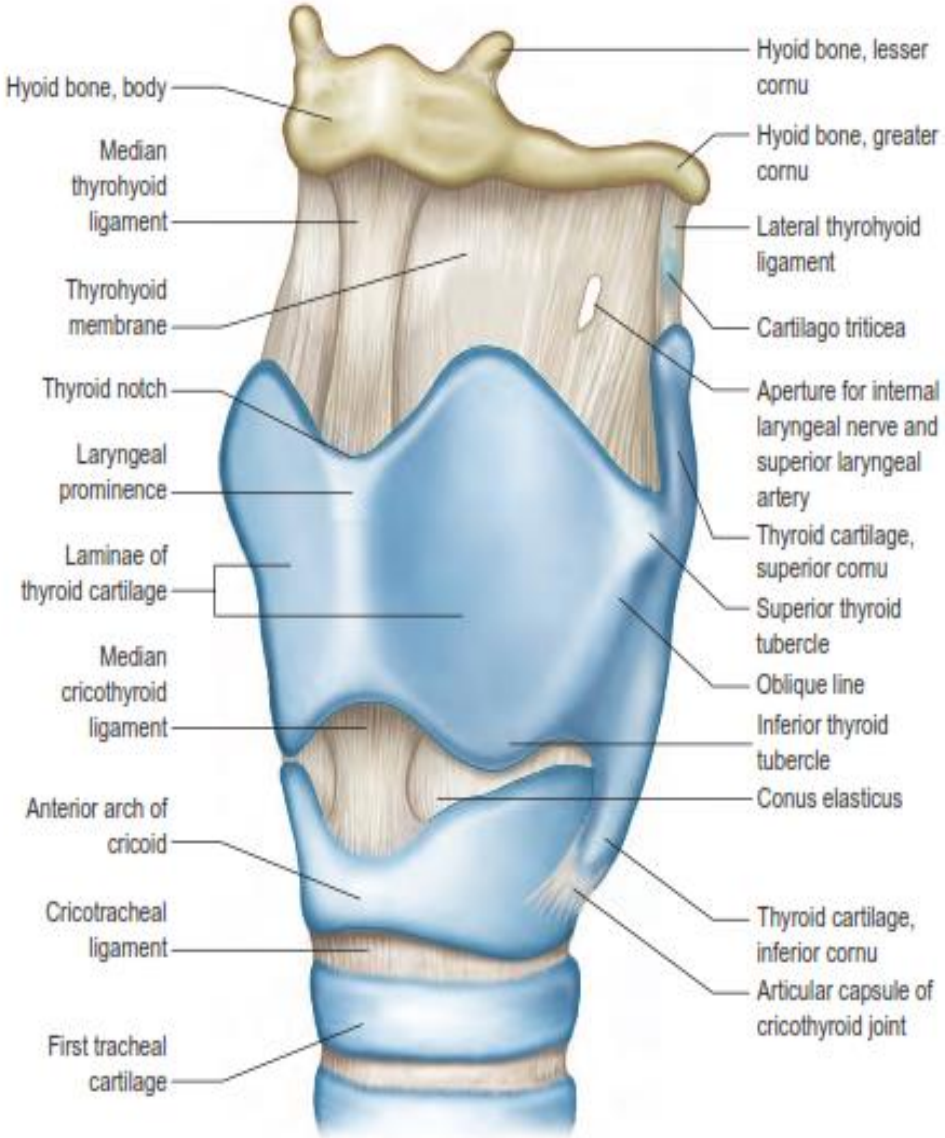

FIGURE 11.98 An anterolateral view of the laryngeal cartilages and ligaments.

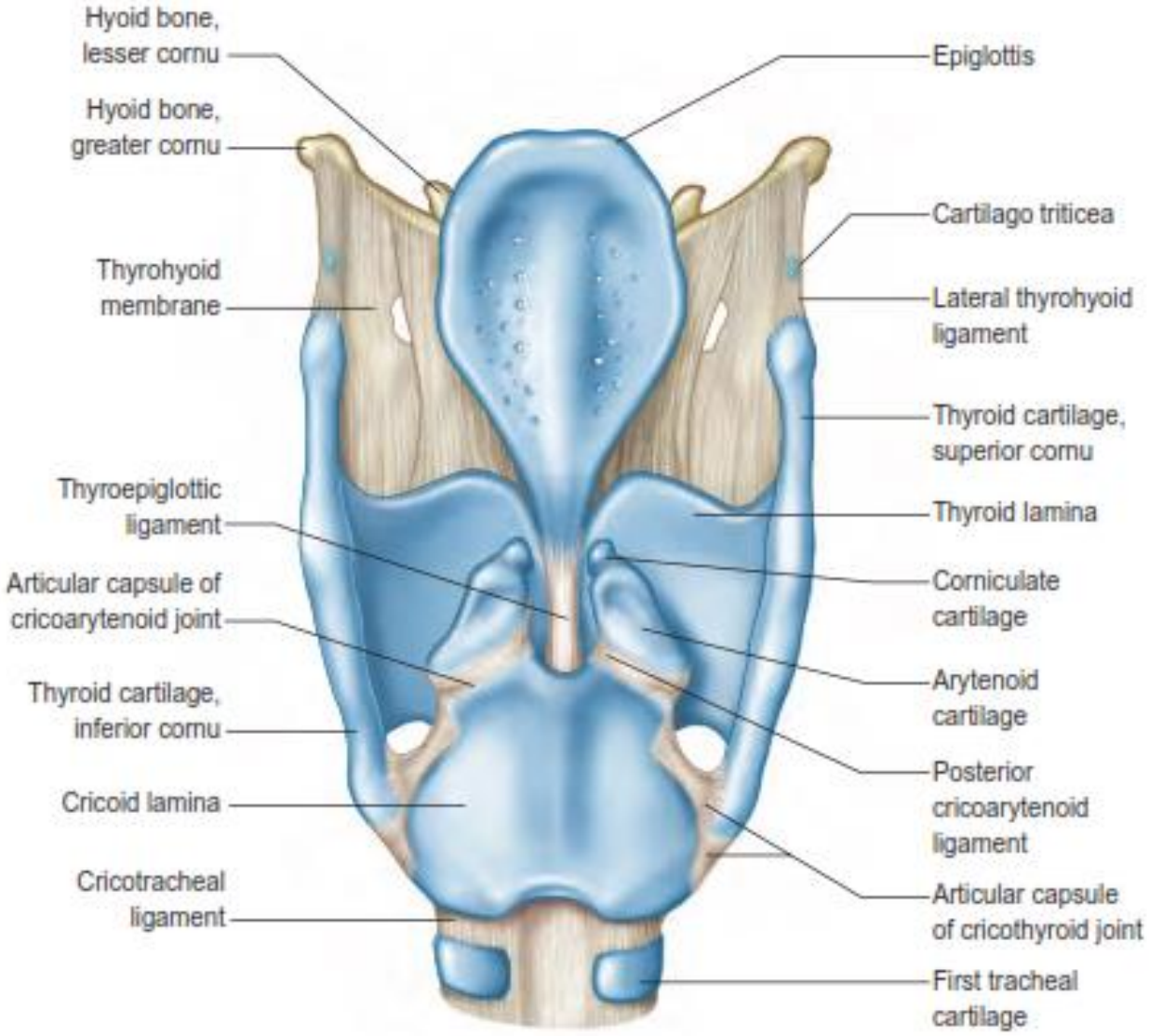

A posterior view of the laryngeal cartilages and ligaments.

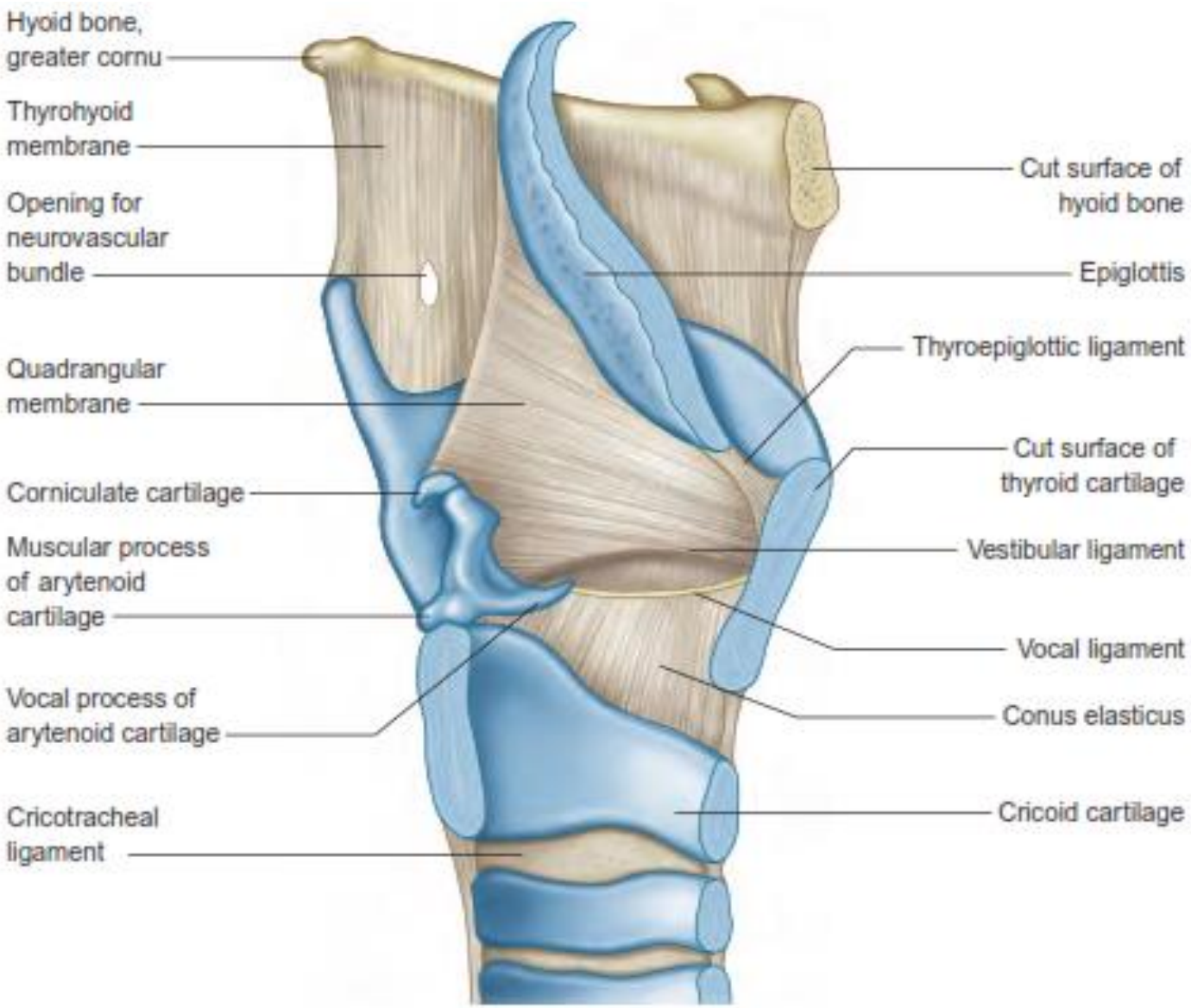
Hyoid bone, greater cornu
Thyrohyoid membrane
Opening for neurovascular bundle
Quadrangular membrane
Corniculate cartilage
Muscular process of arytenoid cartilage
Vocal process of arytenoid cartilage
Cricotracheal ligament
Cut surface of hyoid bone
Epiglottis
Thyroepiglottic ligament
Cut surface of thyroid cartilage
Vestibular ligament
Vocal ligament
Conus elasticus
Cricoid cartilage

Cartilages of the Larynx

Thyroid cartilage: This is the largest cartilage of the larynx (Fig. 11.98) and consists of two laminae of hyaline cartilage that meet in the midline in the prominent V angle (the so-called Adam's apple). The posterior border extends upward into a **superior cornu** and downward into an **inferior cornu.** On the outer surface of each lamina is an oblique line for the attachment of muscles.

Cricoid cartilage: This cartilage is formed of hyaline cartilage and shaped like a signet ring, having a broad plate behind and a shallow arch in front (Fig. 11.98). The cricoid cartilage lies below the thyroid cartilage, and on each side of the lateral surface is a facet for articulation with the inferior cornu of the thyroid cartilage.

Arytenoid cartilages: There are two arytenoid cartilages, which are small and pyramid shaped and located at the back of the larynx (Fig. 11.98). They articulate with the upper border of the lamina of the cricoid cartilage. Each cartilage has an **apex** above that articulates with the small corniculate cartilage, a **base** below that articulates with the lamina of the cricoid cartilage, and a **vocal process** that projects forward and gives attachment to the vocal ligament. A **muscular process** that projects laterally gives attachment to the posterior and lateral cricoarytenoid muscles.

Corniculate cartilages: Two small conical-shaped cartilages articulate with the arytenoid cartilages (Fig. 11.99). They give attachment to the aryepiglottic folds.

Cuneiform cartilages: These two small rod-shaped cartilages are found in the aryepiglottic folds and serve to strengthen them (Fig. 11.99).

Epiglottis: This leaf-shaped lamina of elastic cartilage lies behind the root of the tongue (Fig. 11.98). Its stalk is attached to the back of the thyroid cartilage. The sides of the epiglottis are attached to the arytenoid cartilages by the aryepiglottic folds of mucous membrane. The upper edge of the epiglottis is free. The covering of mucous membrane passes forward onto the posterior surface of the tongue as the **median glossoepiglottic fold**

Muscles of the Larynx

Intrinsic Muscles

muscles modify the laryngeal inlet (Fig. 11.99):

- **Narrowing the inlet:** The oblique arytenoid muscle
- **Widening the inlet:** The transverse arytenoid muscle

muscles move the vocal folds (cords) (Fig. 11.99):

- **Tensing the vocal cords:** The cricothyroid muscle
- **Relaxing the vocal cords:** The thyroarytenoid (vocalis) muscle
- **Adducting the vocal cords:** The lateral cricoarytenoid muscle
- **Abducting the vocal cords:** The posterior cricoarytenoid muscle

TABLE 11.12 Intrinsic Muscles of the Larynx

Muscle	Origin	Insertion	Nerve Supply	Action
Muscles Controlling the Laryngeal Inlet				
Oblique arytenoid	Muscular process of arytenoid cartilage	Apex of opposite arytenoid cartilage	Recurrent laryngeal nerve	Narrows the inlet by bringing the aryepiglottic folds together
Transverse arytenoid	Back and medial surface of arytenoid cartilage	Back and medial surface of opposite arytenoid cartilage	Recurrent laryngeal nerve	Widens the inlet by pulling the aryepiglottic folds apart
Muscles Controlling the Movements of the Vocal Folds (Cords)				
Cricothyroid	Side of cricoid cartilage	Lower border and inferior cornu of thyroid cartilage	External laryngeal nerve	Tenses vocal cords
Thyroarytenoid (vocalis)	Inner surface of thyroid cartilage	Arytenoid cartilage	Recurrent laryngeal nerve	Relaxes vocal cords
Lateral cricoarytenoid	Upper border of cricoid cartilage	Muscular process of arytenoid cartilage	Recurrent laryngeal nerve	Adducts the vocal cords by rotating arytenoid cartilage
Posterior cricoarytenoid	Back of cricoid cartilage	Muscular process of arytenoid cartilage	Recurrent laryngeal nerve	Abducts the vocal cords by rotating arytenoid cartilage

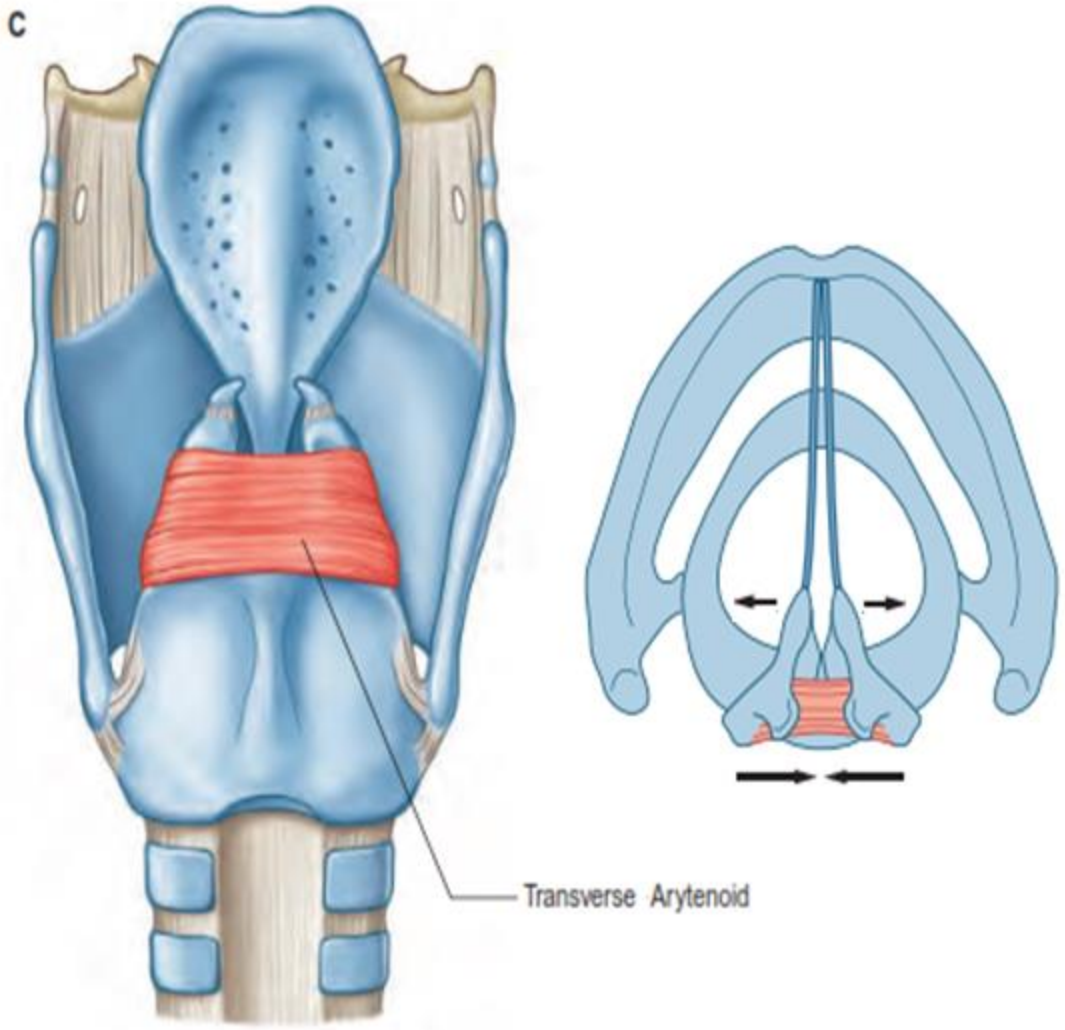

Posterior aspect

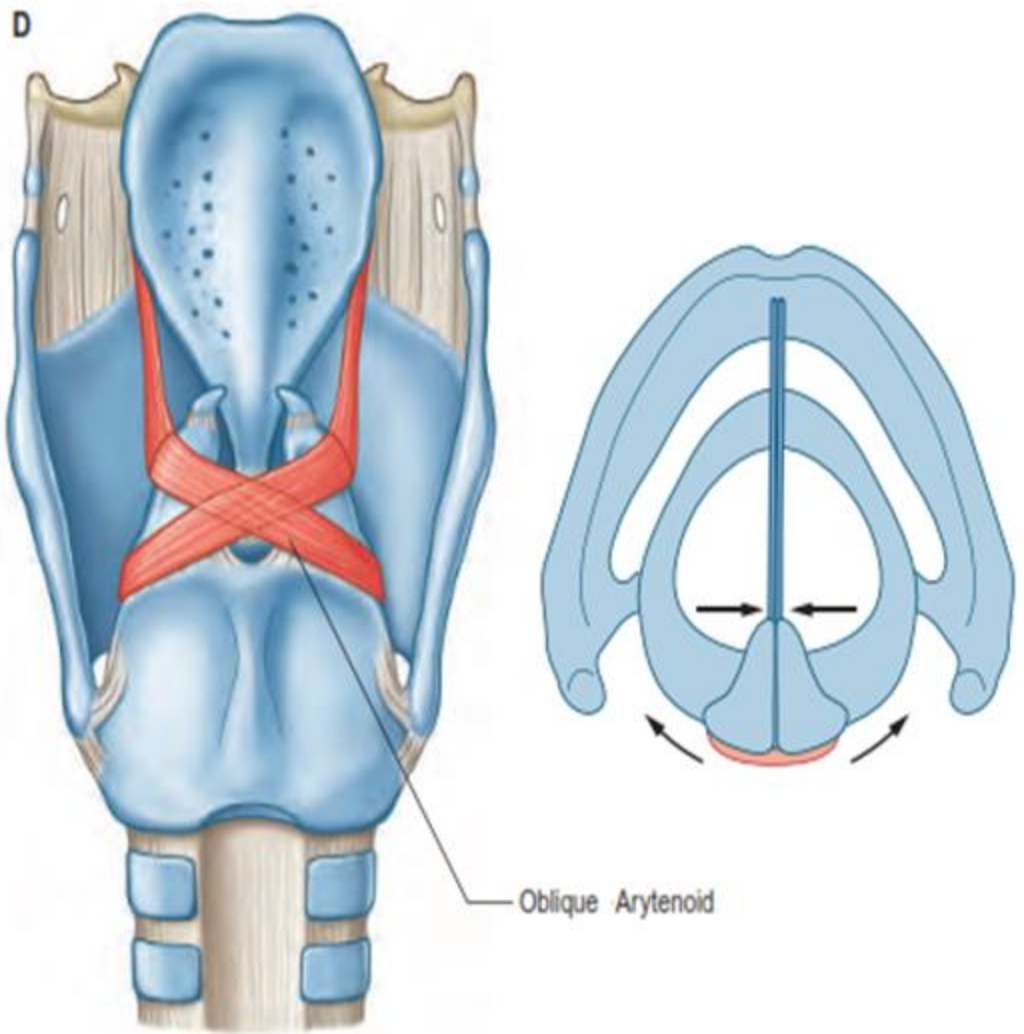

Posterior aspect

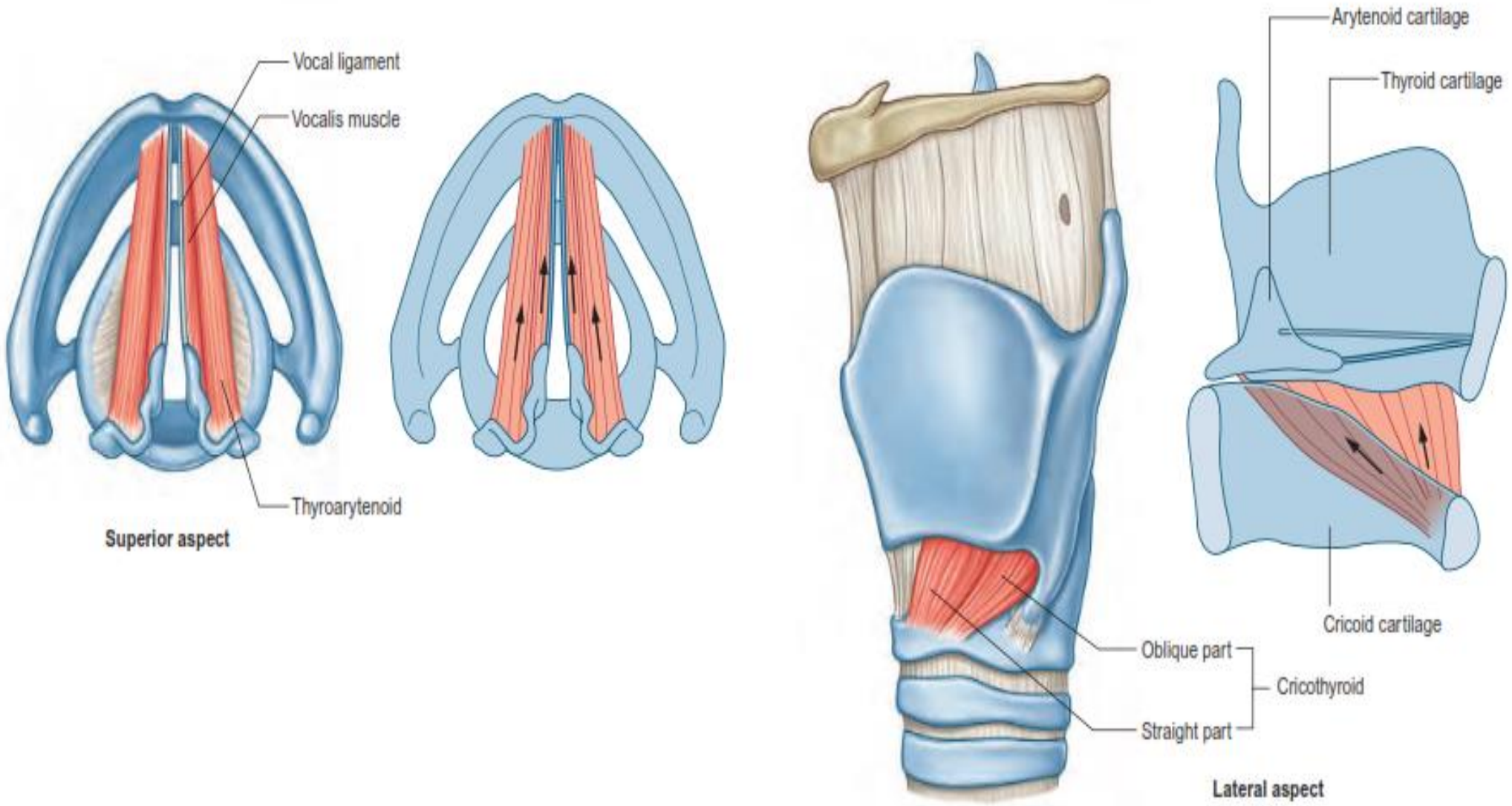

The intrinsic muscles of the larynx in posterior or lateral views, with their actions shown alongside in a superior view. The arrows indicate the direction of movement of the cartilage in each case.

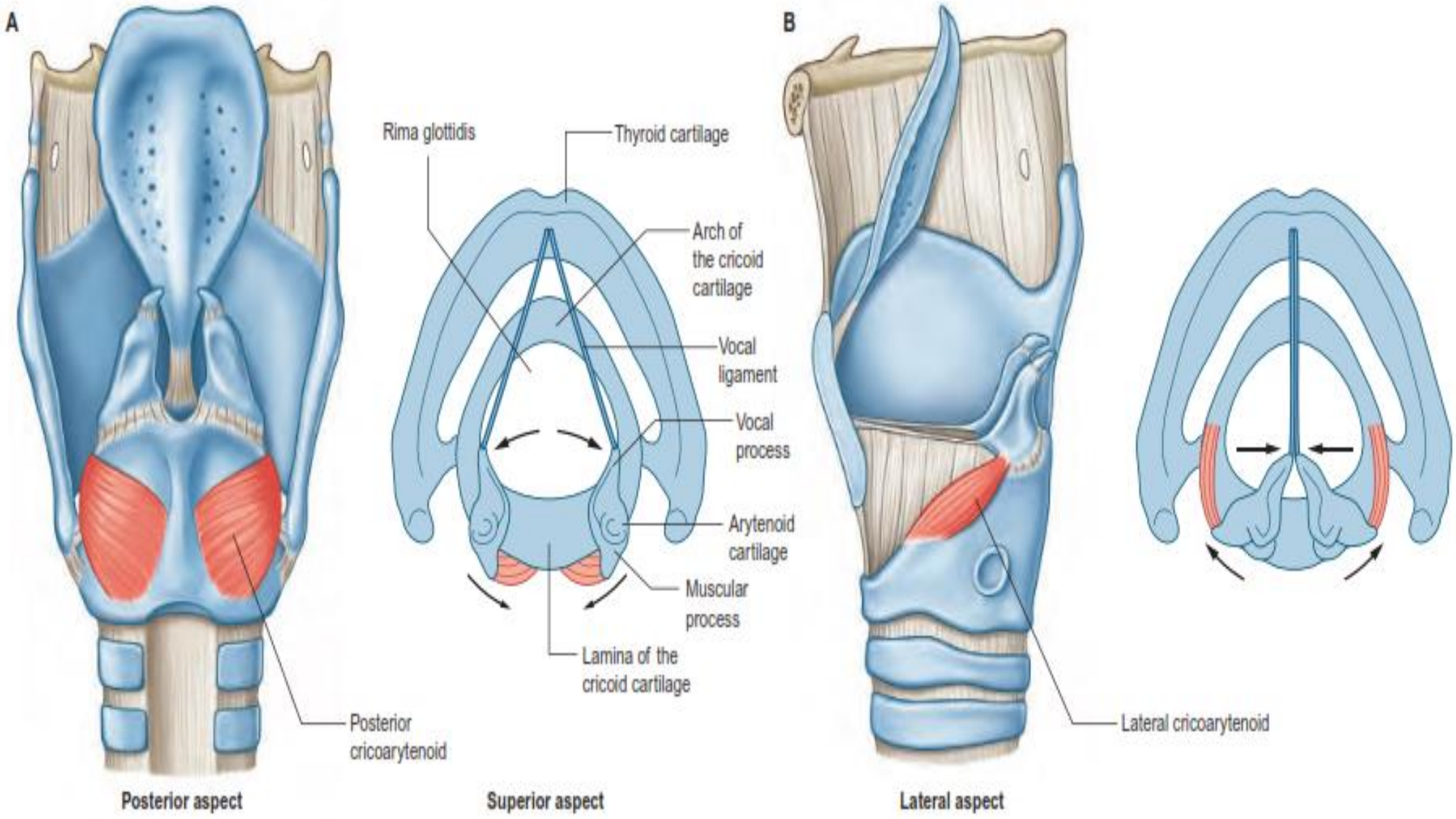
A
B
Rima glottidis
Thyroid cartilage
Arch of the cricoid cartilage
Vocal ligament
Vocal process
Arytenoid cartilage
Muscular process
Lamina of the cricoid cartilage
Posterior cricoarytenoid
Lateral cricoarytenoid
Posterior aspect
Superior aspect
Lateral aspect

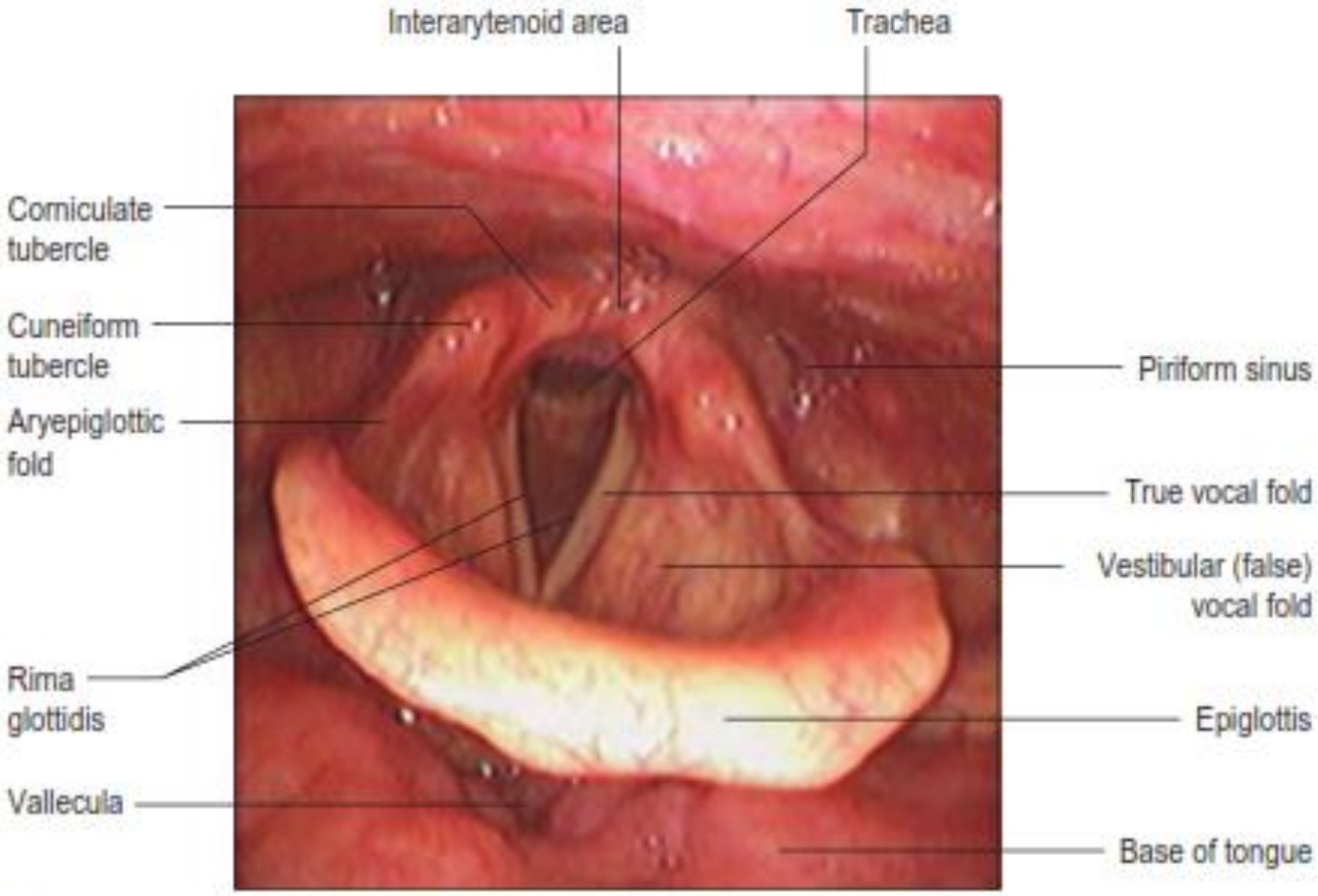

Fig. 35.8 The true vocal folds viewed through a fibreoptic endoscope.

The pterygopalatine fossa

The pterygopalatine fossa (sphenopalatine fossa) is a fossa in the skull. A human skull contains two pterygopalatine fossa, one on the left side, and another on the right side. Each fossa is a cone-shaped paired depression deep to the infratemporal fossa and posterior to the maxilla on each side of the skull, located between the pterygoid process and the maxillary tuberosity close to the apex of the orbit

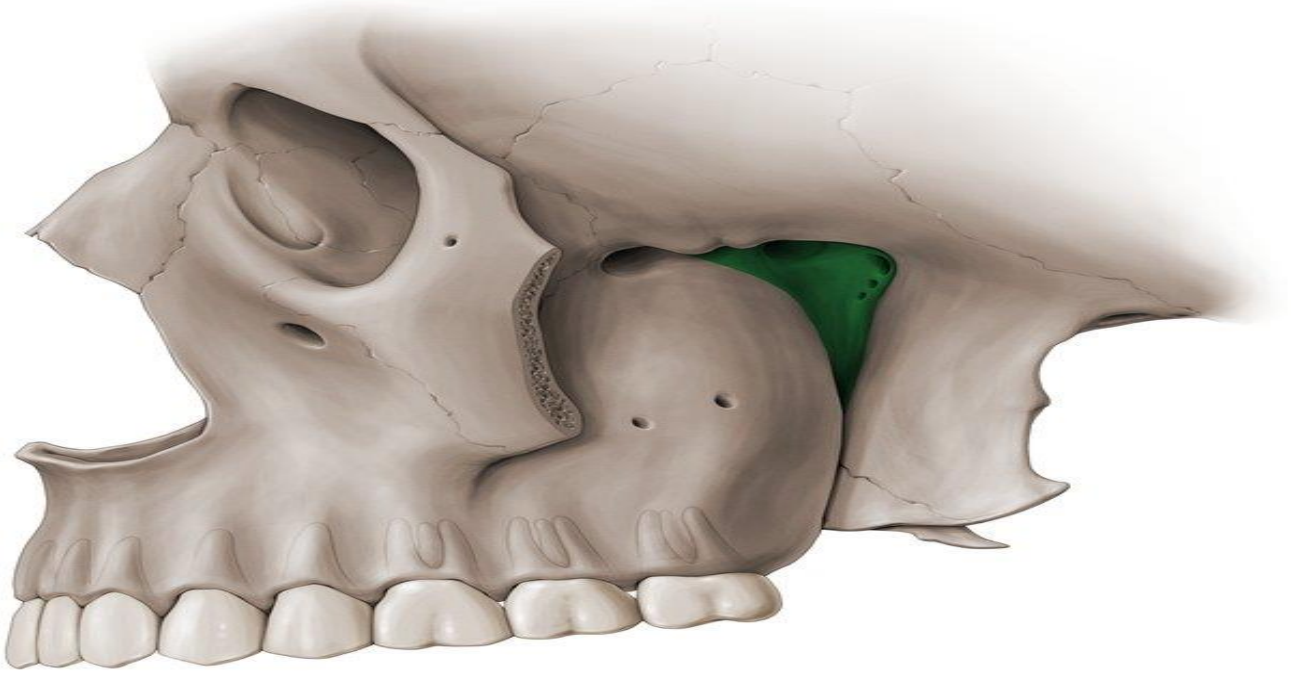

The walls:

1. Maxilla
2. Palatine
3. Sphenoid

- The anterior wall is formed by the maxilla.
- The medial wall is formed by the palatine.
- The roof and the posterior wall are formed by the sphenoid.

contents:

1. maxillary nerve [V2]
2. pterygopalatine ganglion
3. 3rd part of the maxillary artery

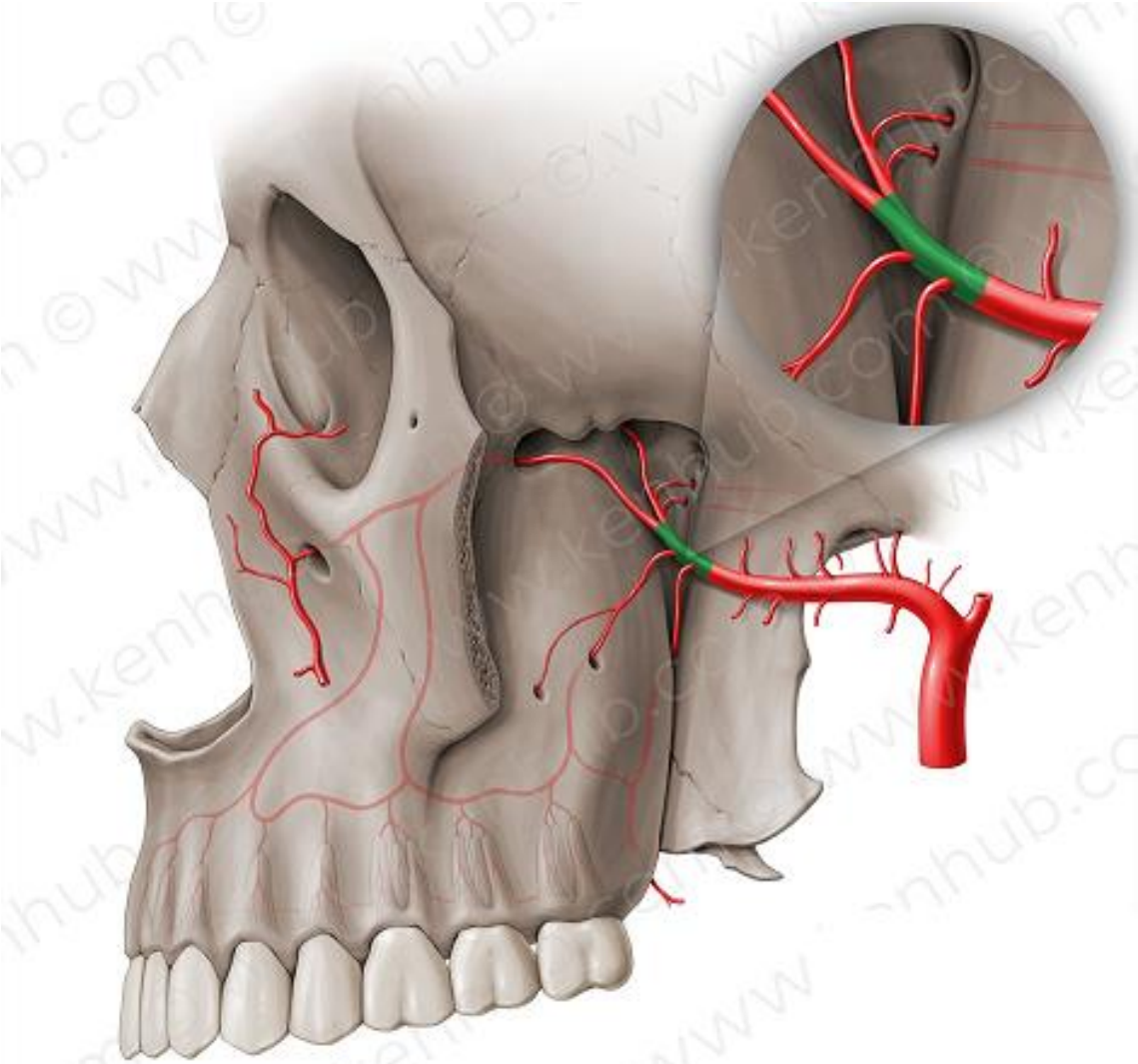

3rd part of the maxillary artery

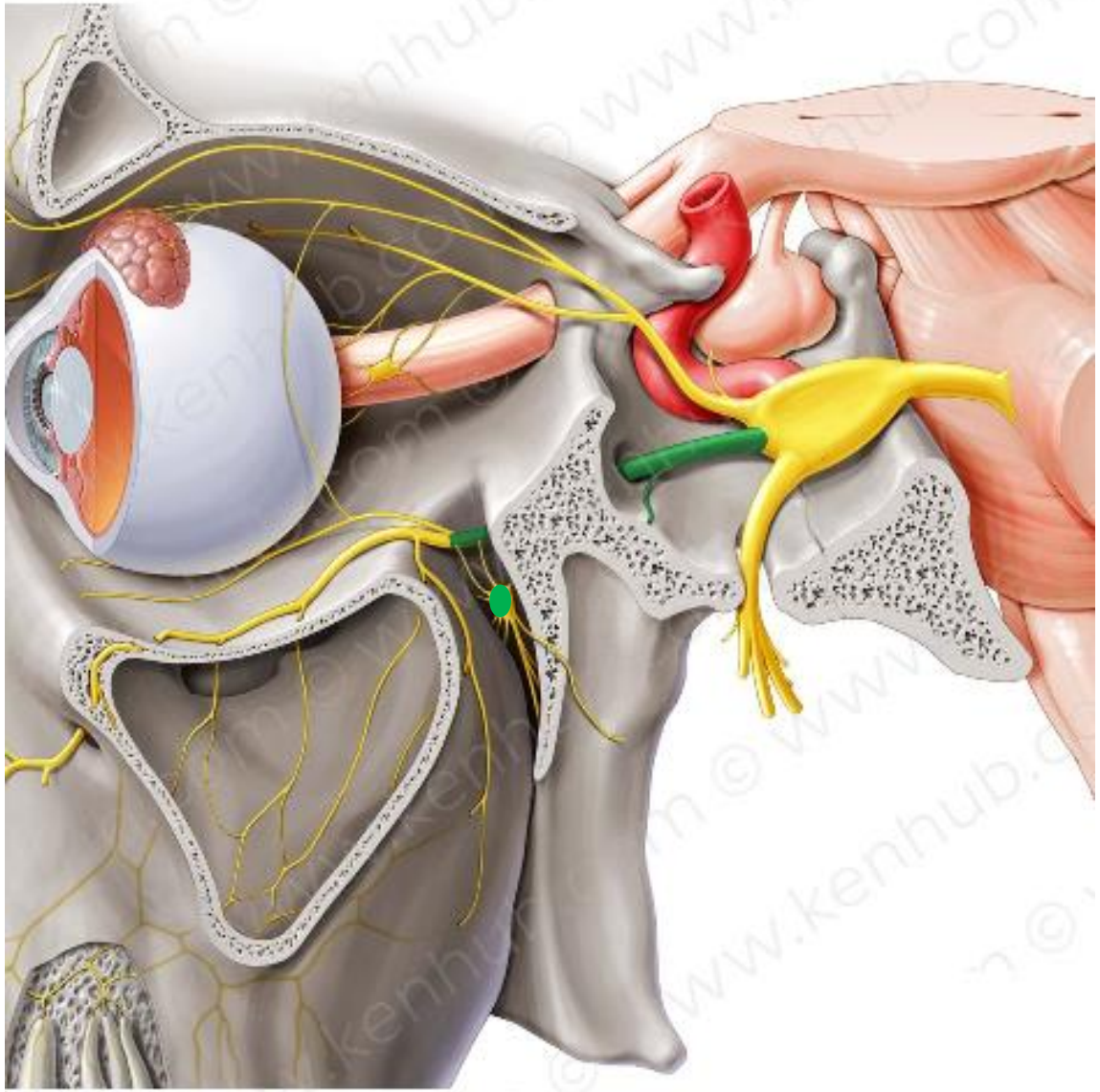

maxillary nerve [V2]
pterygopalatine ganglion

Openings

Pterygomaxillary fissure	It communicates with the infratemporal fossa and transmits the posterior superior alveolar nerve and the maxillary artery.
Foramen rotundum	It communicates with the middle cranial fossa and from there, it transmits the maxillary nerve (V2).
Pterygoid canal	It communicates with the middle cranial fossa. It transmits the nerve of pterygoid canal, artery of the pterygoid canal and vein of the pterygoid canal.
Inferior orbital fissure	It communicates with the orbit and transmits the zygomatic nerve and the infraorbital artery and vein.
Palatine canal	It communicates with the oral cavity via the greater palatine and the lesser palatine canals, which transmit the greater palatine and lesser palatine nerves.
Sphenopalatine foramen	It communicates with the lateral wall of the nasal cavity and transmits nasal nerves and the sphenopalatine artery.

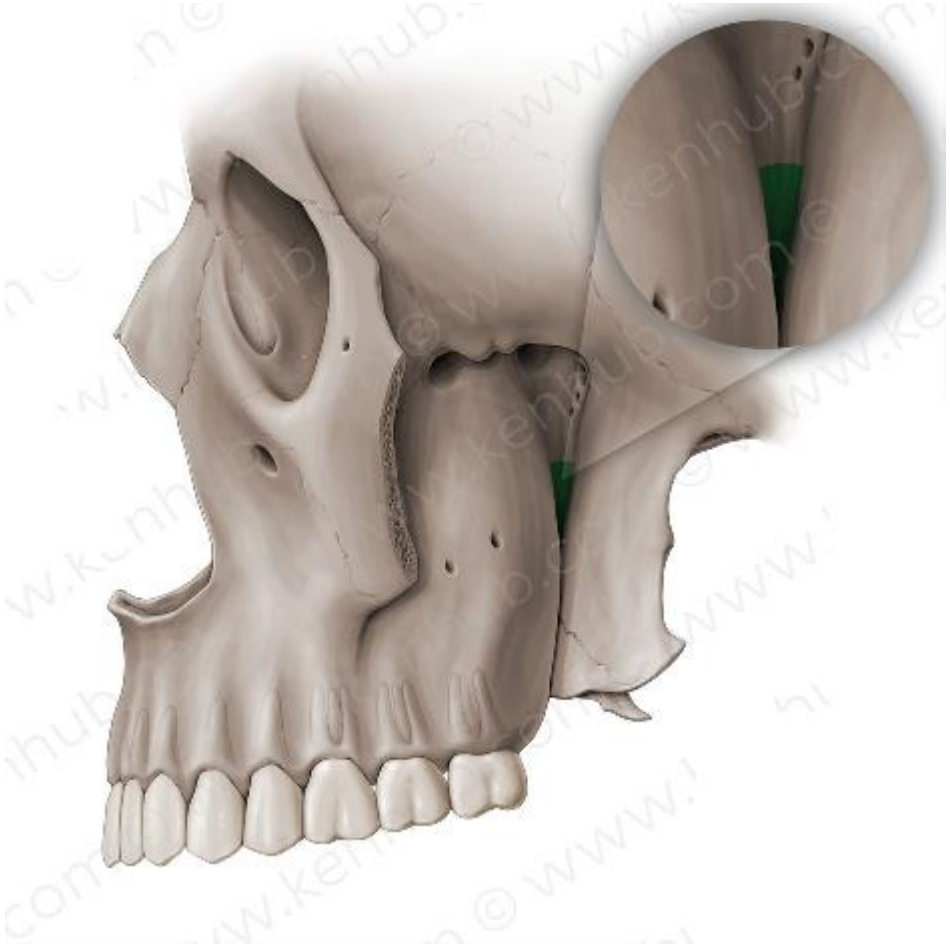

Pterygomaxillary fissure

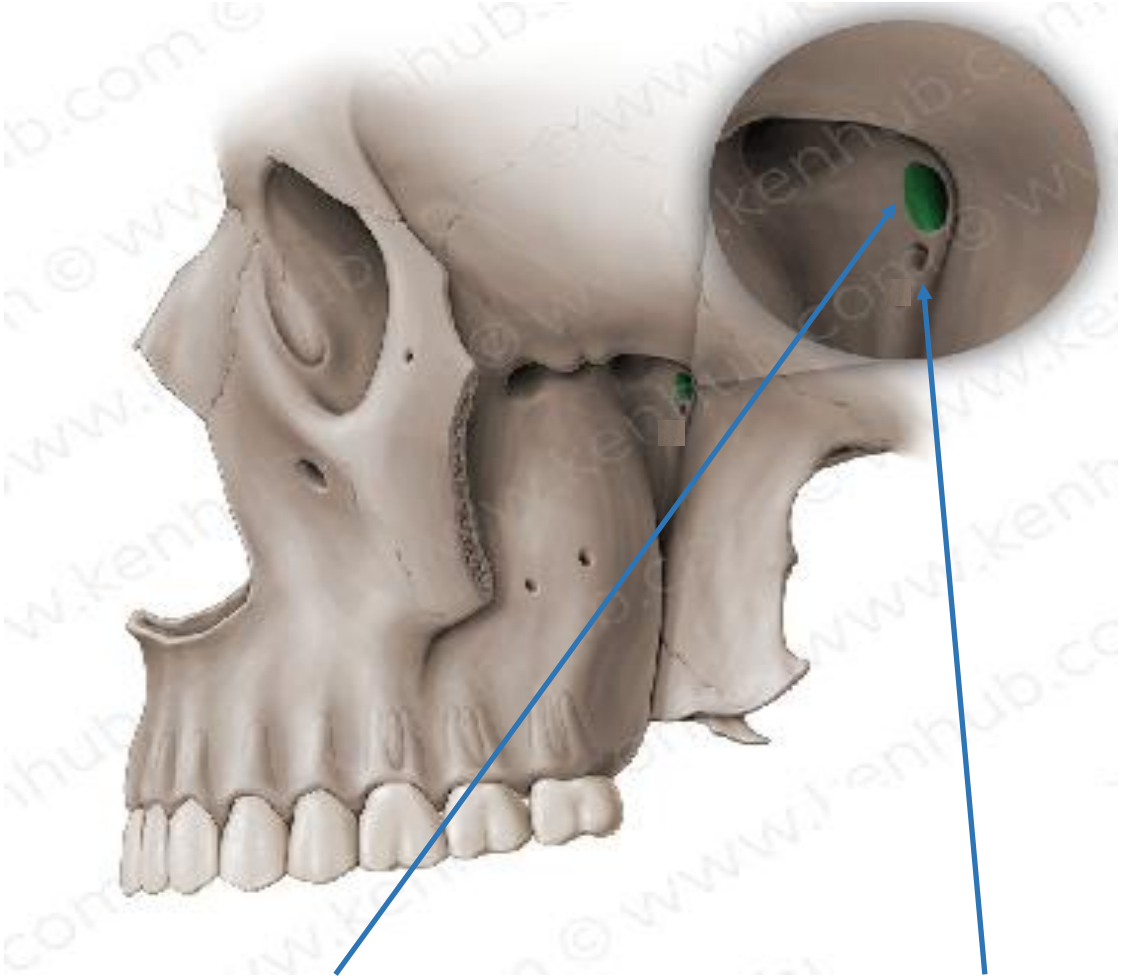

Foramen rotundum

Pterygoid canal

Inferior orbital fissure

Sphenopalatine foramen

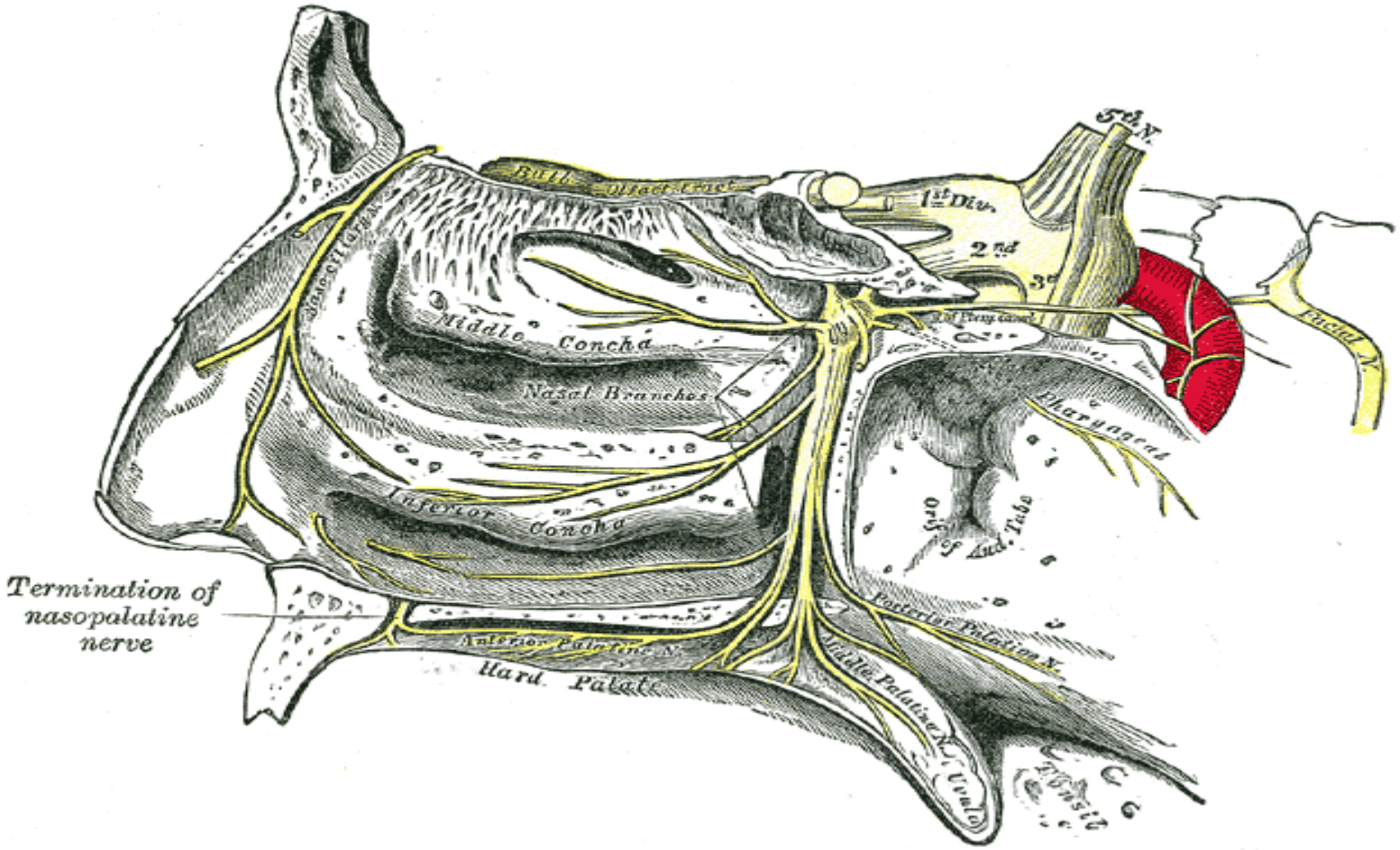

Palatine canal

THANK YOU