Practical parasitology

2nd stage

Medical laboratory technique department

By

Dr. Thuraya Khaled

2020-2021

Lab: 1

Medical Parasitology: - is the science that deals with the study of **parasites**, their classification, morphological forms, epidemiology, which cause human infections and the diseases they produce.

Parasite: **-** an organism that live in or on an organism of another species (known as the **host**).

Parasites of humans are classified into six major divisions:

1. Protozoa (amoebae, flagellates, ciliates, Sporozoans, coccidian, microsporidia)
2. Nematoda or(roundworms)
3. Platy helminthes, or flatworms (Cestodes, trematode)
4. Pentastomids, or (tongue worms)
5. Acanthocephalan, or(thorny-headed worms)
6. Arthropoda (e.g., insects, spiders, mites, ticks)

Types of parasites:-

1 – Obligatory parasites
2 –Facultative parasites
3 – Ectoparasites
4 – Endoparasites (extracellular, intracellular)

Types of life cycle :-

1 – Direct life cycle
2 – Indirect life cycle

Types of hosts :-

1 – Accidental host.
2 – Definitive host (final host).
3 – Intermediate host .
4 – Reservoir host.
5 – Vector host (mechanical or biological).
6 – Carrier.

Laboratory Safety Principles or rules (warnings)

1 - Check the safety requirements throughout the laboratory of fire extinguisher, first aid kits, laundries and alarms.

2 - Wear protective clothing (goggles, gloves, lab coat, and shoes).

3 - Avoid touching objects (e.g : pencils, cell phones, door handles) while wearing gloves.

4 - Pencils, labels, or any other materials should never be placed in your mouth.

5 - Caution must be taken when use gas burners. Be sure gas burners are turned off when finished.

6 - Do not eat food or drink water in the lab. Do not use lab glassware as food or water containers.

7 – Protect your hands safety:

- wash hands after every lab.
- Handle glassware, sharp tools & heated containers carefully.

8 - Unplug electrical equipment after use. Keep all electrical wires away from water.

9 - Keep nonessential books and clothing far away from your work area.

10 - Wipe the bench tops down with disinfectant both before you begin your work and after you have completed your work.

Some warning symbols (Hazard signs) in the laboratory:

Laboratory diagnosis of Parasitic Protozoa & Helminthes;

- **Types of specimens:-**

1 - Feces (stool): to identify the parasites or their eggs that present in the digestive tract *ex: E.histolytica.*
2 - Urine: for parasites present in urogenital tract *ex: Trichomonas vaginalis.*
3 - Blood: for parasites present in blood *ex: Plasmodium vivax*
4 - Sputum: For parasites present in respiratory tract ex: larva of Ascars
5 - Swap or scrap: For parasites present in skin *ex: leishmania spp*
Stains:-
1 – Dyes for **blood-**parasitic protozoa:-
Lieshman's stain
Giemsa stain
Field's stain
2 – Dyes for **intestine-**parasitic protozoa:-
Iodine stain
1%Eosin stain

- **Methods for identification of parasites: -**

We can identify the parasites in two main ways:-
1- Clinical diagnosis
2 - Laboratory diagnosis
Laboratory methods for identification of parasites include the following:-
1 – Fecal or stool examination includes the following methods:-
A - Direct wet smear or temporary method
B - Sedimentation method
C – Floatation method
D - Permanent preparation
2 – Urine examination
3 – Blood examination
3 – Sputum examination
4 – Mouth examination
5 – Vaginal examination

6 – tissue & body fluid examination
7 – Cerebrospinal fluid analysis
8 – Tape technique
9 – Culture
10 – Laboratory animal's inoculation
11 – Immunological & serodiagnosis.
12 – Molecular techniques like PCR

Lab:2

General Stool Examination (G.S.E)

- **Collection of Fecal Specimens**

  1- Collect about 10-15 gm of stool in a dry, clean, container. Make sure no urine, water, soil or other material gets in the container.
  2- If it is not possible to obtain feces, collect a specimen by inserting a cotton wool swab into rectum for about 10 sec.
  3- Label the specimen with the patient's name, date and time of collection. And send it with a request form to reach laboratory as soon as possible.
  • Fresh stool should be examined immediately, or preserved.

- **Solutions for preserve stool specimens**

  1 - 10% formalin
  2 - Potassium Dichromate
  3 - Polyvinyl alcohol (PVA)
  4- Normal saline 0.9%

1. Formalin 10 %:

Preparation of 10% Formalin:

Commercial Formaldehyde (37- 40%) 100 ml dissolved in 900 ml distilled water.

Advantages:

- Formalin is an all-purpose fixative that is suitable for helminth eggs and larvae and protozoan cysts. Two concentrations are commonly used: 5% which is recommended for preservation of protozoan cysts, and 10%, which is recommended for helminth eggs and larvae.
- Can be used for concentration techniques (sedimentation techniques).

- Long shelf life and commercially available.
- Neutral formalin (buffered with sodium phosphate) helps maintain organism morphology with prolonged storage.

Disadvantages:

- The major disadvantage of formalin is that permanent stained smears cannot be prepared from formalin-preserved fecal specimens.
- Trophozoites do not preserve well in formalin and parasite morphology is not maintained adequately for a permanently stained fecal smear.

2. Polyvinyl Alcohol (PVA)

Advantages:

1. This fixative is recommended for the preservation of the trophozoite and cyst stages of the intestinal protozoa.
2. The PVA is a plastic resin that serves as adhesive for the stool material; i.e., when the stool-PVA mixture is spread onto the glass slide, it adheres because of the PVA component.
3. The greatest advantage in the use of PVA is the fact that a permanent stained smear can be prepared (giving excellent result with trichrome staining) and has a long shelf life (months to years).
4. PVA is particularly useful for liquid specimens and should be used at a ratio of 3 parts PVA to 1part fecal specimen.

Disadvantages:

Difficult to prepare in the laboratory.

3. Preparation of Iodine:

- Iodine is a temporary stain for protozoa cysts.

Preparation:

Potassium iodide 10 gm, powdered iodine crystals 5 gm, distilled water 100 ml.

- Dissolve KI in about 20-30 ml of distilled water.
- Add iodine and heat gently with constant mixing until iodine is dissolved.
- Dilute to 100 ml with distilled water.
- Filter the resulting solution.
- Place the filtered solution, known as the stock solution, into a stoppered container.

- Dilute the filtered stock solution 1:5 with distilled water, creating a working solution, before use.
- Store in amber glass-stoppered bottle in a dark place.

From the best, solution must be prepared every 3 weeks.

4. **Preparation of Normal saline (N.S):**

- Dissolve 8.5 g NaCl in 1L water.
- Autoclave 15 min at 121°C. Cool to room temperature

GSE include the following:

1-Macroscopic Examination include :-
1- Color 2- Odor 3- PH reaction 4- Consistency 5- Naked eye parasite 6- blood 7- Mucous

- **Color**
  - ❖ The normal color of stool is **brown**.
  - ❖ Abnormal colors :

No.	color	Likely reason
1	Black color	iron medication or upper GIT bleeding (due to peptic ulcer, stomach carcinoma)
2	Bright red color	lower GIT bleeding
3	Clay color (gray-white)	obstructive jaundice
4	Pale brown color	With a greasy consistency indicate pancreatic deficiency causing malabsorption of fat (often with offensive odor).
5	Yellow-green color	occurs in the stool of breast-fed infants who lack normal intestinal flora
6	Red brown color	Due to some drugs such as :Tetracyclines, and Rifambicin antibiotics

- **Odor**
  Normally **offensive**
  Abnormal:
  Very offensive: usually seen in cases of constipation and with certain types of food
  that produce excessive gases, Bacterial infection and malabsorption.

Foul-smelling stool: characteristic of steatorrhea.

- **PH reaction**
  Normally **variable**
  Abnormal:
  -High alkaline stool
  Physiological: cause by using High protein diet
  Pathological: Secretory diarrhea, Colitis or Antibiotic use
  -High acidic stool
  Physiological :High carbohydrate diet
  Pathological Poor fat absorption, poor absorption of sugars as in lactose intolerance
  Note: Breast-fed infants have slightly acid stool; bottle-fed infants have slightly alkaline stool.

- **Consistency**
  Normally well formed & semi solid
  Abnormal : watery, diarrhea, solid …etc
- **Mucous**
  Normally undetectable amount produce by GIT and found in the stool.
  Abnormal mucus in the sample appears as **white patches** and according to the amount of mucus it can be graded using signs (+, ++, +++).
  Mucus abnormally can be found in the stool in the following cases:
  1 - Ulcerative colitis.
  2 - Bacillary dysentery (mucous with fresh pus).
  3 - Amoebic dysentery (mucous with fresh blood).

- **Gross blood**
  Normally no blood seen in the stool
  Abnormal fresh blood (Hematochezia) seen in cases of lower GIT bleeding
  -**blood that is mixed with stool:** ulcerative colitis, colorectal cancer
  -**blood that not mixed with stool:** Bilharzia (Schistosoma *mansoni* infection), anal Fissure piles.
  -**blood with diarrhea and mucous** : Amoebic dysentery.
- **Naked eye parasites**
  Normally no parasites are present in the stool.
  Abnormal :
  -segments of tape worms
  -Whole worms : Two worms can be seen by naked eye in the stool

2. Microscopic Examination:-

Procedure: -

1- Place a drop of saline on the slide.
2- Pick up a small amount of fecal material on the end of an applicator stick.
3- Emulsify in the saline and cover with a cover slip.
4- Examine on low and high power.

Note: Take small amounts of material from several different areas (stool surface and deep inside), especially from bloody and/or mucoid areas.

Typical report of G.S.E

General Stool Examination (G.S.E)	
Patient's name :	**Date :**
Age :	**Time :**
Gender :	
By Doctor :	
Macroscopic Examination	**Microscopic Examination**
Color:	**RBCs :** /H.P.F
Odor :	**Pus cells:** /H.P.F
Consistency:	**Epi.cells:**
PH Reaction:	**Mucous :**
Mucous :	**Trophozoite of :**
Blood :	**Cyst of :**
Naked eye parasites :	**Eggs of :**
Fecal occult blood test (FOBT) :	**Others :**
Others :	**Include fungi**
	Bacteria
	Indigested food
	Cellulose
Examiner :	
Date : / /20	
Time : :	

Lab: 3

1. Protozoa

- **General characteristic feature of protozoa:**

The protozoa are **unicellular eukaryotic** organisms, most of which are **microscopic**. They have a number of specialized **organelles** that are responsible for **life functions** and that allow further **division** of the group into classes. Most protozoa multiply by **binary fission** and are ubiquitous worldwide.

- **Classification of Clinically Important Protozoa:**

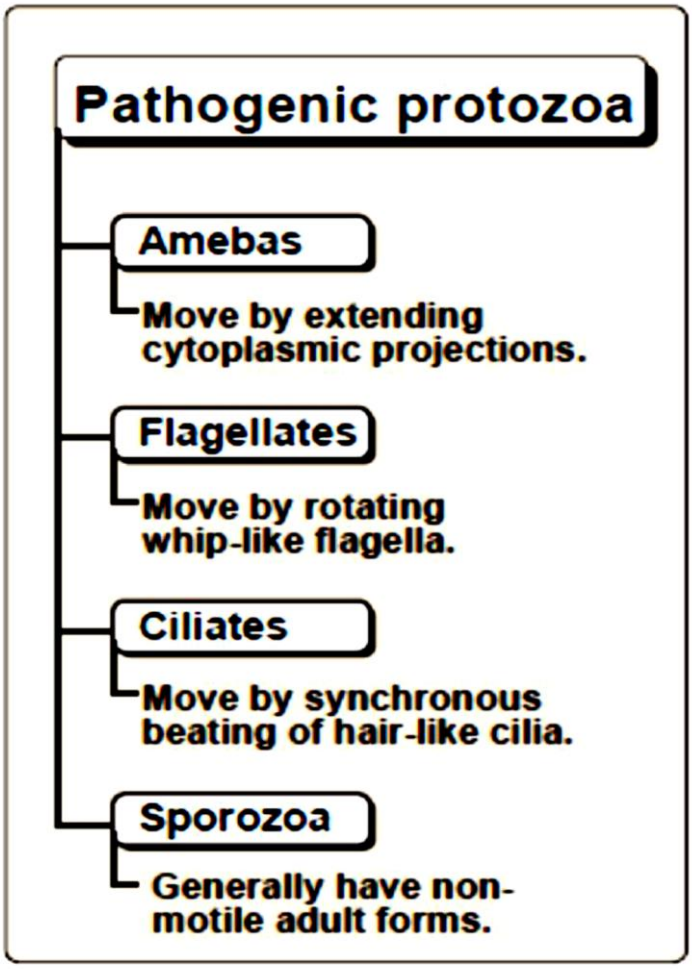

Figure 1.1: Clinically relevant protozoa, classified according to mode of locomotion.

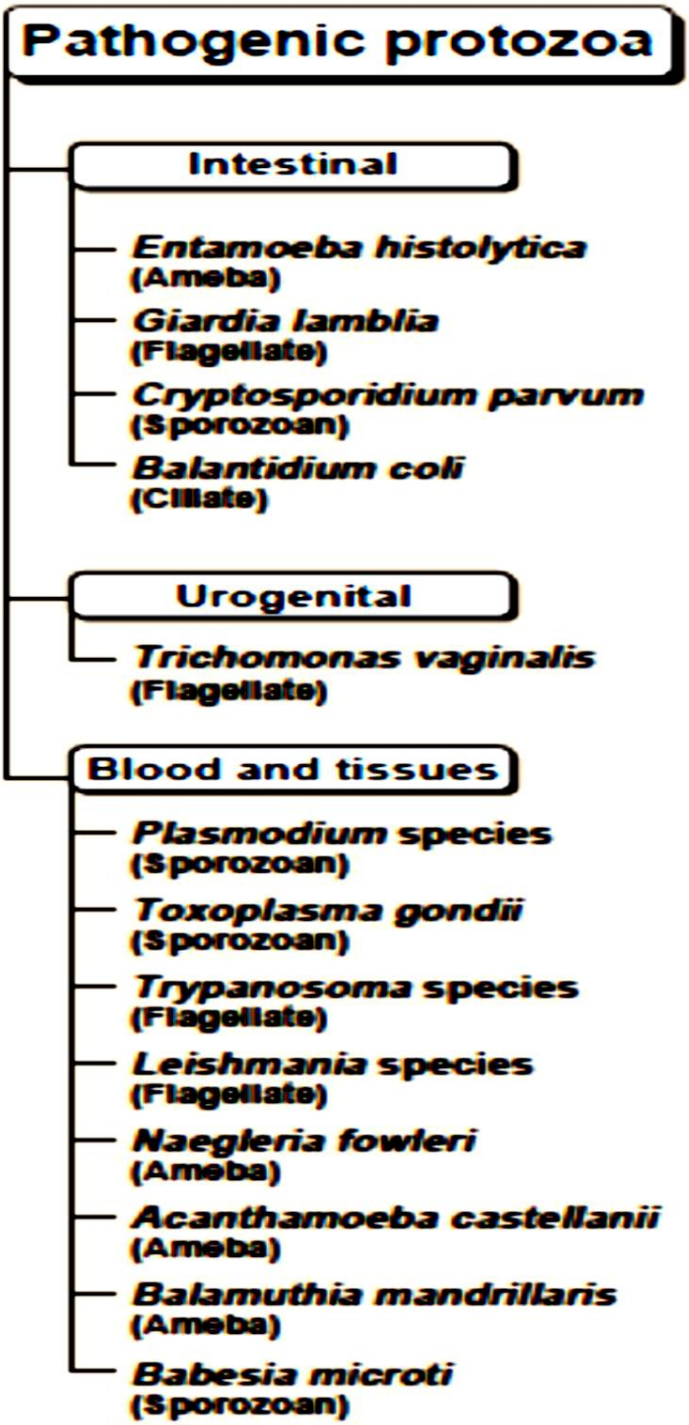

Figure 1.2 .Clinically relevant protozoa, classified according to site of infection.

1. Amoeba:

Classification:

Kingdom : Protista
Subkingdom : Protozoa
Phylum : Sacromastigophora
Subphylum : Sarcodina
Superclass : Rhizopoda
Class : Lobosea
Order : Amoebida

Protozoa Amoebae geneus	Natural habitat
Entamoeba histolytica	Large intestine
Entamoeba dispar	Large intestine
Entamoeba coli	Large intestine
Entamoeba hartmanni	Small intestine
Entamoeba gingivali	Oral cavity
Endolimax nana	Large intestine
Iodamoeba butschlii	Large intestine
Naegleria fowler	*Nasal Cavity,CNS*
Acanthamoeba culbertsoni	Nasal Cavity,CNS

1. *Entamoeba histolytica:*

Sites of infection : Intestinal site(Large intestine) and Extraintestinal site (liver , lung , pericardium, spleen, skin, and brain.

- **Disease :** Amebiasis , Amebic dysentery , hepatic abscesses ,lung abscesses , Skin amoebiasis
- **Stages :** It has four stages: **Trophozoite, precyst, cyst, metacyst .**
- **Infective stage : Tetranucleated cyst (having 4 nuclei)**
- **Diagnostic stage :** Motile trophozoite , cyst
- **Mode of transmission**: Ingestion of mature cyst through contaminated food or water.

Morphology:

Characteries	Trophozoite	Cyst
Size range	8-86um	8-22um
Shape	Arregular shape	spherical to round
Motility	Progressiv,finger-like hyaline pseudopods.	Non- motility
Number of nuclei	One	1-4
Karyosome	Small and central	Small and central
Periphral chromatin	Fine and evenl distributed	Fine and evenl distributed
Cytoplasm	Finely granular	Finely granular
Cytoplasminclusion	Ingested RBC	chromatoid bars, diffuse glycogen mass in younger cysts

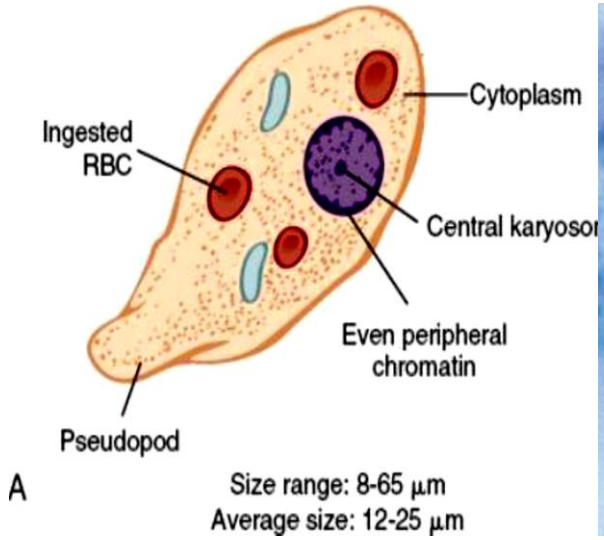

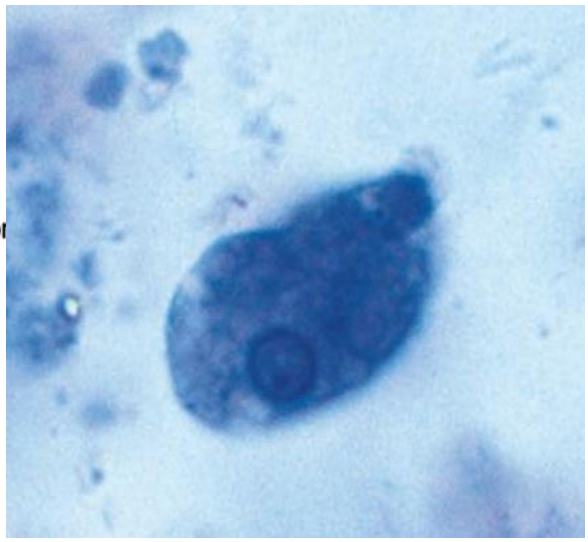

***Entamoeba histolytica* trophozoite**

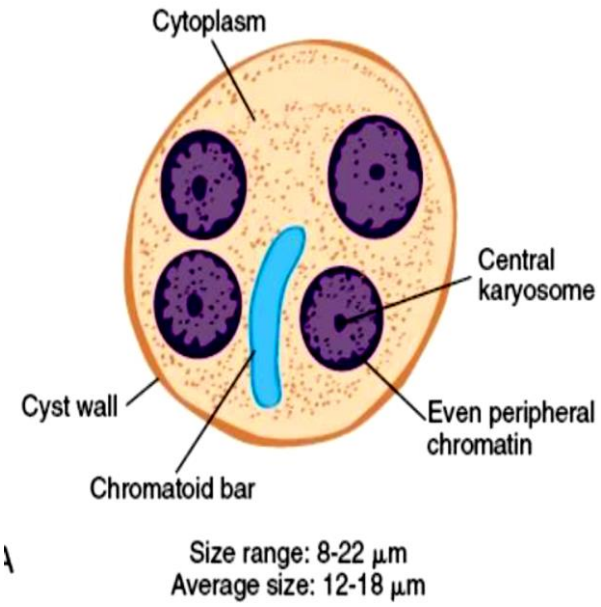

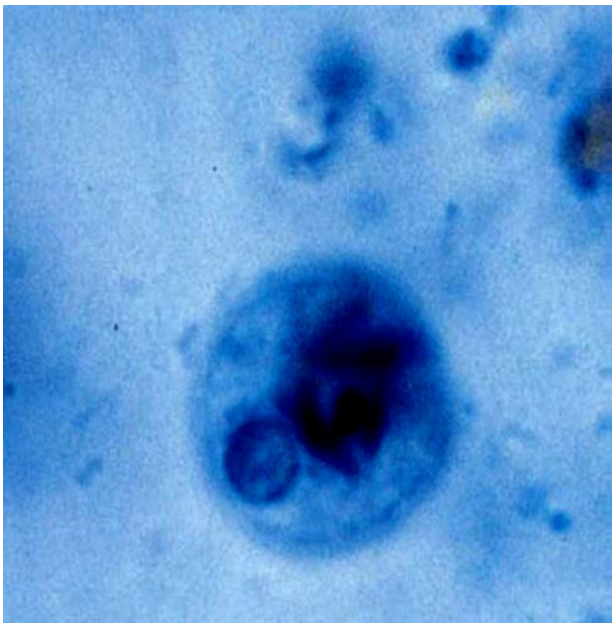

***Entamoeba histolytica* cyst.**

Life cycle: direct life cycle

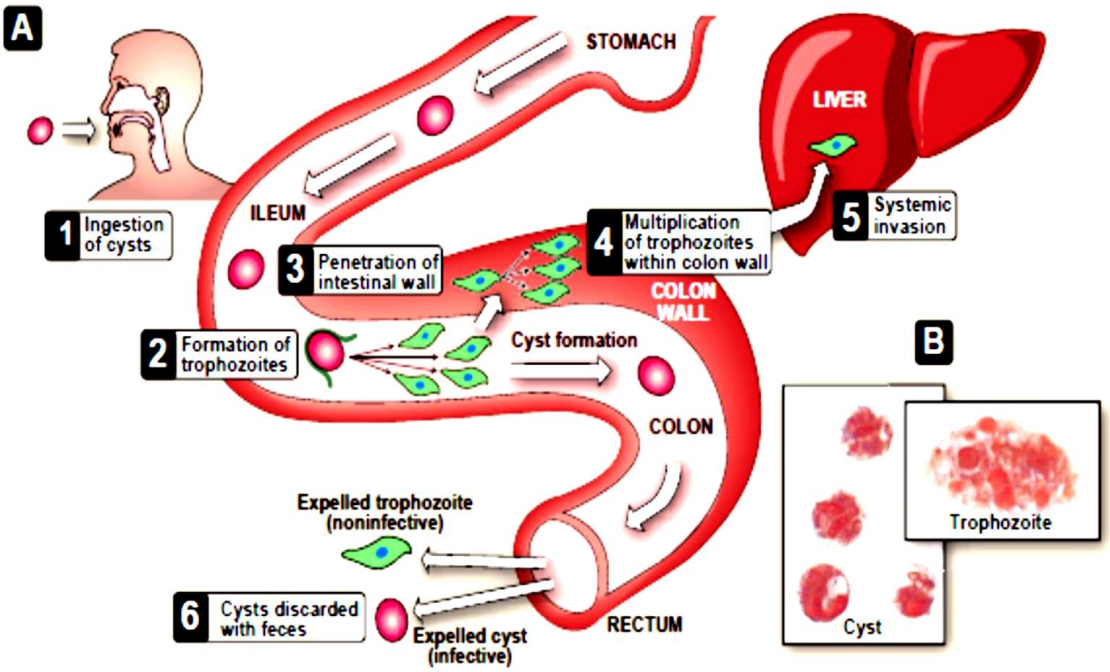

- **Laboratory Diagnosis:**
- **Intestinal amoebiasis** :
- Direct microscopic examination of the stool to **recover motile trophozoite (**containing red cells are diagnostic of amoebic dysentery).
- **In extra intestinal amoebiasis** :
- laboratory tests, including immunologically based procedures, may be used. Methods currently available include antigen tests, enzyme-linked immunosorbent assay (ELISA), indirect hemagglutination (IHA), gel diffusion precipitin (GDP), and indirect immunofluorescence (IIF).

2. *Entamoeba coli:*

- **Habitat :** large intestine
- **Disease** :.(non pathogen)
- **Stages :** ***Trophozoite , cyst.***
- **Infective stage : Cyst**
- **Diagnostic stage :** Trophozoites and cysts in stool .

Morphology:

Characteries	Trophozoite	Cyst
Size range	5-15 µm	8-35µm
Shape	Arregular shape	Round to spherical
Motility	Non Progressiv, blunt pseudopods.	Non- motility
Number of nuclei	One	1-8
Karyosome	Large, irregular shape, eccentric	Large, irregular shape, eccentric
Periphral chromatin	Unevenly distributed	Unevenly distributed
Cytoplasm	Coarse and granulated	Coarse and granulated
Cytoplasminclusion	Vacuoles containing bacteria often visible	diffuse glycogen mass in younger cysts ,Thin chromatoid bars with pointed to splintered ends in young cysts

- **Laboratory Diagnosis:**

Stool examination is the method of choice for the recovery of *E. coli* **trophozoites and cysts**. Although not considered as being pathogenic, the presence of *E. coli* suggests ingestion of contaminated food or drink.

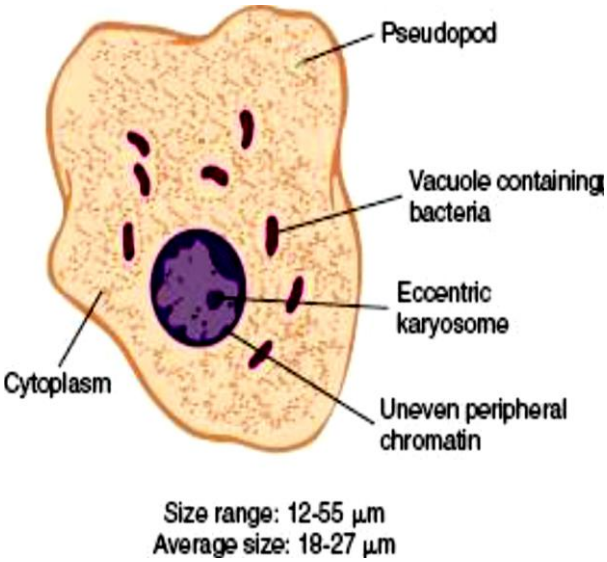

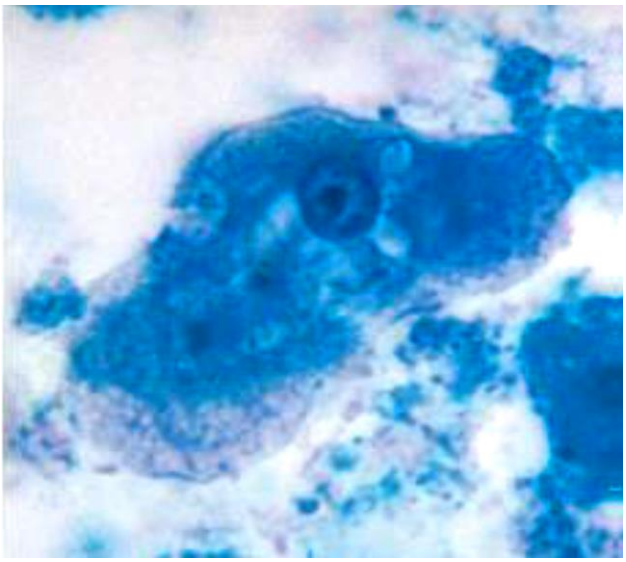

***Entamoeba coli* Trophozoite stage**

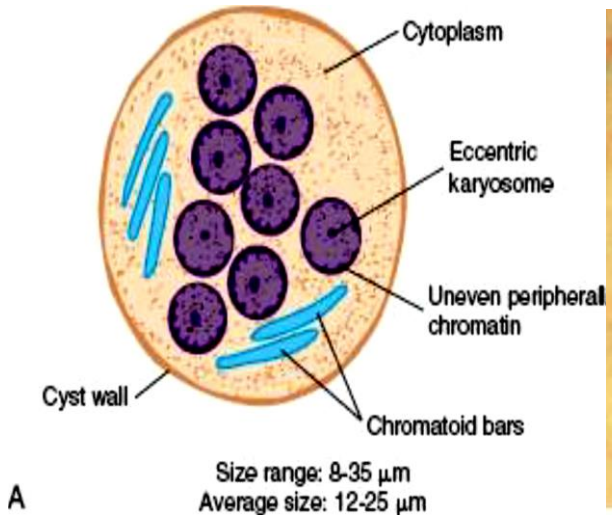

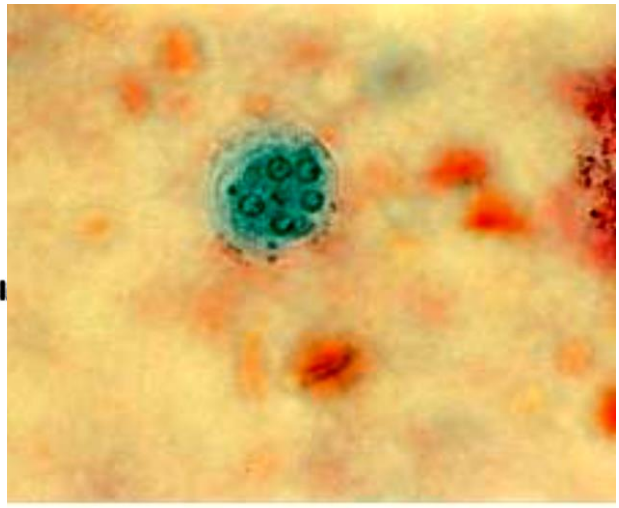

***Entamoeba coli* Cyst stage**

3. *Entamoeba gingivalis:*

- **Habitat** : Oral cavity , vaginal and cervical areas.
- **Disease :** It is nonpathogenic but **opportunistic**
- **Stages :** Only **Trophozoite (No cyst stage)**
- **Infective stage :** Trophozoite
- **Diagnostic stage** Trophozoite
- **Reproduction :** Asexually reproduction by Binary fission

Morphology:

Characteries	Trophozoite
Size range	8-20 µm
Motility	Active, varying pseudopod appearance
Number of nuclei	One
Karyosome	Centrally located
Peripheral chromatin	Fine and evenly distributed
Cytoplasm	Finely granular

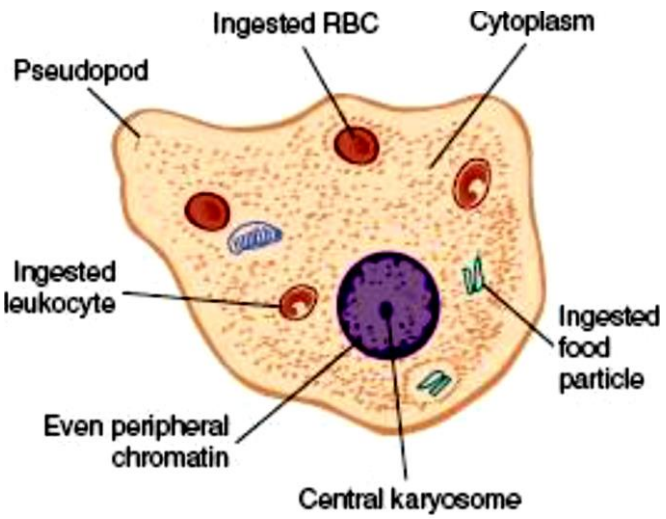

Size range: 8-20 µm

- **Laboratory Diagnosis:**
- An accurate diagnosis of *E. gingivalis* trophozoites may best be made by examining **mouth scrapings** particularly from the **gingival area**.
- Material from the **tonsillar crypts** and **pulmonary abscess**, as well as **sputum**, may also be examined.
- **Vaginal and cervical material** may be examined to diagnose *E. gingivalis* in the vaginal and cervical areas.

4. Endolimax nana:

Habitat : Large intestine
- **Disease :** considered as a nonpathogen .
- **Stages : Trophozoite, Cyst.**
- **Infective stage : Cyst**
- **Diagnostic stage** Finding the characteristic trophozoite and cyst stages in stool
- **Reproduction :** Asexually reproduction by Binary fission

Morphology:

Characteries	Trophozoite	Cyst
Size range	5-12 µm	4-12 µm
Shape	Arregular shape	Spherical, ovoid, ellipsoid
Motility	Sluggish, nonprogressive, blunt pseudopods.	Non- motility
Number of nuclei	One	One to four; four most common
Karyosome	Large, irregular, blotlike	Large, blotlike, usually central
Periphral chromatin	Absent	Absent
Cytoplasm	Granular and vacuolated	Cytoplasm Granular and vacuolated
Cytoplasm inclusion	Bacteria	Nondescript small mass Diffuse glycogen mass in young cysts

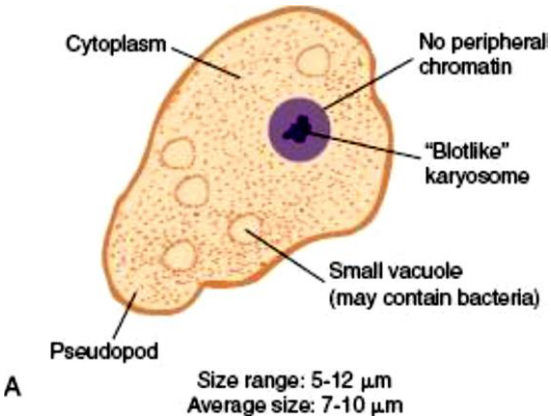

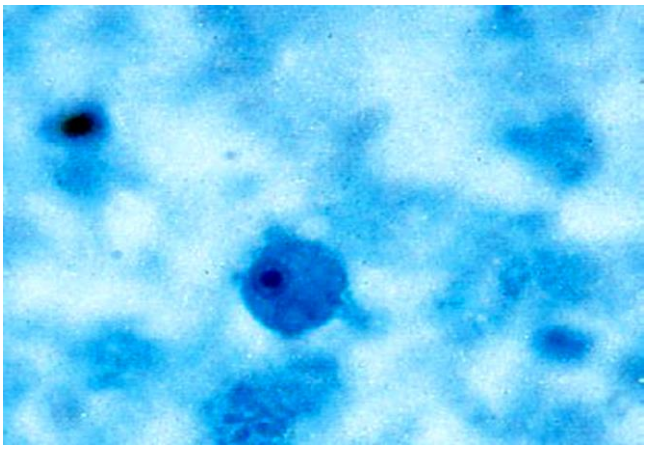

Trophozoite stage of *E. nana*

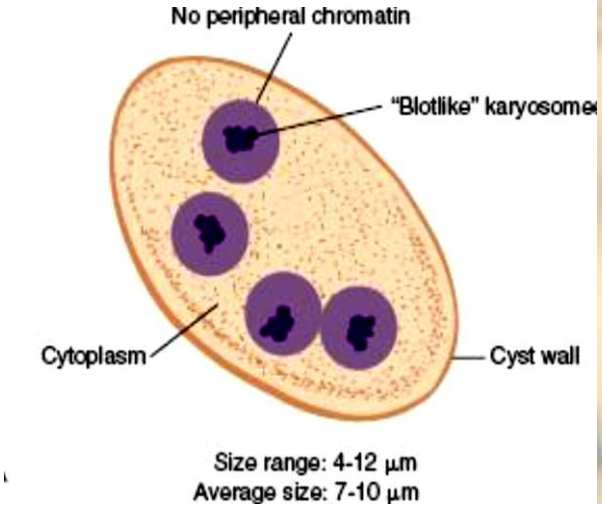

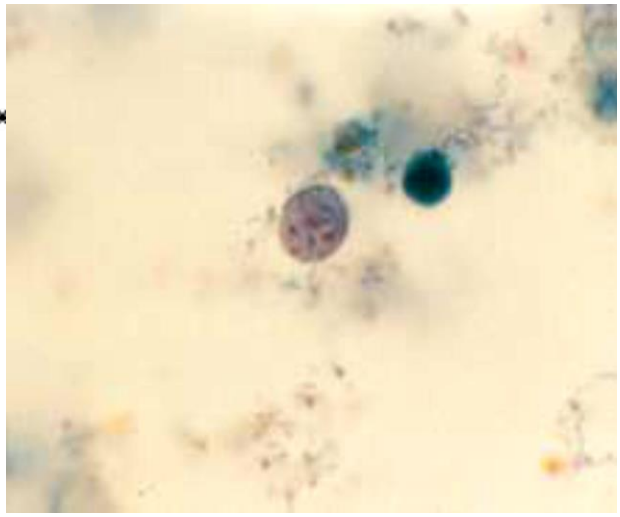

Cyst stage of *E. nana*

Lab: 4

Kingdom : Protista
Phylum : Sarcomastigophora
Class : Zoomastigophora
Geneus : 1. *Giardia intestinalis* (*Giardia lamblia*)
: 2. *Chilomastix mesnili*
: 3. *Trichomonas spp.*

1. Giardia lamblia:

- **Habitat** : Small intestine (duodenum and jejunum)
- **Disease** : **Giardiasis**
- **Stages** : Trophozoite, cyst **.**
- **Infective stage** : Cyst
- **Diagnostic stage** : Motile trophozoite , cyst stage
- **Mode of transmission**: by ingestion of **cysts** in contaminated water and food

Morphology:

Characteries	Trophozoite	Cyst
Size range	8-20 µm long , 5-16 µm wide	8-17 µm long , 6-10 µm wide
Shape	Pear-shaped, teardrop Bilaterally symmetrical	Ovoid
Motility	Falling leaf	Non- motility
Number of nuclei	Two ovoid-shaped,	Immature cyst, two Mature cyst, four
Karyosome	large karyosome	Central karyosomes
Periphral chromatin	Absent	Absent
Flagella	Four pairs, origination of each: One pair, anterior end	Absent
Other structures	One pair, posterior end ,Two pair, central, extending laterally Two median bodies Two axonemes Sucking disk	Median bodies:two in immature cyst or four in fully mature cyst Interior flagellar structures*

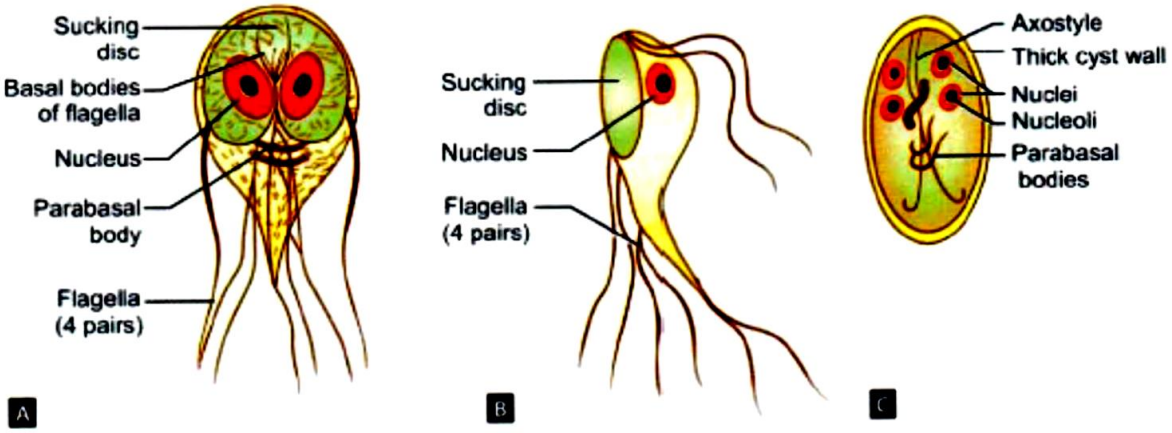

(A) Trophozoite. (B) Ventral view; Lateral view: and (C) Quadrinucleate cyst

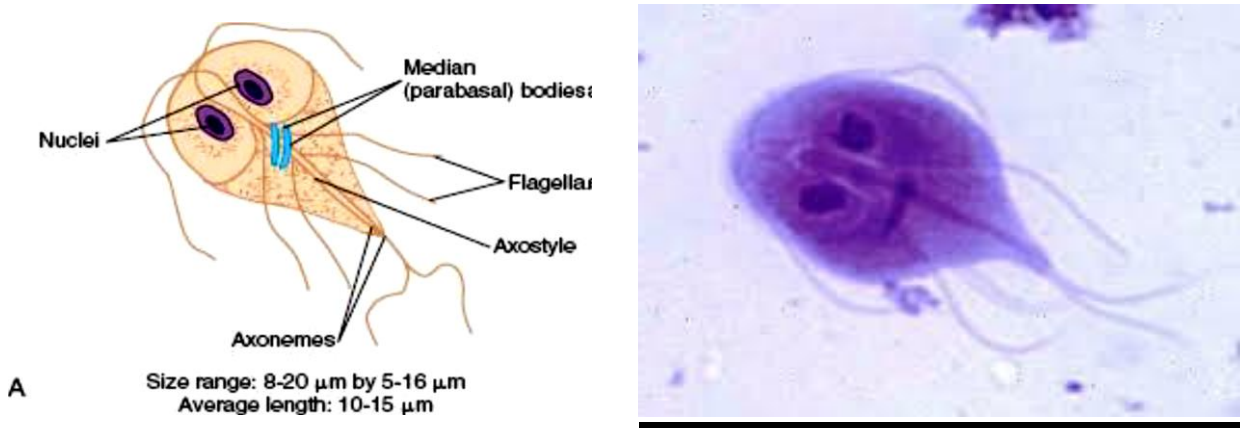

***Giardia intestinalis* trophozoite**

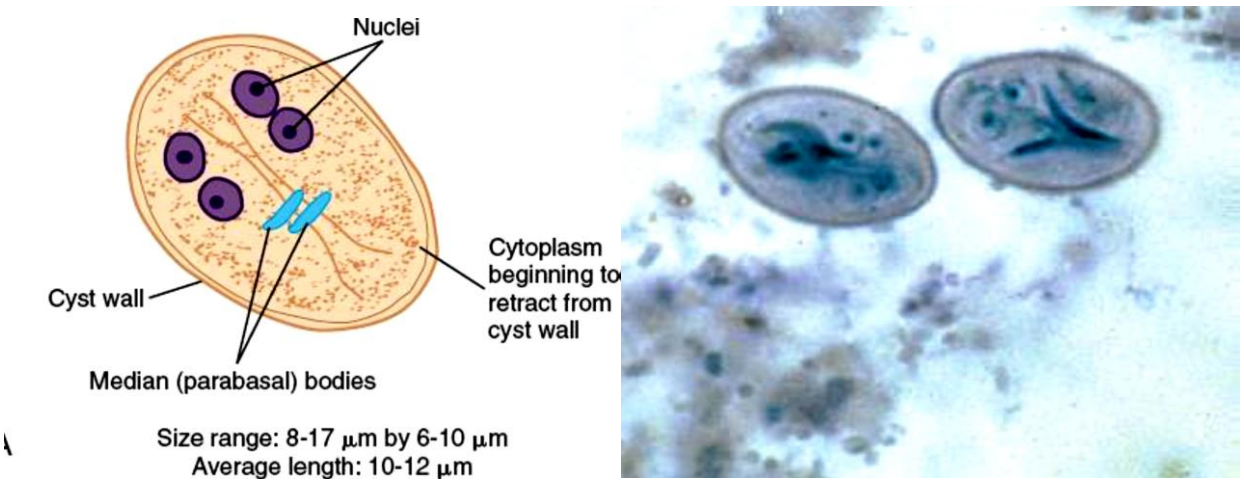

***Giardia intestinalis* cyst**

Laboratory Diagnosis:

1-Stool Examination: Giardiasis can be diagnosed by identification of **cysts** of *Giardia lamblia* in the formed **stools** and the **trophozoites and cysts** of the parasite in **diarrheal stools** by **saline** and **iodine** wet preparations..

• On macroscopic examination, fecal specimens containing G. *lamblia* may have an **offensive odor, are pale colored and fatty, and float in water.**
2-Enterotest (String Test) .

3- Examination **of Duodenal contents** by **aspiration and Biopsies from upper small intestine**.

4- **Fecal antigen detection** by enzyme immunoassays(EIA) and enzyme-linked immunosorbent assay(ELISA)

5-Molecular Method: by using **PCR.** Technique.

2. Chilomastix mesnili

General Properties :

- **Habitat :** Small intestine and large intestine (cecum and/or colon)
- **Disease : considered a nonpathogen**
- **Stages : Trophozoite, cyst .**
- **Infective stage : Cyst**
- **Diagnostic stage :** Trophozoite , Cyst stage .
- **Reproduction :** Asexually reproduction by Binary fission

- ***Morphology***

Characteries	Trophozoite	Cyst
Size range	5-25 µm long ,5-10 µm wide	5-10 µm long ,
Shape	Pear-shaped	Lemon-shaped, with a clear hyaline knob extending from the anterior end
Motility	Stiff, rotary, directional	Non- motility
Number of nuclei	One with small central or eccentric karyosome No peripheral chromatin	One, with large central karyosome No peripheral chromatin
Karyosome	large karyosome	Central karyosomes
Periphral chromatin	Absent	Absent
Flagella	Four:Three extending from anterior end One extending posteriorly from cytostome region	Absent

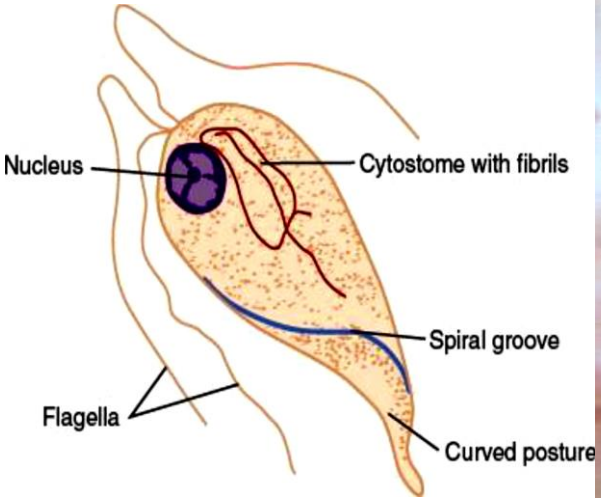

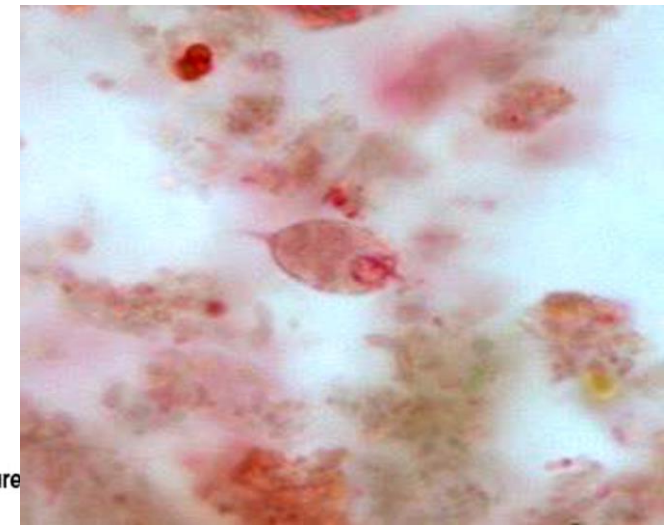

***Chilomastix mesnili* trophozoite.**

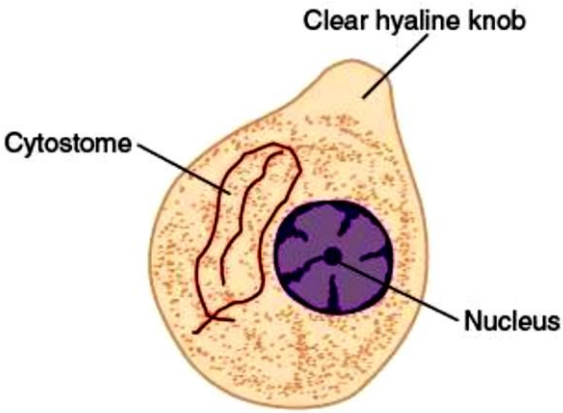

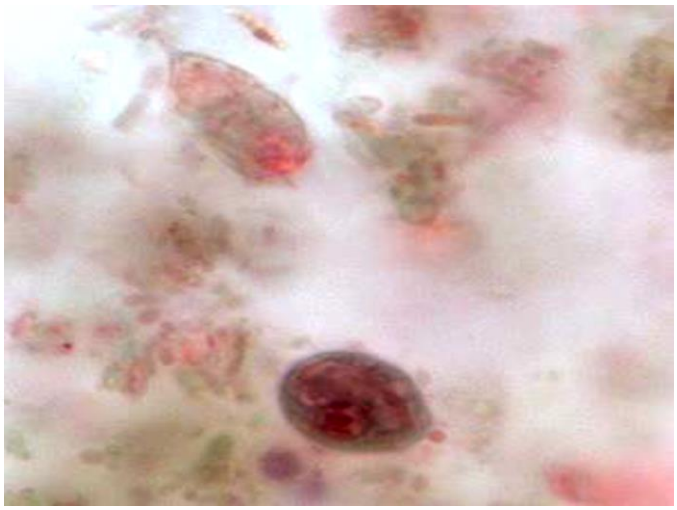

***Chilomastix mesnili* cyst**

Laboratory Diagnosis:

- Examination of **liquid stools** from patients infected with C. mesnili typically reveals **only trophozoites**.
- **Formed stool** samples from these patients usually reveal **only cysts**.
- Samples of **semiformed** consistency may contain **trophozoites and cysts**.

3.Trichomonas vaginalis

- **Disease**: Vaginitis
- **Habitat** : vagina , urethra , prostate
- **Infective stage**: Trophozoit**e**
- **Mode of transmission** : sexual intercourse& contaminated clothes
- **Trophozoit:** pear or oval shape , one nucleus , 4 free anterior flagellates , fifth backward with undulating membrane , Axostyle
- **Definitive host**: Human

- **Diagnosis:**

1-Direct smear in general urine examination
2- vaginal discharge examination.
3- urethra and seminal fluid examination.

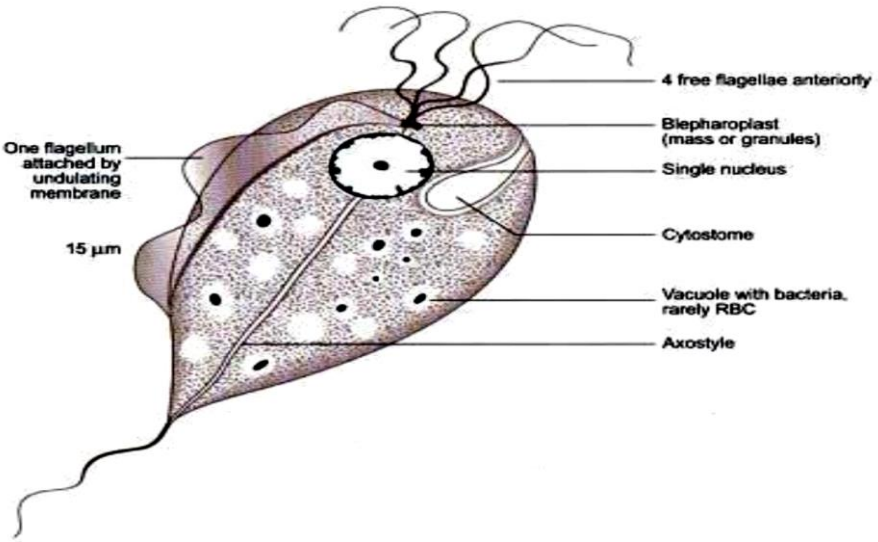

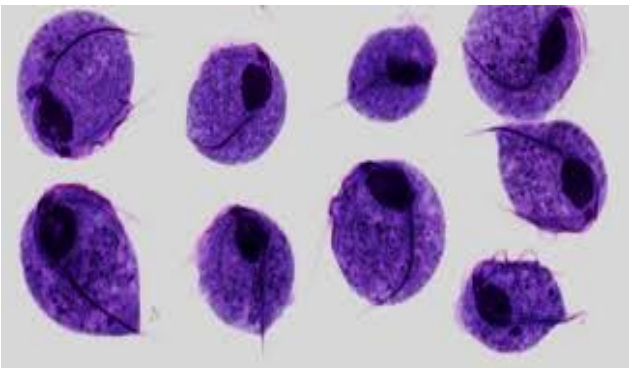

Trichomonas vaginalis –Trophozoite

• *Trichomonas hominis:*

- **Disease**: Non- pathogenic
- **Habitat** : Large intestine may seen in small intestine
- **Infective stage**: Trophozoite
- **Mode of transmission**: ingestion of contaminated food or water
- **Trophozoit:** pear shape , one nucleus , 3-5 flagellates , one flagellum united with the parasite body forming undulating membrane , Axostyle
- **Definitive host**: Human
- **Diagnosis**: Direct smear of stool examination
- **Trichomonas vaginalis –Trophozoite**

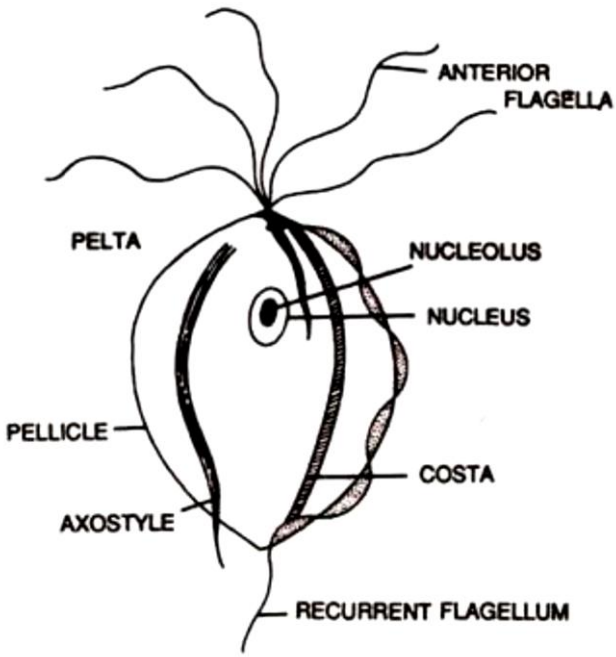

Fig. 8.2 Trichomonas hominis

• *Trichomonas tenax*

- **Disease**: cause disease of gum
- **Habitat** : mouth
- **Infective stage**: Trophozoit
- **Mode of transmission** : contamination of dental equipments
- **Trophozoit:** pear or oval shape , one nucleus , 4 free anterior flagellates , fifth backward with undulating membrane , Axostyle
- **Definitive host**: Human
- **Diagnosis**: Swab from mouth.

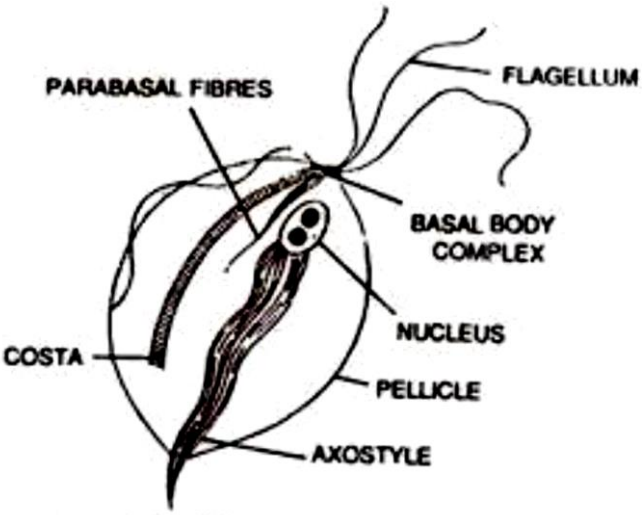

Fig. 8.3 Trichomonas tenax

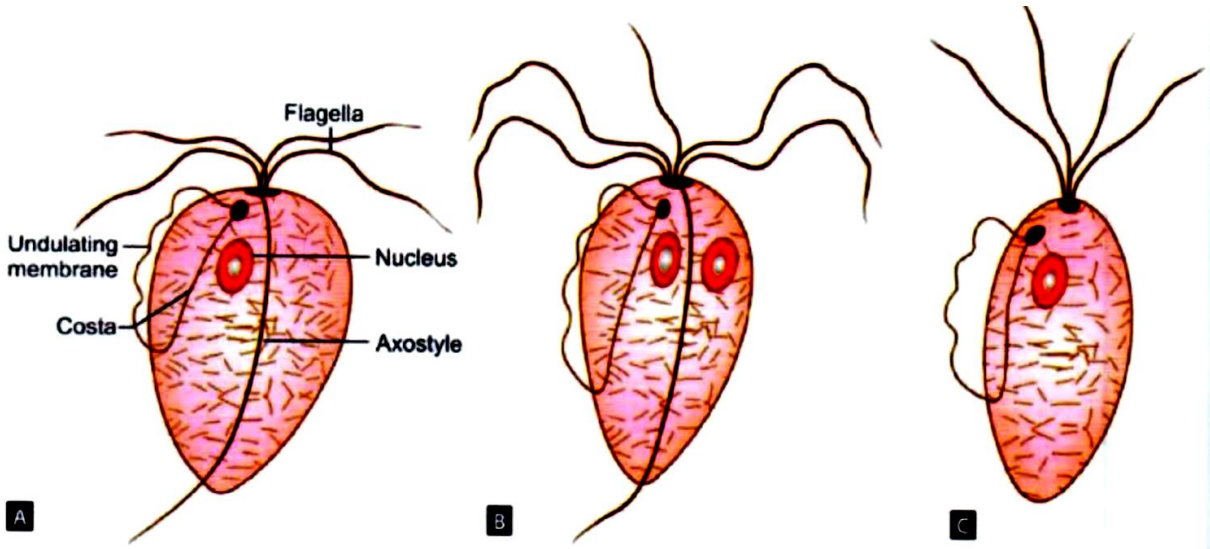

Trichomonas* species. (A) *T. vaginalis;* (B) *T. hominis;* and (C) *T. tenax

Lab: 5

Hemoflagellates (blood and tissue flagellates protozoa)

It is called **Hemoflagellates** because they have a **flagellum** and require **blood medium** to culture them. It is included ***Trypanosoma spp.*** *and* ***Leishmania spp***.

Life cycle**: Indirect life cycle** need two hosts:
Definitive Host - Humans and their domestics .
Intermediate Host - Insect vectors .

***Morphological forms of hemoflagellates:**
1-Amastigote Form
2-Promastigote Form
3-Epimasigote Form
4-Trypomastigote Form.

Different stages of Haemoflagellates

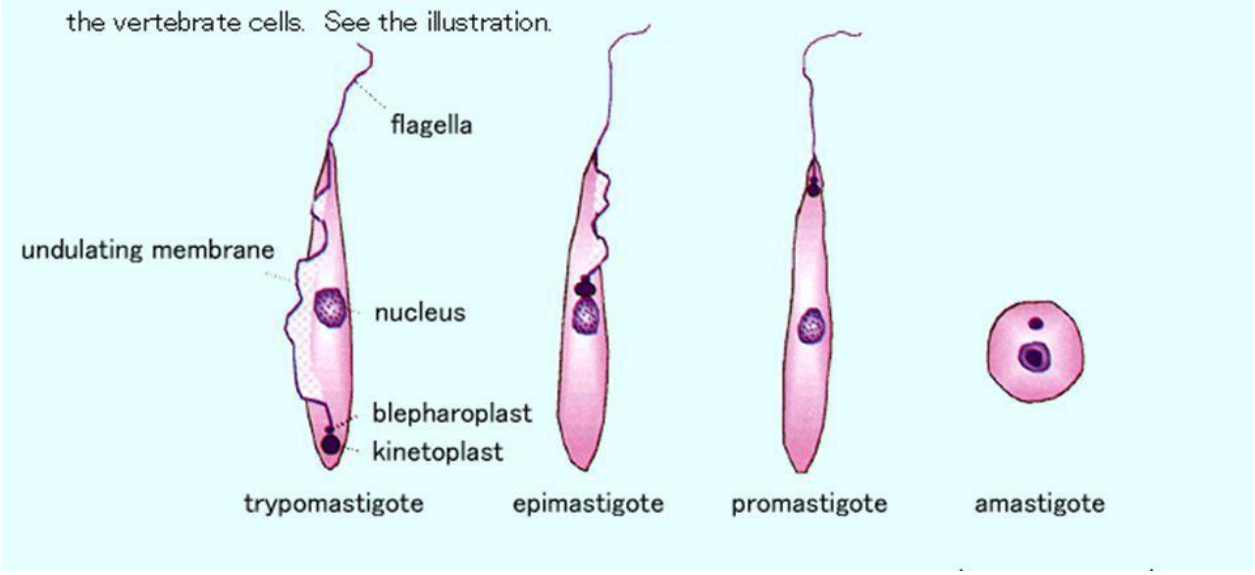

1-Amastigote (Leishmania) form:
Round or oval in shape, 2-5 microns in diameter, no free flagellum,
No undulating membrane, The only intracellular forms of all Leishmania species and *Trypanosome cruzi*



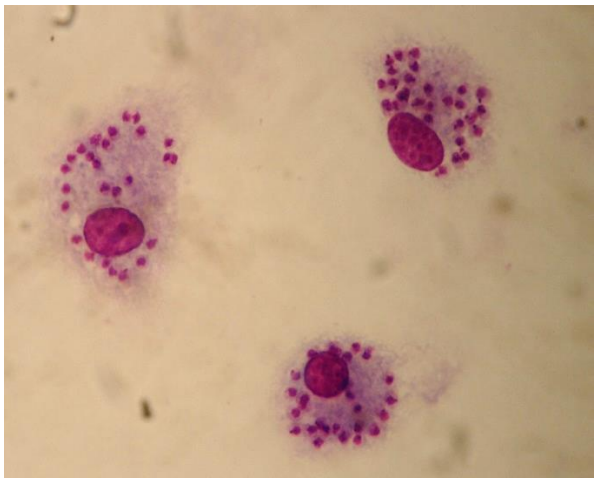

2-Promastigote (leptomonad) form:
Elongated (spindle in shape), have centrally located nucleus and the kinetoplast situated at the anterior end. From blepharoplast, **single free flagellum** projects from the anterior end, **equal or longer** than the body length. This form has **no undulating membrane.**

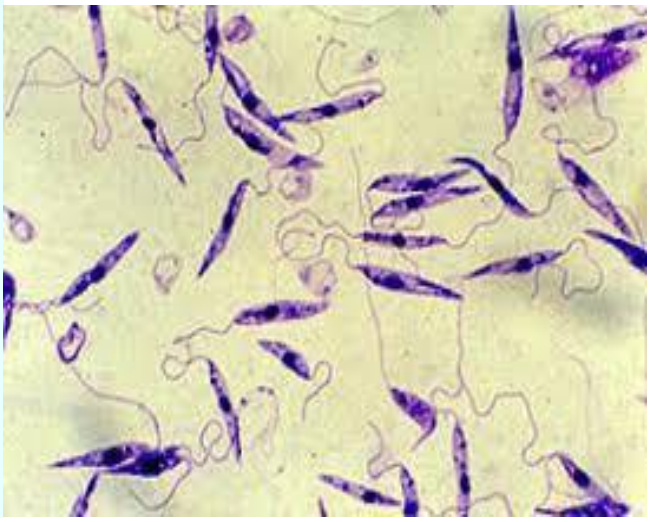

3-Epimastigote (crithidia) form:
Elongated form, slightly wider than promastigote, single free flagellum, single nucleus , undulating membrane, the kinetoplast is just anterior to the nucleus. It is found in the invertebrate host and in culture media (of Trypanosome species).

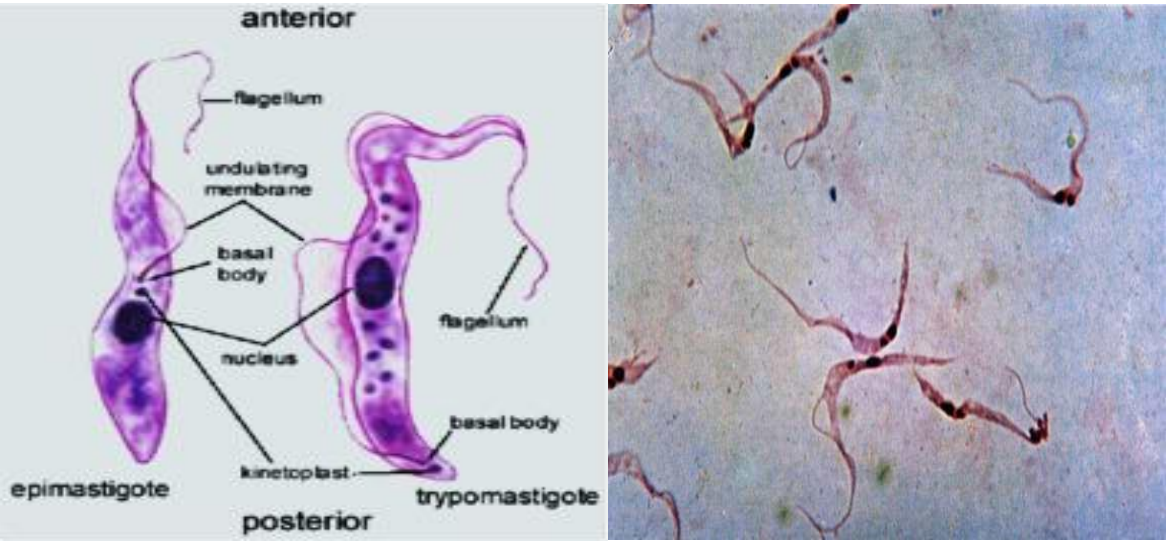

4-Trypomastigote (Trypanosome) form:

Elongated form with highly polymorphism from rather short and stumpy to a long slender from. In stained blood film, *Trypanosoma cruzi* appears as C or U shape, single free flagellum, single Nucleus , presence of undulating membrane . The kinetoplast and axonemes are found at the posterior end relative to the nucleus.This form is found in the peripheral blood of vertebrates and is the diagnostic stage of *Trypanosoma* species.

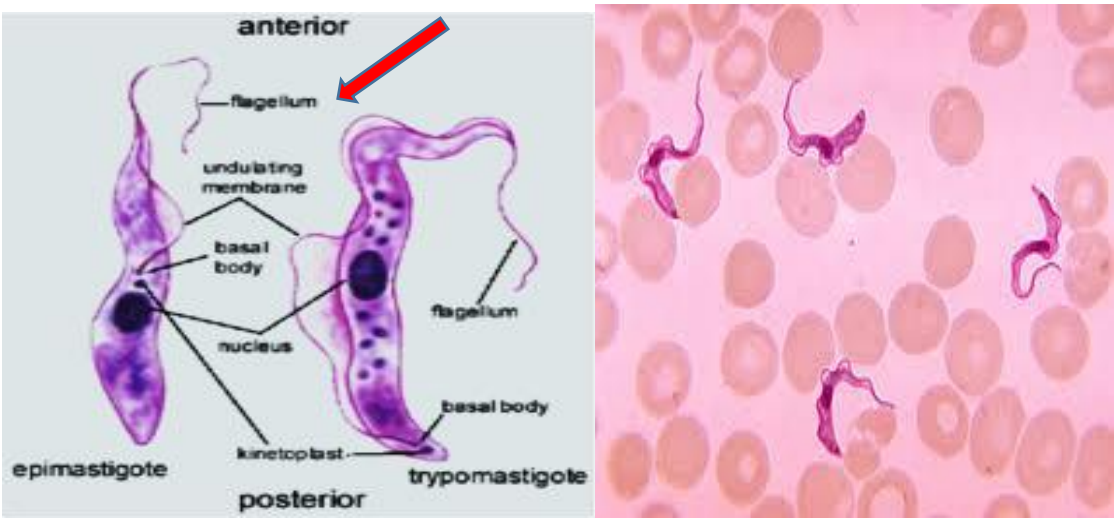

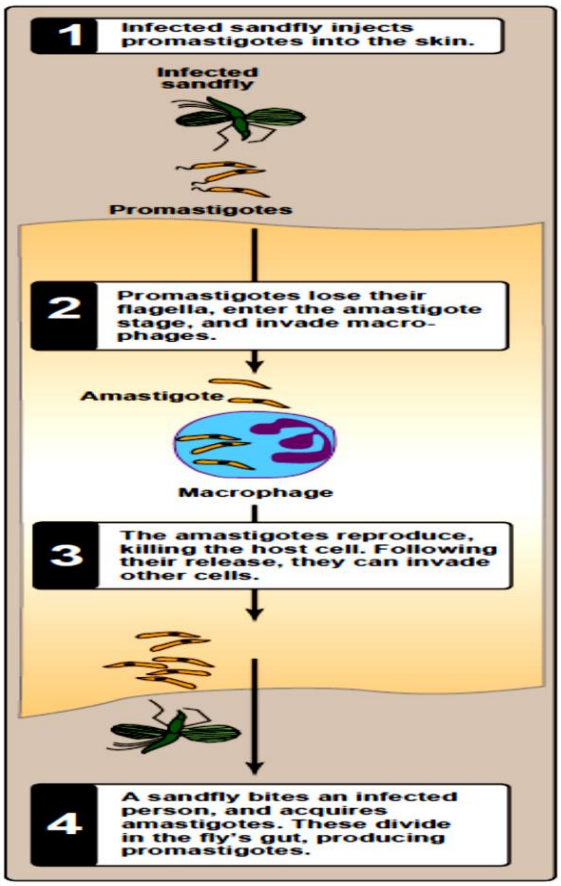

- ***Leishmania spp:***

There are three clinical types of leishmaniasis:
1-Cutaneous
2- Mucocutaneous
3-Visceral

1- Leishmania tropica:

Disease: Cutaneous leishmaniasis , oriental sore , Baghdad boil, Delhi boil
Habitat: skin
Morphology: Amastigote , promastigote
Infective stage: Promastigote
Vector (intermediate host) : Sand fly
Mode of transmission: by biting of sand fly
Diagnosis:

- Smear : Giemsa stain- microscopy examination for (amastigote) from infected tissue samples taken from the edges of lesions or lymph node aspirates.
- Biobsy: microscopy for (promastigote).

2- Leishmania donovani:

Disease: Viseral leishmaniasis , Kala-azar disease.
Habitat: liver , spleen , bone marrow
Morphology: Amastigote , promastigote
Infective stage: Promastigote
Vector: Sand fly
Mode of transmission: by biting of sand fly
Diagnosis:

- Microscopy , Culture in **NNN** medium or Schneider's Drosophila medium
- Serodiagnosis (IFAT , ELISA , DAT).
-

3- Leishmania braziliensis:

Disease: Mucocutaneous leishmaniasis , Espundia
Habitat: Nasopharyngeal, mucosa membrane
Morphology: Amastigote , promastigote
Infective stage: Promastigote
Vector: Sand fly
Mode of transmission: by biting of sand fly
Diagnosis: Microscopy (finding the organism in a histological section of the lesion provides defeninitive diagnosis of Mucocutaneous leishmaniasis.

Lab 6

- **Trypanosoma:**

1. **Trypanosoma *bruci*** involves two species:
   - **Trypanosoma gambiense.**
   - **Trypanosoma rhodesiense**

2. **Trypanosoma *cruzi***

1- Trypanosoma *bruci*

Disease: sleeping sickness African trypanosomiasis
Habitat: liver , spleen , CNS
Morphology: Amastigote , promastigote , epimastigote , trypomastigote
Infective stage: Trypomastigote
Vector: Tsetse fly
Mode of transmission: by biting of Tsetse fly
Diagnosis: Blood film ,wet mount stained smear of C.S.F. (snake-like motion) IFAT , PCR

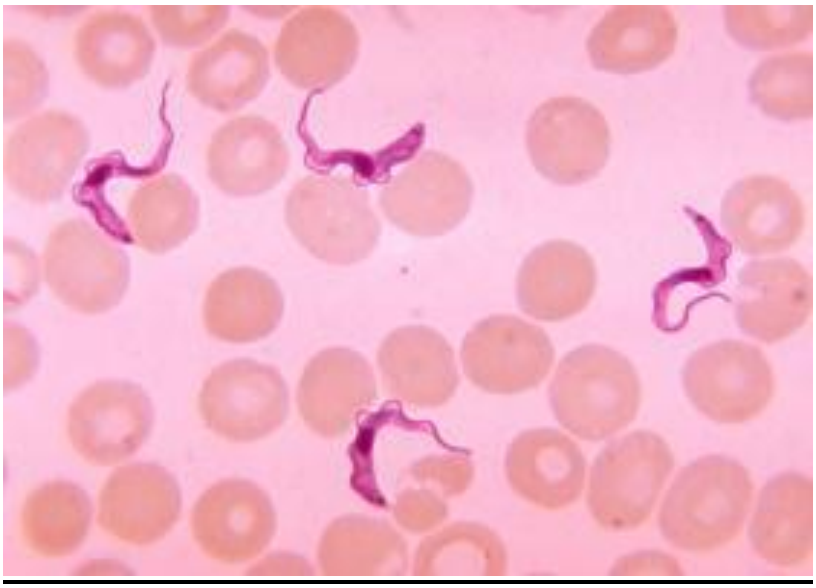

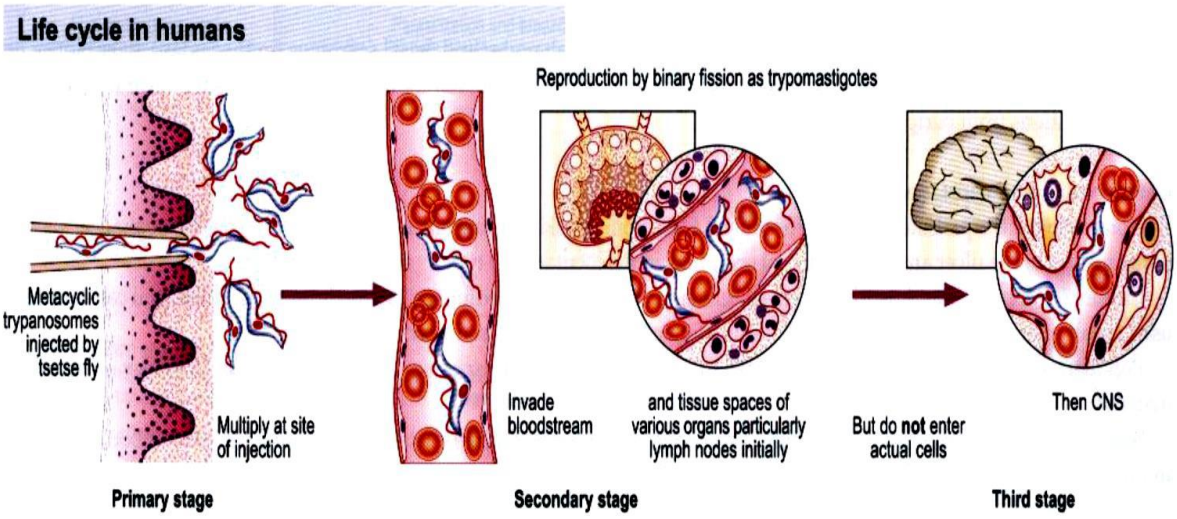

2- Trypanosoma *cruzi:*

Disease: chagas disease ,south American trypanosomiasis
Habitat: blood , RBC , heart , muscle
Morphology: Amastigote , promastigote , epimastigote , trypomastigote
Infective stage: Trypomastigote
Vector: Reduviid bug
Mode of transmission: by biting of Reduviid bug **Diagnosis**: Blood film (snake-like motion against red blood cells (RBCs), IFAT , PCR, Xenodiagnosis.

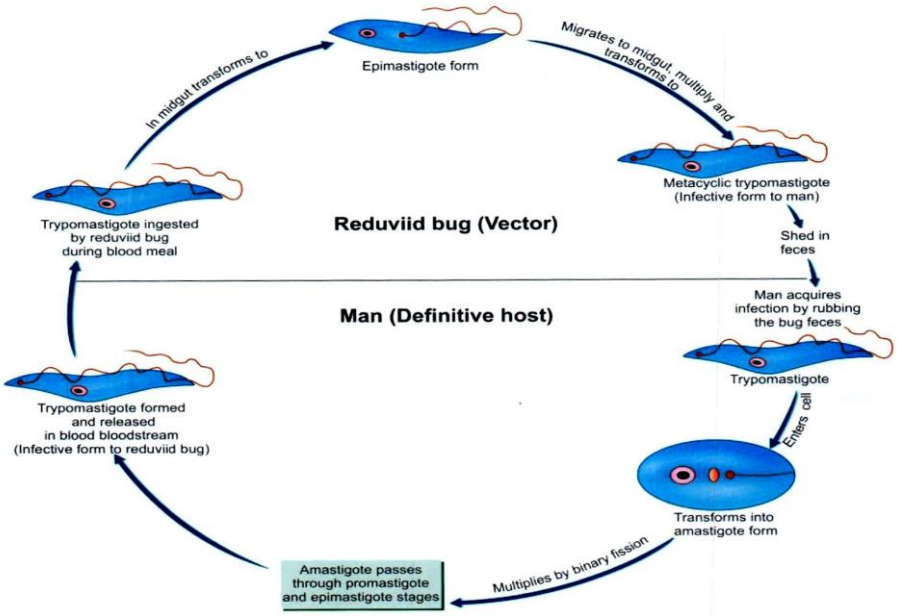


T. cruzi causes cutaneous stage (chagoma)


Ocular lesion (Romana sign)

Lab -7

- **Ciliates:** are a group of protozoans characterized by the presence of hair-like organelles on the surface of their membranes called **cilia** that are used for **locomotion**.

Kingdom : Animalia

Phylum : Protozoa

Subphylum : Ciliophora

Class : Ciliates

Genus : ***Balantidium coli***

- ***Balantidium coli*** **(Intestinal species):**

Balantidium coli considered as the **large protozoan parasite** known to humans. It is causes the disease **Balantidiasis** . It is the only member of the ciliate phylum known to be pathogenic parasitize to humans.

- **Habitat** : large intestine (cecum).
- **Life cycle** : Direct.
- **Disease :** Zoonotic intestinal disease Balantidiasis
- **Stages**: Trophozoite, cyst .
- **Definitive host**: human, **swine,** horses, ...
- **Locomotion**: cilia
- **Infective stage** : cyst
- **Diagnostic stage** : Both cyst and trophozoite
- **mechanism of transmission**: by contaminated water (most important) and food.

The life cycle of this parasite consist of **two stages:**

A- **Trophozoite stage**: The typical characteristics of this stage are:
1- **Ovoid to sac-shaped** tapers at the anterior end.
2- Cytoplasm is **granular** and have **two nuclei**:

- Micronucleus (small spherical-shaped)

• Macronucleus (kidney-shaped)

3- Having one to two contractile vacuoles in the granular cytoplasm and food vacuoles (ingested microbes " bacteria ").
4- There is **cytosome** in the anterior end (mouth like structure).
5- A large of cilia surrounded the organism and one protective wall surrounded the organism.
6- • The B. coli trophozoite is often referred to as resembling a sac in its shape. As of this shape, the organism was named *Balantidium*, which means " **little bag** ".

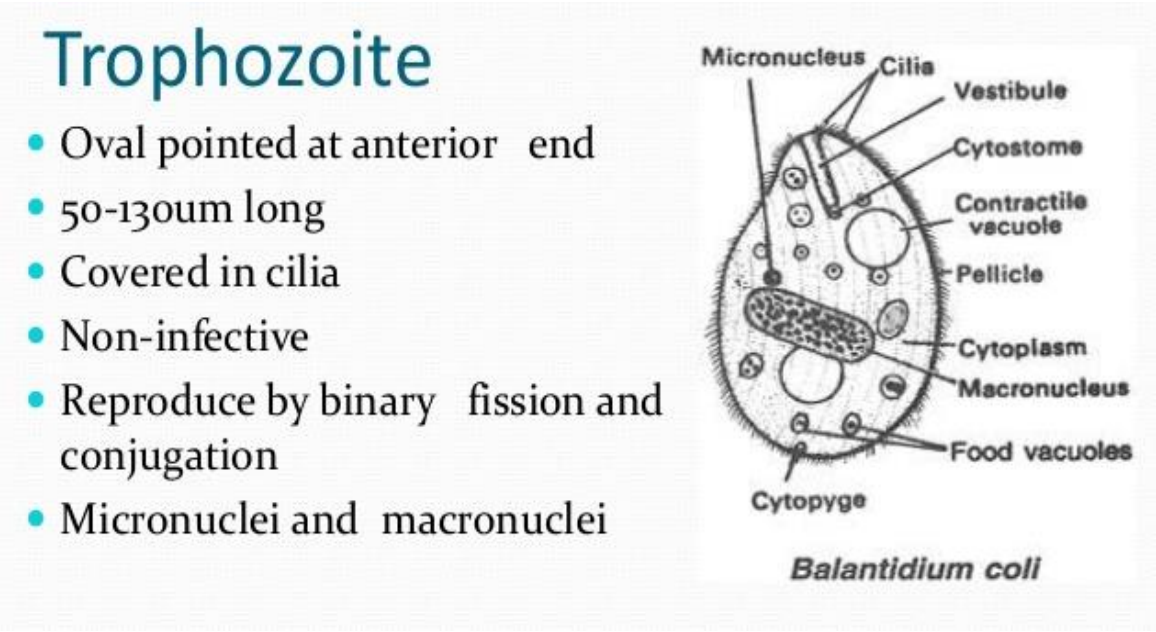


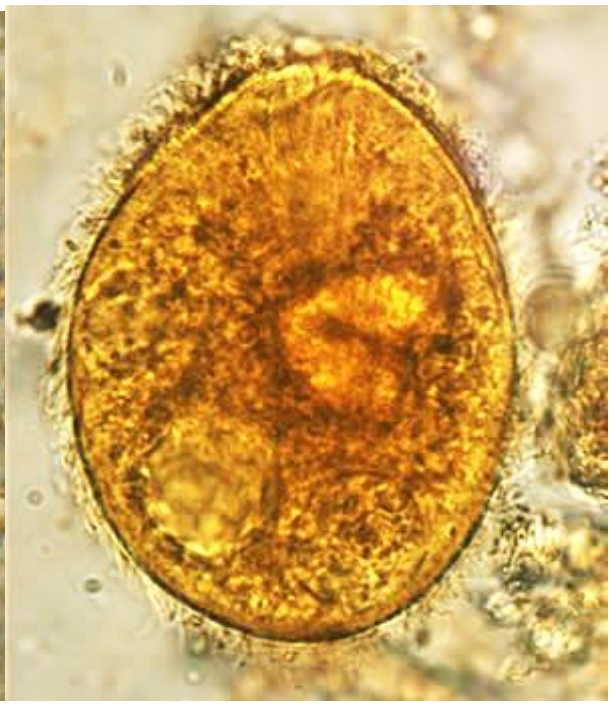

B- **Cyst stage** : The typical characteristics of this stage are :

1- Sub-spherical to oval-shaped .
2- Cytoplasm is granular and have two nuclei :
   - Micronucleus (small spherical-shaped)
   - Macronucleus (kidney-shaped)
3- Having one to two contractile vacuoles in young cyst but does not have food vacuoles .
4- Doesn't have cytosome .
5- Double – protective cyst wall surrounded the organism and arrow of cilia visible in between the two cyst wall layers of cyst .

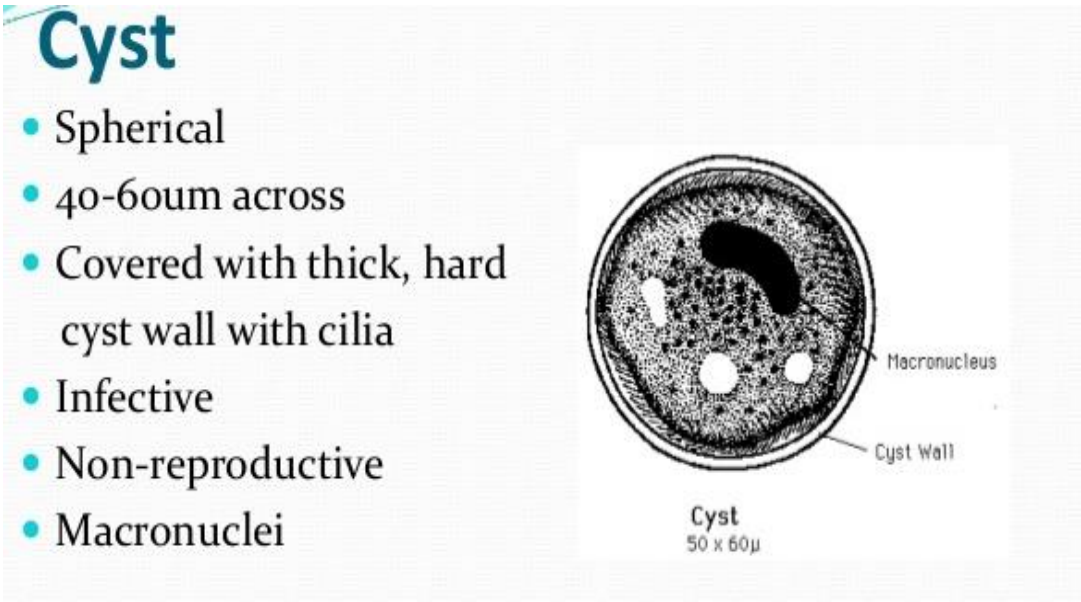

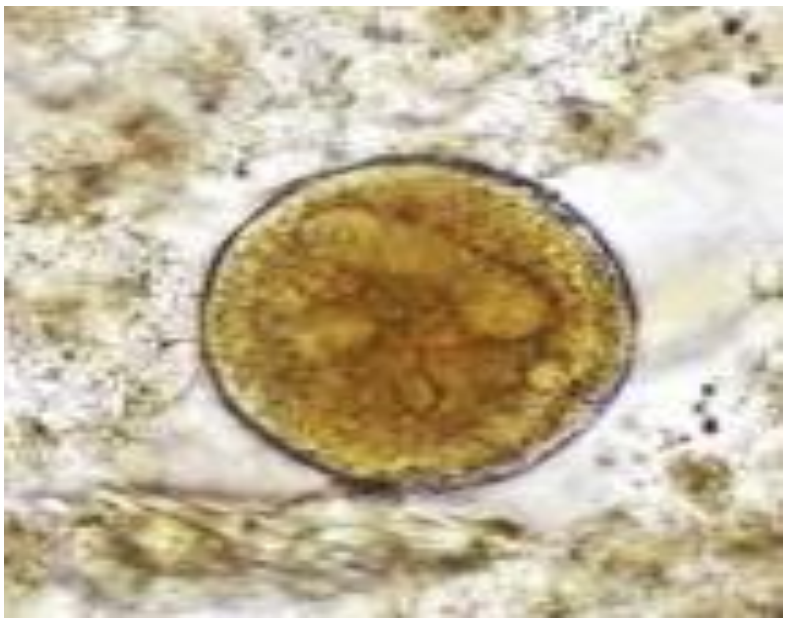

Diagnosis:

1- Clinical symptoms

Blantidiasis may be resemble amebic dysentery . Acute infections are characterized by up to **15 liquid stools per day containing pus** , **mucus and blood** . Patients who suffer from chronic infection may develop a tender colon , anemia , chachexia and occasional diarrhea .

2- Laboratory Diagnosis

By examining stool samples for the presence of trophozoites and cysts.

Lab - 8

Sporozoa

Phylum : Apicomplexa.

Class : Coccidia.

Order : Eucoccidia.

Genus : Plasmodium.

1. Plasmodium vivax

General Properties :

- **Habitat :** Young and immature Red blood corpuscles (R.B.Cs)
- **Appearance of infected RBCs :** Enlarged, distorted
- **Disease :** Benign tertian malaria, vivax malaria.
- **Vector :** Female of Anopheles Mosquito .
- **Human Stages :** Ring form
  Developing trophozoite
  Immature schizont
  Mature schizont
  Merozoites
  Microgametocyte
  Macrogametocyte
- **Mosquito Stages :** Zygotes, Ookinete ,Oocyst , Sporozotes**.**
- **Infective stage :** Sporozotes .
- **Diagnostic stage :** all human stage .

Morphology

Morphologic Form	Typical Characteristics
Ring form	Delicate cytoplasmic ring measuring one third of RBC diameter , Single chromatin dot Ring surrounds a vacuole ,
Developing trophozoite	Irregular ameboid appearance , Ring remnants common , Brown pigment becomes apparent, increases in number and visibility as parasites mature
Immature schizont	Multiple chromatin bodies ,Often contains clumps of brown pigment
Mature schizont	12 to 24 merozoites occupy most of infected red blood cell , Merozoites surrounded by cytoplasmic material , Brown pigment may be present
Microgametocyte	Large pink to purple chromatin mass surrounded by colorless to pale halo Brown pigment common
Macrogametocyte	Round to oval cytoplasm , Eccentric chromatin mass , Delicate light-brown pigment may be visible throughout cell

2. *Plasmodium ovale*

General Properties :

- **Habitat :** Only young and immature cells .
- **Appearance of infected RBCs :** Oval and enlarged, distorted with ragged cell walls.
- **Disease :** Benign tertian malaria, ovale malaria.
- **Vector :** Female of Anopheles Mosquito .
- **Human Stages :** Ring form.

Developing trophozoite

Immature schizont

Mature schizont

Merozoites

Microgametocyte

Macrogametocyte

- **Mosquito Stages :** Zygotes, Ookinete ,Oocyst , Sporozotes**.**
- **Infective stage :** Sporozotes .
- **Diagnostic stage :** all human stage .

Morphology

Morphologic Form	Typical Characteristics
Ring form	Resembles that of P. vivax Ring larger in size than P. vivax Ring thick and often somewhat ameboid in appearance
Developing trophozoite	Ring appearance usually maintained until late in development Ameboid tendencies not as evident as in P. vivax .
Immature schizont	Progressive dividing chromatin surrounded by cytoplasmic material—often maintains circular shape early in development
Mature schizont	Parasites occupy 75% of RBCs. Rosette arrangement of merozoites (average of eight merozoites typically present)
Microgametocyte	Large pink to purple chromatin mass surrounded by colorless to pale halo Brown pigment common smaller in size *P. vivax*,

Macrogametocyte	**Round to oval cytoplasm , Eccentric chromatin mass , Delicate light-brown pigment may be visible throughout cell smaller in size than *P. vivax*,**

3. *Plasmodium malariae*

General Properties :

- **Habitat :** Only mature cells
- **Appearance of infected RBCs :** Typical Characteristics (Based on Giemsa Stain)
- **Disease :** Quartan malaria, malarial malaria.
- **Vector :** Female of Anopheles Mosquito.
- **Human Stages :** Ring form
  Developing trophozoite
  Immature schizont
  Mature schizont
  Merozoites
  Microgametocyte
  Macrogametocyte
- **Mosquito Stages :** Zygotes, Ookinete ,Oocyst , Sporozotes**.**
- **Infective stage :** Sporozotes .
- **Diagnostic stage :** all human stage .

Morphology

Morphologic Form	Typical Characteristics
Ring form	Smaller than P. vivax , Occupies one sixth of the RBC Heavy chromatin dot , Vacuole may appear filled in Pigment characteristically forms early
Developing trophozoite	Nonameboid solid cytoplasm that may assume roundish, oval, band, or bar shape Cytoplasm contains coarse dark brown pigment; may mask chromatin material Vacuoles absent in mature stages
Immature schizont	Similar to that of P. vivax, only smaller; may contain large and dark peripheral or central granules .
Mature schizont	Typically contains 6 to 12 merozoites arranged in rosettes or irregular clusters Central arrangement of brown-green pigment may be visible Infected RBC may not be seen because developing parasites often fill the cell completely.
Microgametocyte & Macrogametocyte	Similar to P. vivax, only smaller in size; pigment usually darker and coarser Older forms assume an oval shape.

General Properties :

- **Habitat :** May infect cells of all ages
- **Appearance of infected RBCs :** Normal size, no distortion
- **Disease :** Black water fever, malignant tertian malaria, aestivoautumnal malaria, subtertian malaria, falciparum malaria.
- **Vector :** Female of Anopheles Mosquito .
- **Human Stages :** Ring form
  Developing trophozoite

Immature schizont

Mature schizont

Merozoites

Microgametocyte

Macrogametocyte

4. *Plasmodium falciparum*

- **Mosquito Stages :** Zygotes, Ookinete ,Oocyst , Sporozotes.
- **Infective stage :** Sporozotes .
- **Diagnostic stage :** all human stage .

Morphology

Morphologic Form	Typical Characteristics
Ring form	Circle configuration (one chromatin dot) or headphone configuration (two chromatin dots) Scanty cytoplasm , Small vacuole usually visible Multiple rings common , Accolé forms possible
Developing trophozoite	Heavy rings common Fine pigment granules Mature forms only seen in severe infections
Immature schizont	Multiple chromatin bodies surrounded by cytoplasm Only detected in severe infections

Mature schizont	Typically consists of 8-36 ,merozoites (average, 24) in cluster arrangement Only detected in severe infections
Microgametocyte	Sausage- or crescent-shaped Dispersed central chromatin with nearby black pigment usually visible
Macrogametocyte	Sausage- or crescent-shaped Compact chromatin Black pigment surrounding chromatin may be visible

Laboratory Diagnosis

1- **Thick and thin blood films :** All developmental stages of parasites may be seen in blood film stained with **Giemsa s**tain.

2- **Serological tests** : Among the tests used are :

a) Indirect fluorescent antibody test (IFAT),

b) Indirect hemagglutination antibody (IHA) test,

c) Enzyme-linked immunosorbent assay (ELISA).

3) **Dipstick tests:** based on the detection of parasite lactate dehydrogenase are now available.

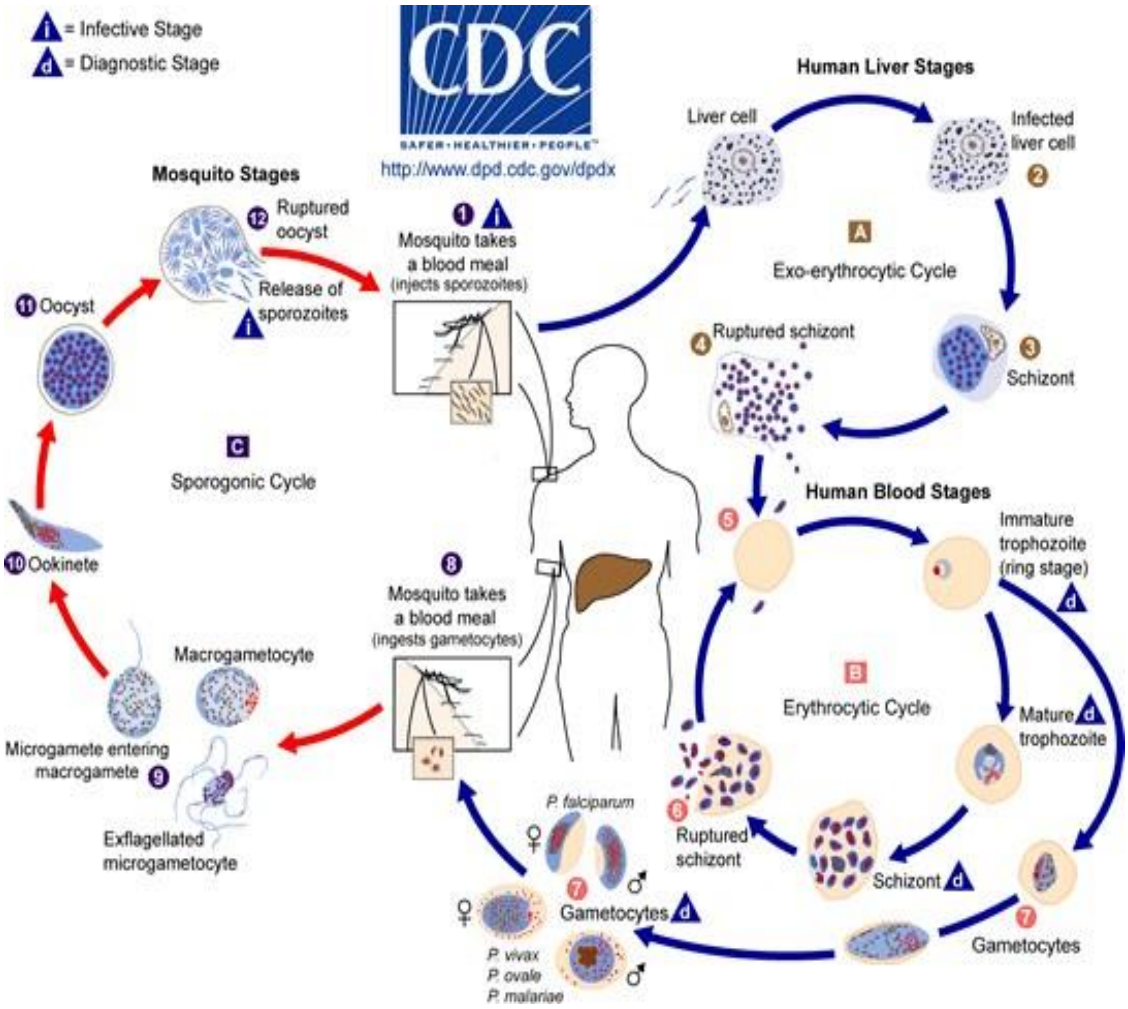
= Infective Stage
= Diagnostic Stage
CDC
SAFER • HEALTHIER • PEOPLE
http://www.dpd.cdc.gov/dpdx
Human Liver Stages
Liver cell
Infected liver cell
Exo-erythrocytic Cycle
Ruptured schizont
Schizont
Mosquito Stages
Ruptured oocyst
Release of sporozoites
Oocyst
Mosquito takes a blood meal (injects sporozoites)
Sporogonic Cycle
Ookinete
Mosquito takes a blood meal (ingests gametocytes)
Macrogametocyte
Microgamete entering macrogamete
Exflagellated microgametocyte
Human Blood Stages
Immature trophozoite (ring stage)
Mature trophozoite
Erythrocytic Cycle
Ruptured schizont
Schizont
Gametocytes
P. falciparum
P. vivax
P. ovale
P. malariae

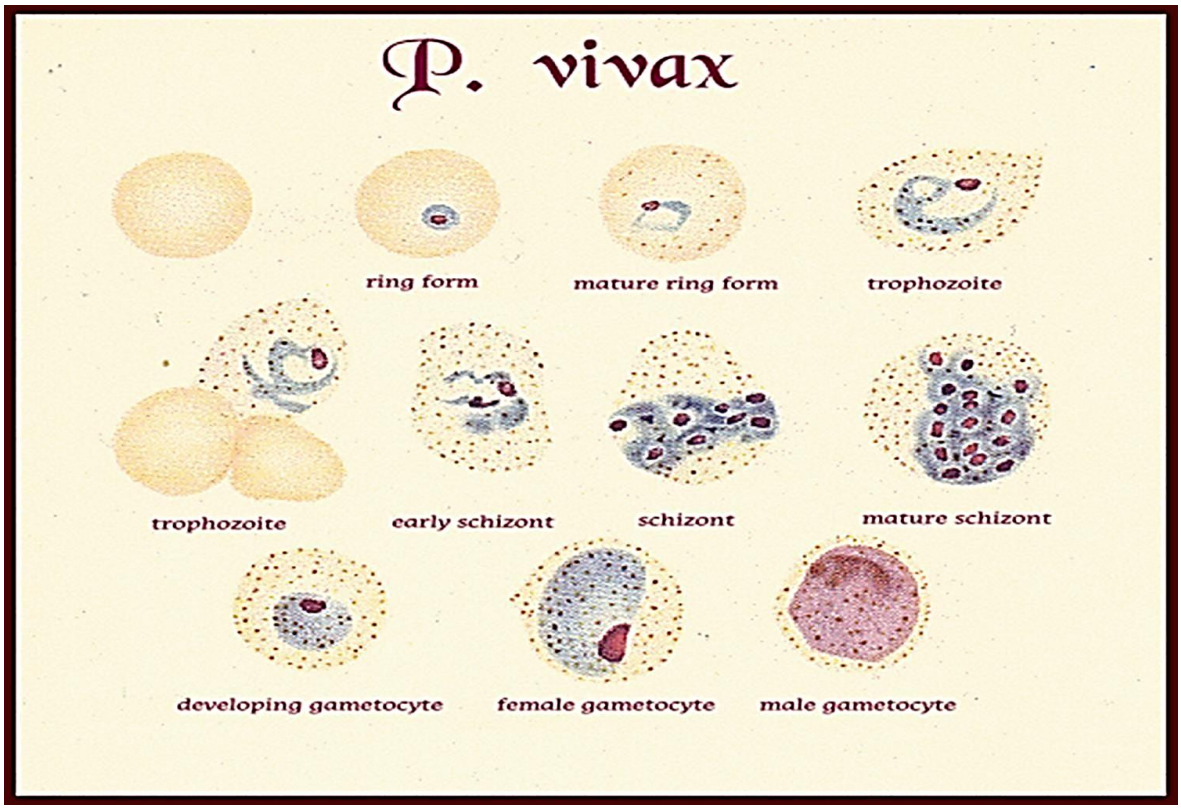
P. vivax
ring form
mature ring form
trophozoite
trophozoite
early schizont
schizont
mature schizont
developing gametocyte
female gametocyte
male gametocyte

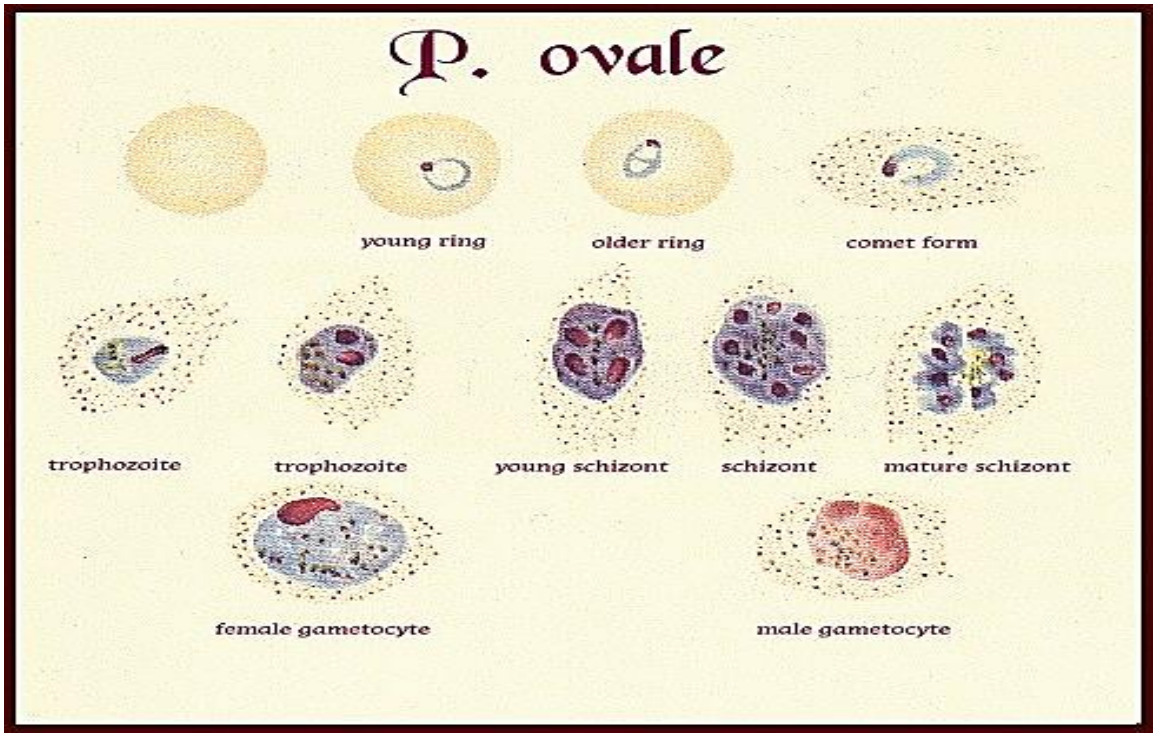
P. ovale
young ring
older ring
comet form
trophozoite
trophozoite
young schizont
schizont
mature schizont
female gametocyte
male gametocyte

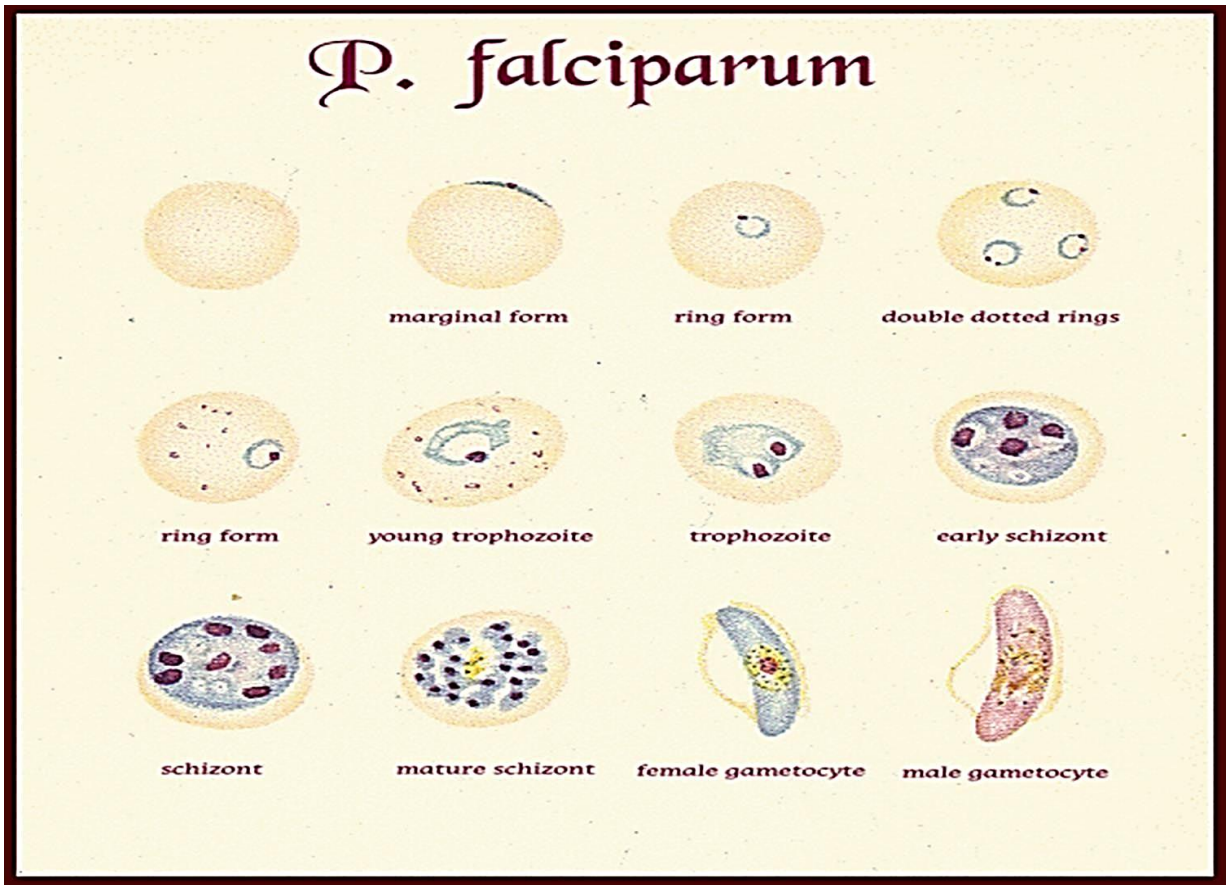
P. falciparum
marginal form
ring form
double dotted rings
ring form
young trophozoite
trophozoite
early schizont
schizont
mature schizont
female gametocyte
male gametocyte

Lab: 9 ……Helminthes

Helminthes

Helminthes are classified into :

A- **Platyhelminths Phylum (flat worms)** divided into two classes :
1- Cestodes class الشريطيات
2- Trematodes class المثقوبات

B- **Nemathelminthes Phylum (**Class **Nematoda or round worm)**

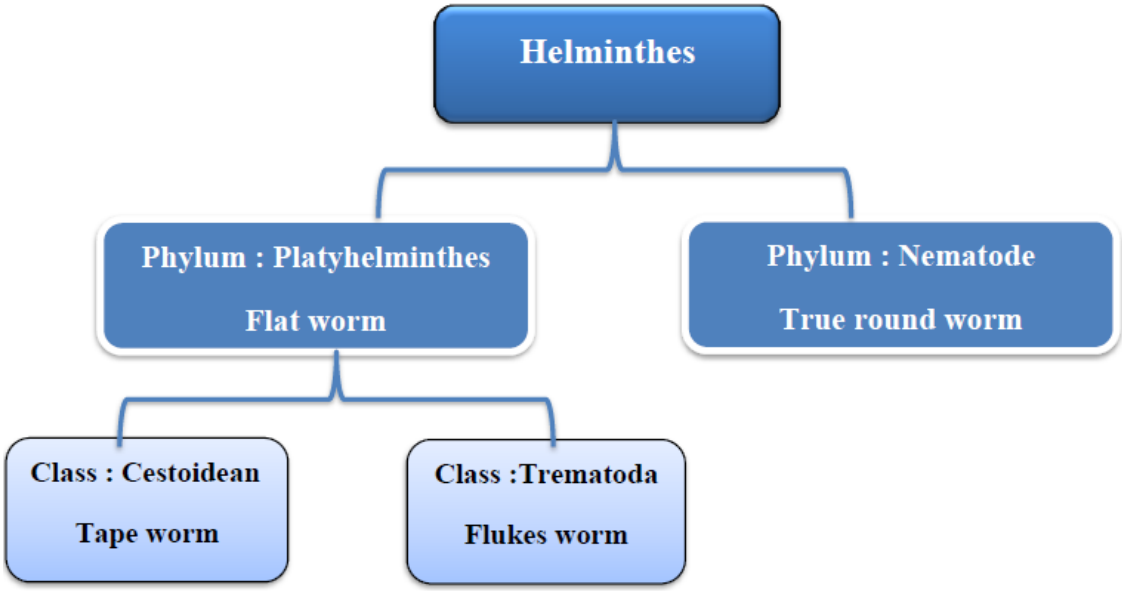

➢ Platyhelminths Phylum (flat worms)

➢ Cestode Morphology:

The body of cestoda called strobilla consist of 3 part :

1. Scolex(head): - All cestoda has scolex but different in shape for each worm and help attachment in host tissues and used in diagnosis.

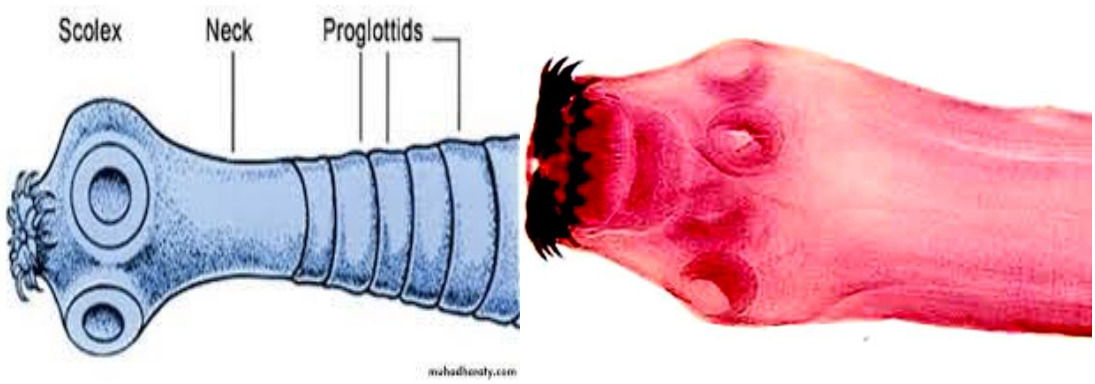

2. Neck: It is narrow and unsegmented , the segmentation or strobillization ocurrs in neck.
3. Proglottid (segments) – There are three types of segments in strobilla :
    - Immature segments: located near from the neck and the sex organs are immature.
    - Mature segment: It is containing both male and female organs and sex organs are fully mature.(presence numbers of ovaries and testis)
    - Gravid segments: it is look like a sac filled with fertilized eggs. The gravid segment is separated from the strobilla and appear with stool.

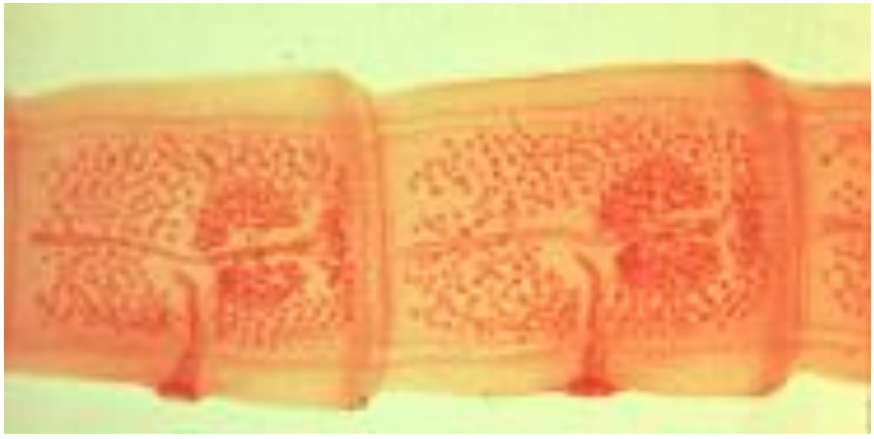

Phylum : Platyhelminthes .
Class : Cestoidean
Order : Cyclophyllidea .
Genus : ***1) Taenia***
2) Echinococcus
3) Hymenolepis

I- Taenia:

A.Taenia saginata
B.Taenia Solium

General Properties *:*

- **Common name:** **Beef tapeworm (** ***Taenia saginata)*****.**

  Pork tapeworm (***Taenia Solium)*** **.**
- **Final host** : man
- **Intermediate host:** **cow (** ***Taenia saginata*****).**
  : pig **(** ***Taenia Solium)***
- **Disease : Taeniasis , beef tapeworm infection.**
  Taeniasis(adult), cysticercosis (Larva) .
- **Habitat : Wall of small intestine**
- **Body region :**
  1. **Scolex (Head): The hold fast organ**
  2. **Neck: Posterior to the scolex .**
  3. **Stobilla(trunk) : made up of proglottid.**
- **Stages : Adult worm , Egg , Larva .**
- **Infective stage :** T. saginata **(Larva: cysticercus bovis)**

  T. solium (Larva: cysticercus cellulosae)

- **Diagnostic stages :** proglottid or egg
- **Reproduction : Tape worms are Hermaphrodites .**

➢ Morphology:

Adult Worm		
Characteries	***Taenia saginata***	***Taenia Solium***
Length	5-10 meters	3 meters
Scolex shape	pyriform scolex has 4 suckers but no rostellum.	globular scolex has rostellum with 2 rows of hooklets.
Uterus branches	15-30 branches	7-15 branches
Proglottids number	1000 -2OOO proglottid.	fewer than 1000 proglottid
Eggs number	100.000 egg	30.000-50.000 egg
Infective stage	**Cysticercus bovis**	**Cysticercus cellulosae**
Egg		
Size range	28-40 µm by 18-30 µm	
Hooklets	Three pairs; hexacanth embryo	
Other features	Radial striations on yellow brown in color	

➢ Laboratory Diagnosis:

1. Demonstration of proglottid or egg in faeces.
2. Serodiagnosis: IHA, IFA, ElISA.
3. Adhesive tape technique.

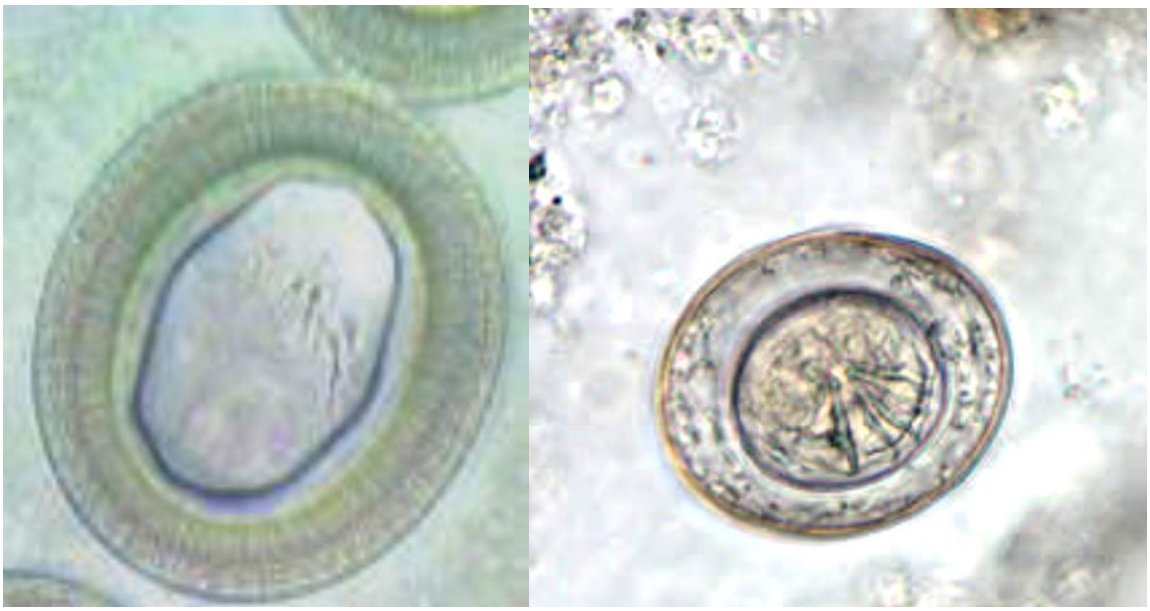

Egg of *Taenia*

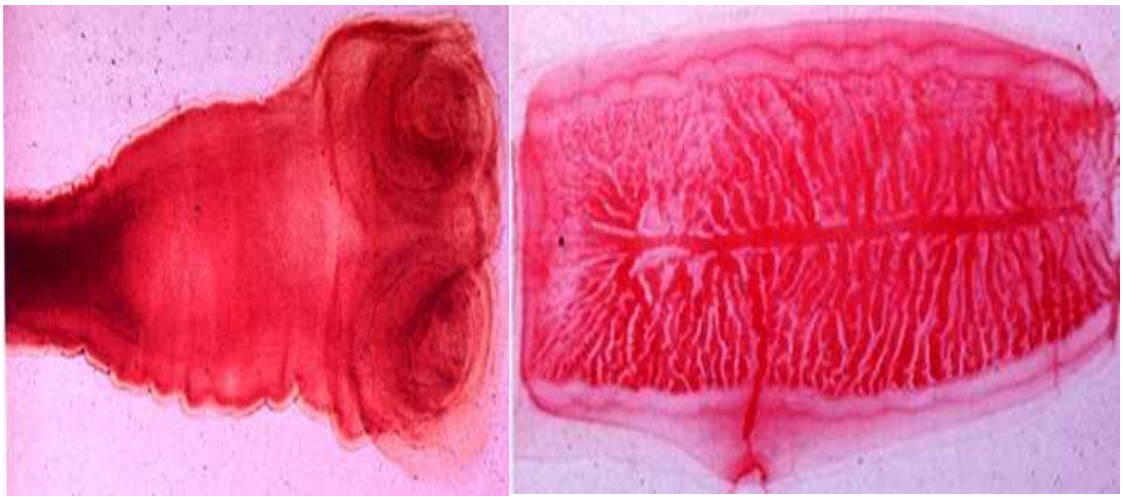

Scolex **proglottid**

Taenia saginata

Taenia solium (Adult) ***Cysticercus***

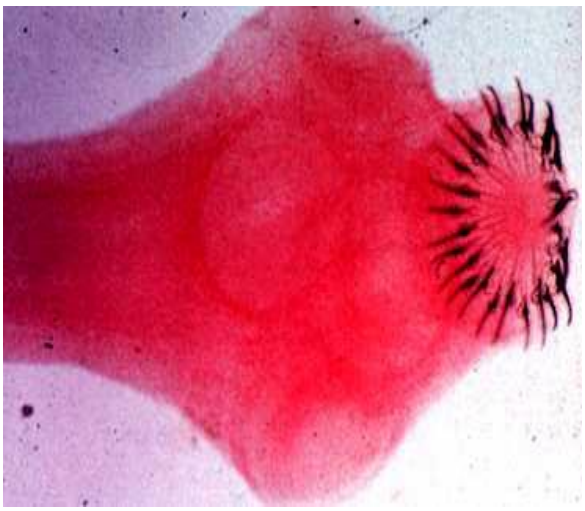



Scolex of Taenia Solium

Lab **10**.....**Helminthes**

Echinococcus granulosus

General Properties :

Common name : Dog tape worm, hydatid tape worm.

Disease : Echinococcosis, hyatid cyst, hyatid disease, hyatidosis.

Habitat : 1. liver and lungs (Man) ⟹ larval form

2. small intestine (dog and other canines) ⟹ Adult worm

Intermediate host : Sheep and other herbivores.
Accidental intermediate host : Human .
Definitive host : Dogs or wild canine .

Body region :

1. Scolex (Head): The hold fast organ
2. Neck: Posterior to the scolex .
3. Stobilla : (short)The main bulk, made up of proglottids.

Stages : Adult worm , Egg , Larva (Hydatid Cysts larval stages) .

Infective stage : Embrocated egg .

Diagnostic stages : scolices, daughter cysts, brood capsules, or hydatid sand.

- **Morphology:**

Adult Worm	
Characteries	*Echinococcus granulosus*
Length , Body shape	up to 6 mm long, ribbon-like
Scolex shape	pyriform in shape rostellum with 28 to 50hooks in 2 rows 4 suckers.
Strobila	Short with neck ,one immature ,one mature and one or two gravid proglottids
Mature segment:	with male and female genital organ, male with 45-65 testes.
Gravid segment	measures more than half the total length of the whole tape worm with sac like uterus.

Egg	
Shape & Size range	spherical , 31-40 –m in diameter
Other feature	Outer shell surround ---- with radially striated embryophore (inner shell) Hexacanth embryo


Larval stage (Hydatid cyst)	
Protective coverings	Cyst wall; multiple laminated germinal tissue layers
Basic cyst makeup	Fluid-filled bladder
Structures that arise from inner germinal layer	Daughter cysts
	Brood capsules
Other possible structures present	Hydatid sand

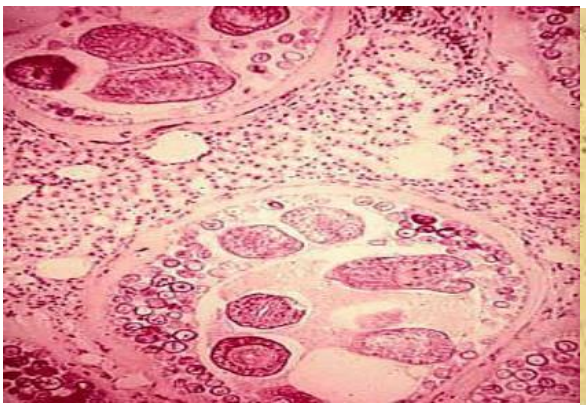
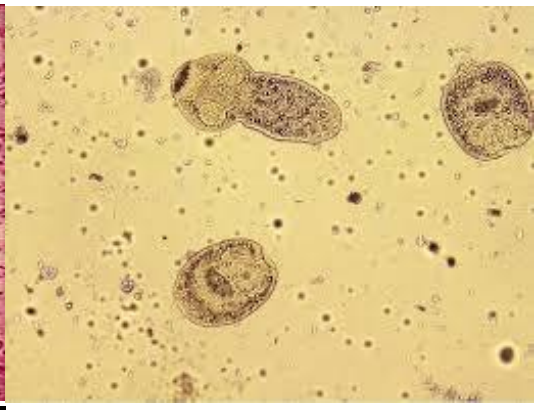

Laboratory Diagnosis:

- **Imagery**
  Hydatids are found during X-radiography, ultrasonography.
- **Immunodiagnostic techniques**
  Generally less sensitive then imagery
- **Microscopy**
  Fluid aspirated from hydatid cyst will show many protoscolices

Lab 11……Helminthes

A.Hymenolepis nana

*** Hymenolepiasis nana is an infection by adult and larval stage of H. nana. It is found world wide, primarily limited to children in war climate.**

Common name : Dwarf tape worm .
Disease : Hymenolepiasis nana, Dwarf tape worm infection .
Habitat : small intestine
Intermediate host : fleas, beetles, rats, and house mice.
Definitive host : humans and rodents

Body region :

1. Scolex (Head): The hold fast organ
2. Strobila .
3. Mature proglottids .
4. Gravid proglot .

Stages : Adult worm , Egg , Larva .
Infective stage : Embronated egg .
Diagnostic stages : Embronated egg

Morphology:

- It is a small species, The scolex bears a retractable rostellum armed with a single circle of 20 to 30 hooks. The scolex also has four suckers. The neck is long and slender, and the segments are wider than long.
- The oncosphere is covered with a thin, hyaline, outer membrane and an inner, thick membrane with polar thickenings that **bear several filaments.**
- The neck is long and slender, the region of growth.
- The strobila starts with short, narrow proglottids, followed with mature ones.
- **Laboratory Diagnosis:**

Laboratory diagnosis of *H. nana* is accomplished by examining stool samples for the characteristic eggs.



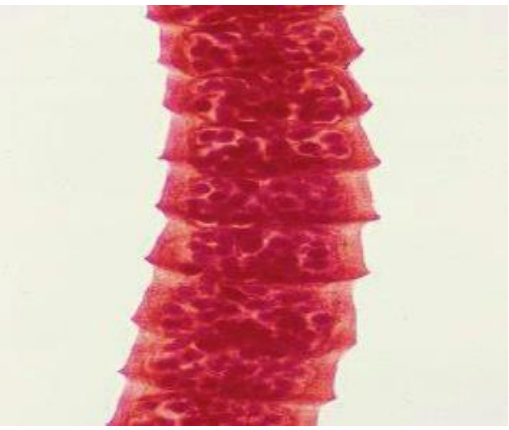

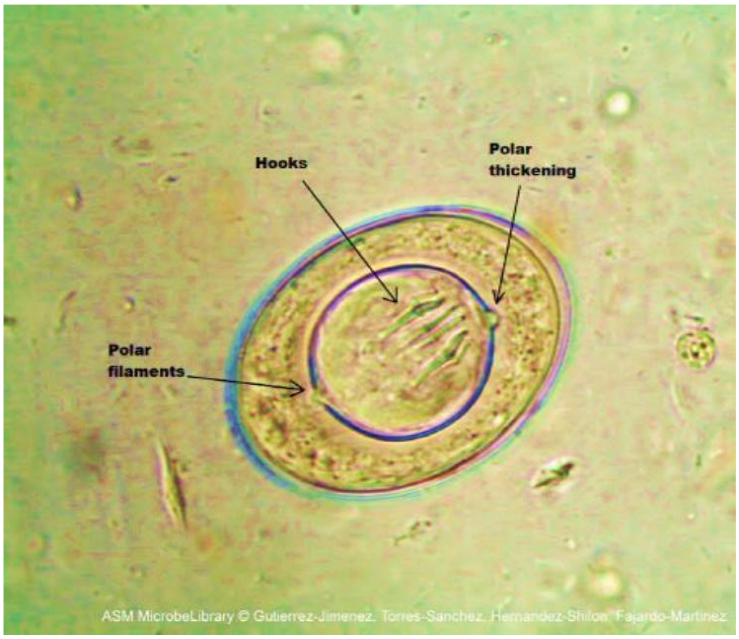
Hooks
Polar thickening
Polar filaments
ASM MicrobeLibrary © Gutierrez-Jimenez, Torres-Sanchez, Hernandez-Shiloe, Fajardo-Martinez

B. Hymenolepis diminuta

General Properties :

Common name : Rat tape worm infection.

Disease : Hymenolepiasis, rat tapeworm disease .

Habitat : in the small intestine of Rat and mice and rarely in human.

Intermediate host : grain beetle or flea .

Accidental intermediate host : Human

Definitive host : Mice , Rate .

Body region :

1. Scolex (Head): The hold fast organ
2. Strobila .
3. Mature proglottids .
4. Gravid proglot .

Stages : Adult worm , Egg , Larva .

Infective stage : Embronated egg .

Diagnostic stages : Embronated egg

Laboratory Diagnosis:

Laboratory diagnosis is accomplished by examining stool samples for the characteristic eggs.

Lab 12……. Helminthes

A.Dipylidium caninum

General Properties :

- **Common name :** Dog / cat tape worm , pumpkin seed tapeworm .
- **Disease :** Dipylidiasis , dog or cat tapeworm disease.
- **Habitat :** Adult in the small intestine of dogs and cats. Occasionally in human mostly in children, infants.
- **Intermediate host :** fleas .
- **Accidental intermediate host:** Human
- **Definitive host:** dogs and cats.
- **Body region:** 1. Scolex .
    - 2. Mature proglottids.
    - 3. Gravid proglot.
- **Stages:** Adult worm, Egg , Larva .
- **Infective stage:** larval stage.
- **Diagnostic stages:** egg packets or gravid proglottids .

Morphology :

- **Adult:**
    - **Length :**median size 1o _ 7o cm in length, 6o_17o proglottid
    - **Scolex shape:** Four suckers Rostellum Present; club-shaped, withone to seven circlets of Spines . Hooks Absent
    - **Mature segment**: Contain paired reproductive organs with a genital pore at each lateral margin
    - **Gravid segment:** Resemble cucumber seeds in shape, size. Uterus disappear early in development and replaced by hyaline , non-cellular masses of egg capsules, each egg capsule filled with 1 to 2 o fully embryonated eggs.

- **Egg :**
    - **Number of eggs in enclosed packet:** 5-30

- **Diameter range per egg :** 30-60 µm
- **Individual egg features:** Six-hooked oncosphere.

- **<u>Laboratory Diagnosis:</u>**

D. caninum diagnosis is based on the recovery of the **characteristic egg packets** or **gravid proglottids** in stool samples.

Adult (scolex)

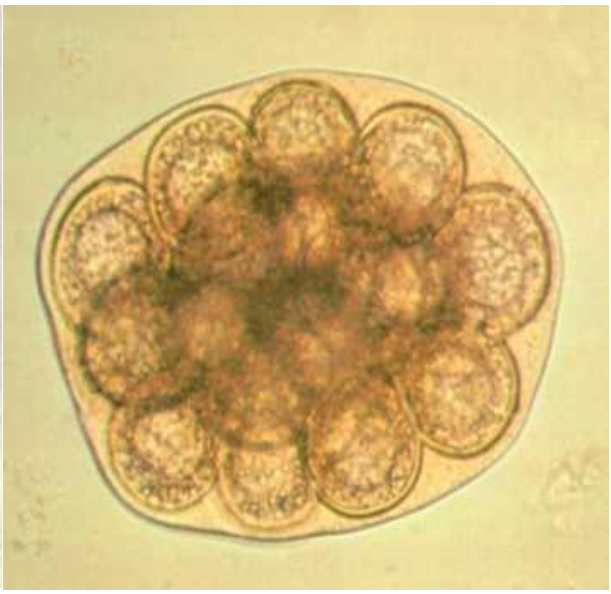

Egg

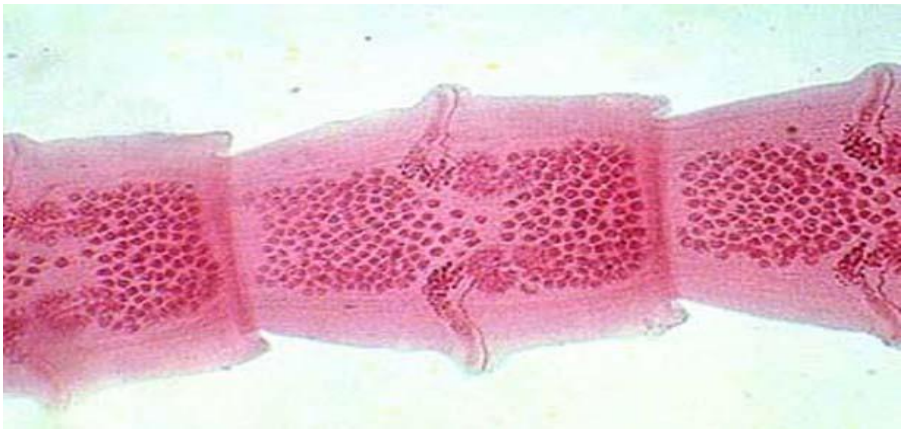

Gravid segment

B. Diphyllobothrium latum

General Properties :

- **Common name :** fish tapeworm .
- **Disease :** Diphyllobothriasis, fish tapeworm infection .
- **Habitat :** small intestine
- **First Intermediate host :** copepod crustacea.
- **Second Intermediate host :** freshwater fish
- **Definitive host :** Human.
- **Body region :** 1. Scolex .
  2. Mature proglottids.
  3. Gravid proglot.
- **Stages :** Adult worm , Egg , Larva .
- **Infective stage :** pleurocercoid defined as a precursor larval stage .
- **Diagnostic stages :** egg , gravid proglottids .

Morphology:

- **Adult Worm :**
  - **Length** 10 M in length and may have 3OOO-4Ooo proglottids .
  - **Scolex shape** Two suckers , Almond Shape.
  - **Mature segment** The genital and uterine pores open to the ventral surface in the center of the proglottid (black arrow, compare to lateral pores in other species). There are numerous testes throughout and a bilobed ovary posteriorly (red arrow).
  - **Gravid proglottids** Gravid proglottids characteristically contain a centrally located uterine structure that frequently assumes a rosette formation.
- **Egg**
  - **Size range**: 55-75 µm long, 40-55 µm wide.
  - **Shape**: Somewhat oblong
  - **Embryo**: Undeveloped, termed coracidium.
  - **Shell Smooth**: yellow-brown in color.
  - **Other features:** Operculum on one end; terminal knob on opposite end.

- **Laboratory Diagnosis:**

Stool examination looking for eggs or segments also Immunodiagnosis.

Scolex

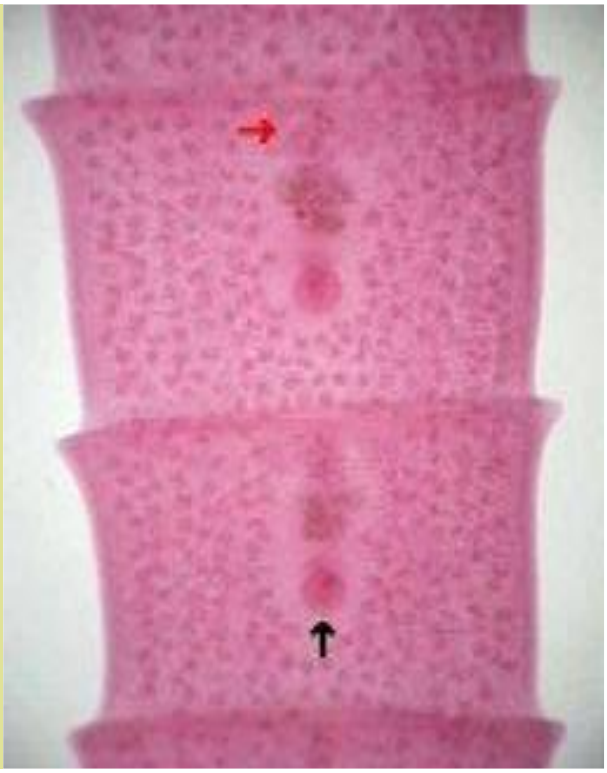

Mature segment

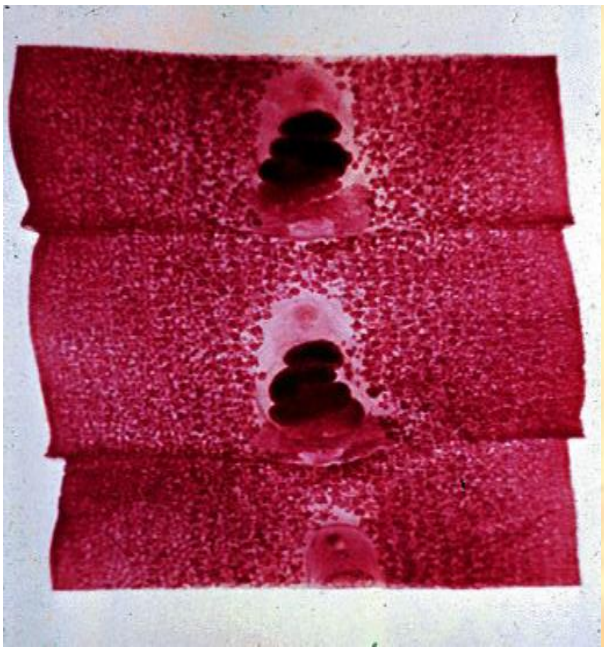

Gravid segment

Egg

Lab: 13……Helminthes

2nd Class: Trematodes class

Blood Flukes Schistosomes:

- ***Schistosoma Species:***

- **General Properties:**

Schistosoma SP	*Schistosoma mansoni*	*Schistosoma japonicum*	*Schistosoma haematobium*
Common name	Manson's blood fluke	Blood fluke	Bladder fluke
Disease	Schistosomiasis mansoni	Schistosomiasis japonicum	urinary schistosomiasis
Habitat	intestine , in intra hepatic portal veins ,vesical venules , pulmonary pulmonary	veins that surround the intestinal tract, as well as in the blood passages of the liver.	vesical venules
Final host	vertebrate	vertebrate	vertebrate
Intermediate host	Snail	Snail	Snail
Stages	Adult worm , Egg , cercaria	Adult worm , Egg , cercaria	Adult worm , Egg , cercaria
Infective stage	cercaria	cercaria	cercaria
Diagnostic stages	Egg	Egg	Egg

Morphology:

Morphology	*S. mansoni*	*S. japonicum*	*S.haematobium*
Male	6.4-9.9 mm in length has 6-9 grape like cluster testes	12-20 mm by 0,5 mm. has 7 testes	10-15 mm in length &1 mm in diameter. has 4-5 testes
Female	7.2-14 mm with	15-30 mm in length &width 0.1-0.3 mm	20mm in length &0.25 mm in width
Egg	large ,rounded at both ends & has lateral spine near one pole .	Round ,has Small; lateral	rounded at one pole & has a terminal spine at the other

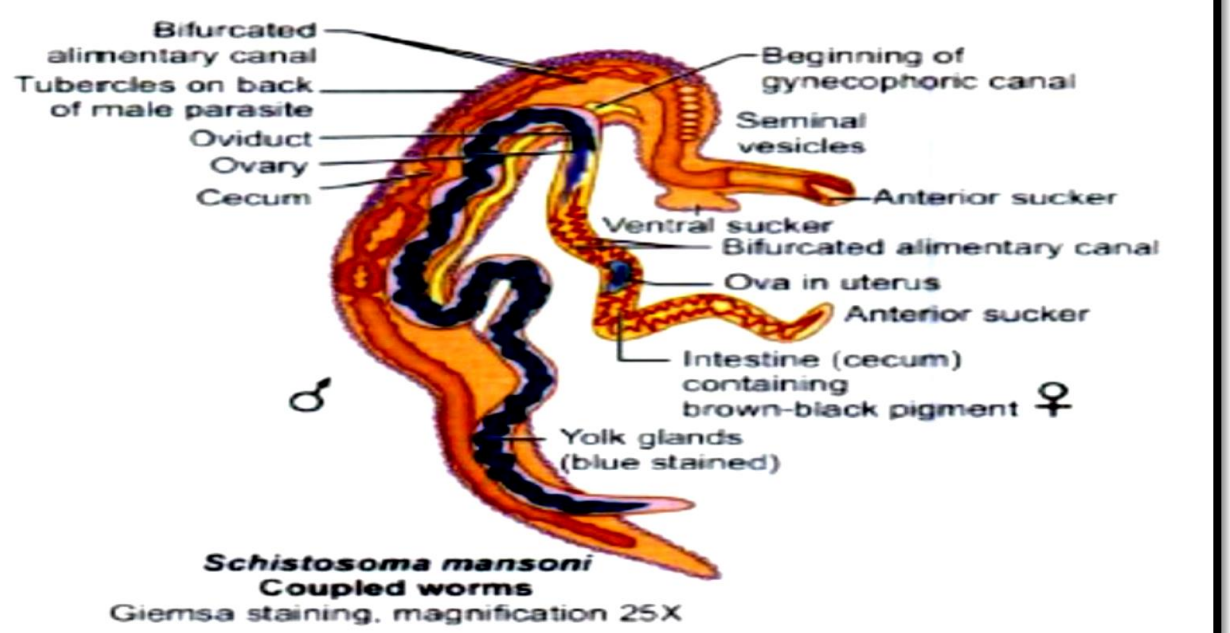

Fig. 3: Structural details of *Schistosoma* (coupled)

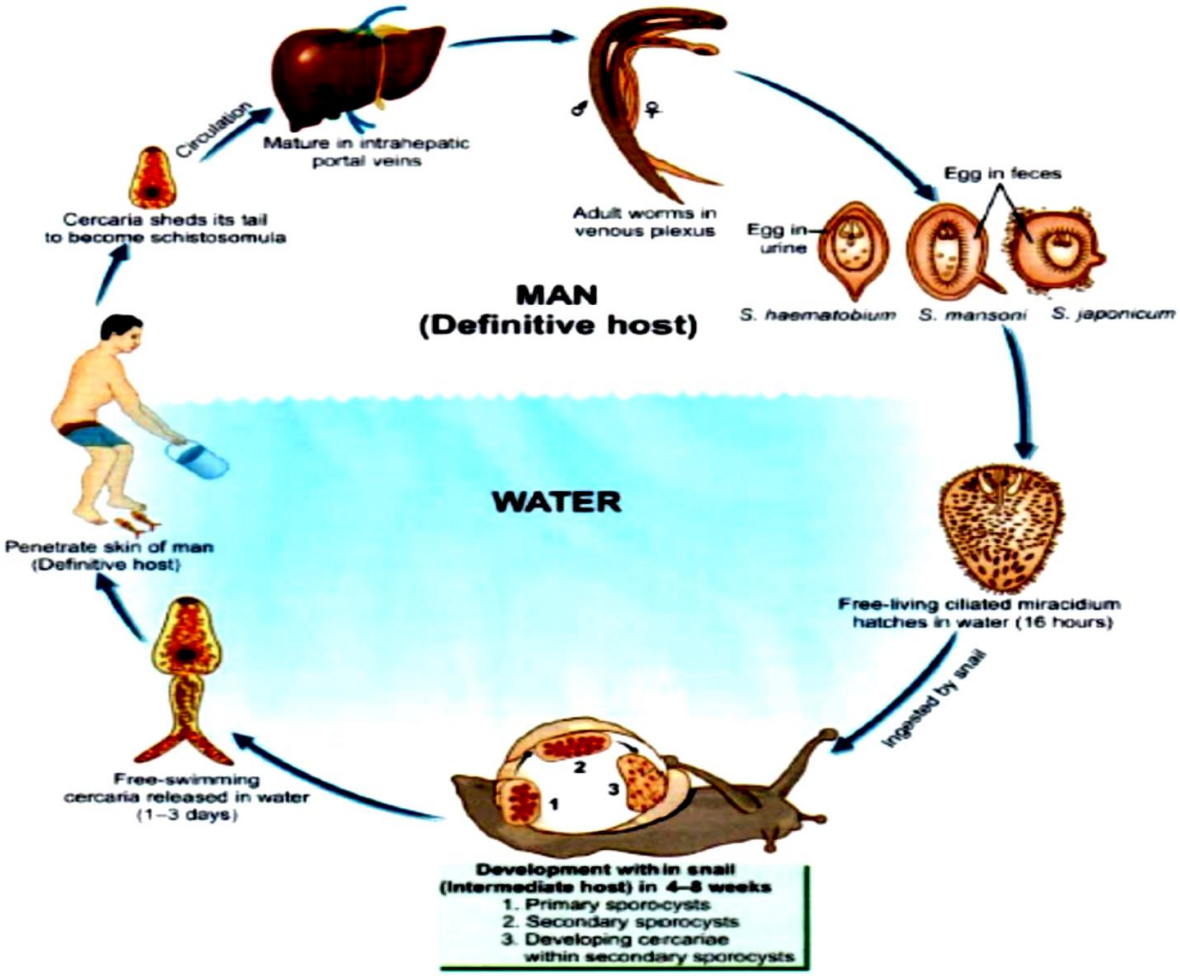

Laboratory Diagnosis

- Laboratory diagnosis of ***S. mansoni*** **and** ***S. japonicum*** is accomplished by recovery of the eggs in **stool** or rectal biopsy specimens.
- The specimen of choice for the recovery of ***S. haematobium*** eggs is a concentrated **urine** specimen.
- Immunodiagnostic techniques, including ELISA, , PCR. are also available.

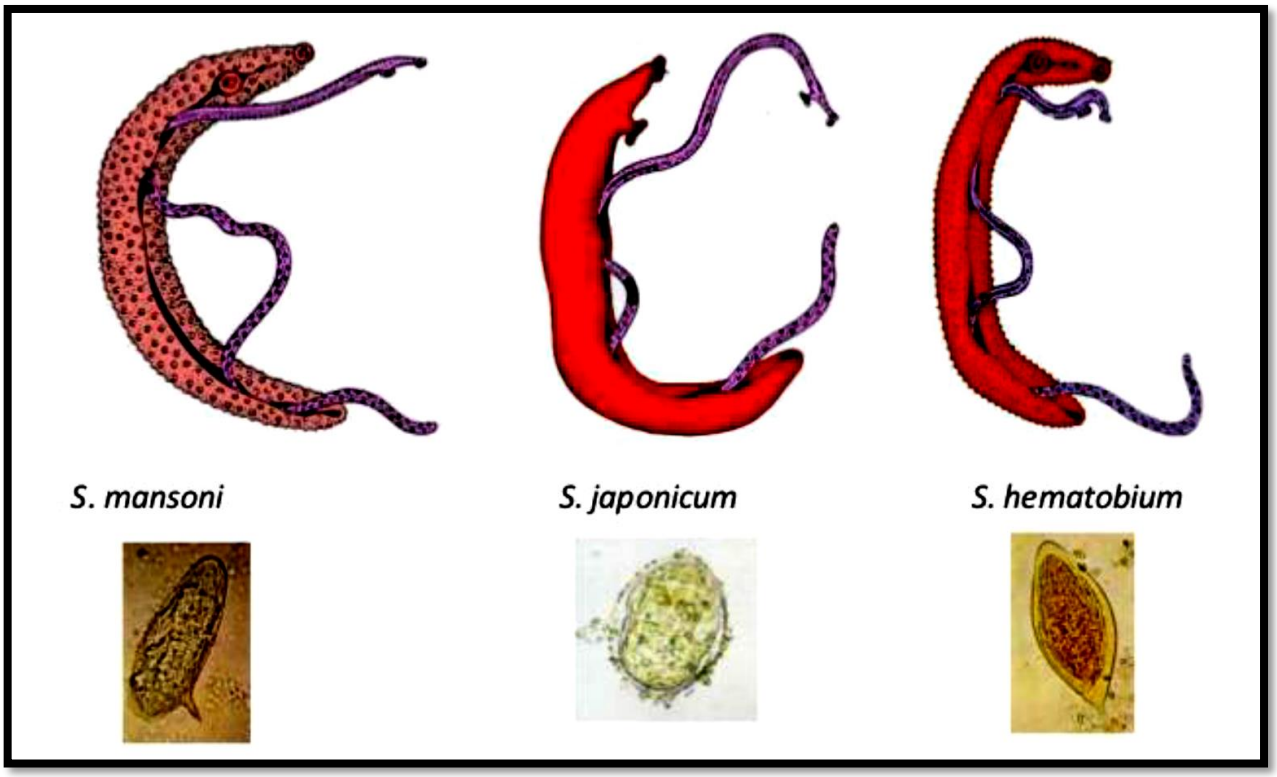
S. mansoni
S. japonicum
S. hematobium


S. mansoni
Stool
S. haematobium
Urine
S. japonicum
Stool

Lab: 14……Helminthes

Fasciola hepatica (Sheep liver fluke)*:*

General Properties*:*

- **Common name:** sheep liver fluke.
- **Diseases:** fascioliasis, sheep liver rot.
- **Habitat:** Large bile ducts & gall bladder.
- **Final Host:** sheep, goats & occasionally man.
- **Intermediate Host:** Snail.
- **Stages:** Adult worm, Egg, miracidium, sporocyst, cercariae, Metacercariae.
- **Infective stage:** Metacercaria
- **Diagnostic stages:** Embronated egg

Morphology:

Adult worm It is large in size, flat leaf-shaped fluke measuring 30 mm long and 15 mm broad, gray or brown in color. It has a conical projection anteriorly containing an oral sucker and is rounded posteriorly.

The adult worm lives in the biliary tract of the definitive host for many years about 5 years in sheep and 10 years in humans.

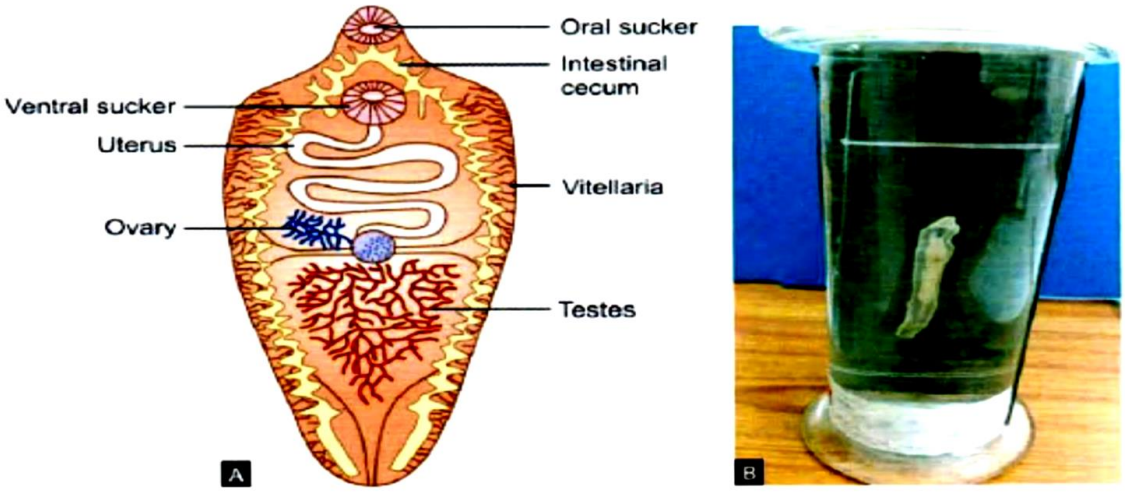

(A) *Fasciola hepatica;* (B) Specimen showing *Fasciola hepatica*

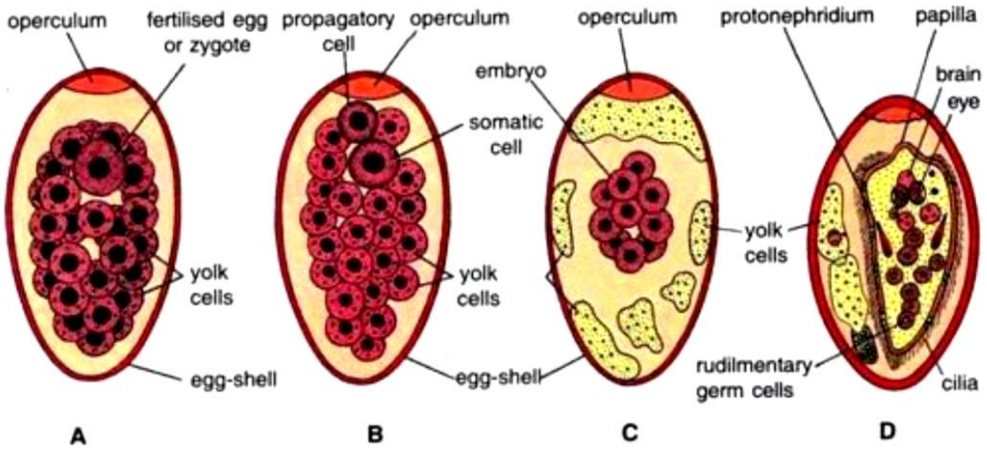

Fig. 41.14. *Fasciola hepatica.* Early stages of development. A—Fertilised egg; B—Two cell stage; C—Many cell stage; D—Miracidium in capsules.

- **<u>Laboratory Diagnosis:</u>**

1-Stool microscopy: Demonstration of eggs in feces or aspirated bile from duodenum is the best method of diagnosis. Eggs of *F. hepatica* and *F. buski* are indistinguishable.
2-Blood picture: It reveals eosinophilia.
3-Serodiagnosis: Serological tests such as immunofluorescence, ELISA, immunoelectrophoresis and complement fixation are helpful in lightly infected individuals for detection of specific antibody. ELISA becomes positive within 2 weeks of infection and is negative after treatment. In chronic fascioliasis, Fasciola coproantigen may be detected in stool.
4-Imaging: Ultrasonography, computed tomography **(CT)** scan, endoscopic retrograde cholangiopancreatography **(ERCP)** and percutaneous cholangiography may be helpful in diagnosis.

Adult of *F. hepatica*

Egg of *F. hepatica*

❖*Fasciolopsis buski*

General Properties :

- **Common name:** Giant intestinal fluke.
- **Diseases:** Fasciolopiasis.
- **Habitat:** duodenum &jejunum.
- **Final Host:** man & pig.
- **Intermediate Host:** Snail .
- **Stages:** Adult worm, Egg ,miracidium ,sporocyst , cercariae , Metacercariae .
- **Infective stage :** Metacercaria
- **Diagnostic stages :** Embronated egg

Morphology

Adult : Large ,fleshy worm (20-75)mm long, (8-20)mm in width,(0.5-3) mm thick. **Tegument** is spinose, oral sucker is smaller than the nearby acetabulum. Small branched ovary, uterus is short, convoluted. highly branched testes.

Egg: large , shaped-like hens egg (130-140)--µ-m by (80-85) µm—, thin transparent shell, small operculum at one end & are unembryonated when evacuated in the hosts feces . yellowish – brown in color.

Laboratory Diagnosis:

- The specimen choice for recovery of the eggs of *Fasciolopsis buski* is stool.
- Other methodologies available for the detection of *Fasciola* include the Enterotest, ELISA, and gel diffusion.

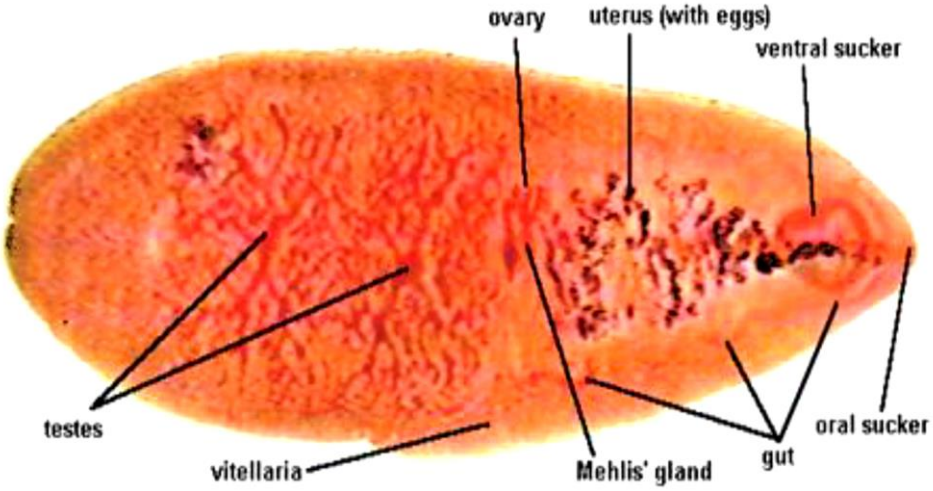

Lab: 15……Helminthes

Class Nematoda

A- Ascaris lumbricoides (Round worm)

- **General Properties :**
  - **Common name :** large intestinal roundworm ,round worm of man.
  - **Diseases :** ascariasis , round worm infection .
  - **Habitat :** large intestine
  - **Stages :** Adult worm , Egg , Larva .
  - **Infective stage :** Embronated egg and larva .
  - **Diagnostic stages :** Embronated egg
- **Morphology:**

Ascaris lumbricoides Egg		
Parameter	**Unfertilized egg**	**fertilized egg**
Size	85-95um by 38-45um	40-75umby 30-50um
Shape	subsperical	Rounder than nonfertilized version
Embryo	Unembryonated; amorphous mass of protoplasm	Undeveloped unicellular embro
Shell	Thin ,usually corticated	Thick chitin may be corticated or decorticated

Ascaris lumbricoides Adult		
Parameter	**Adult Female**	**Adult Male**
Size	22-35cm	Up to 30 cm
color	Creamy white pink tint	Creamy white pink tint
Posterior end	Pencil lead thickness	Promint incurved tail

- **Laboratory Diagnosis:**

1- General stool examination to see eggs , adult worm may be recovered in several specimen types .

2- Enzyme linked immunosorbent assay (ELISA) is also available .

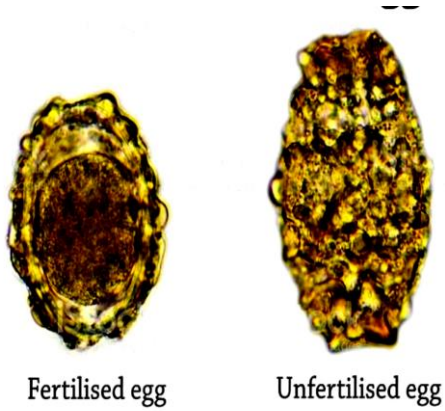

B. Entrobius vermicularis (Pin Worm)

- **General Properties :**
  - **Common name :** Pinworm , seat worm .
  - **Diseases :** enterobiasis , pinworm infection .
  - **Habitat :** small intestine
  - **Stages :** Adult worm , Egg , Larva .
  - **Infective stage :** Embronated egg .
  - **Diagnostic stages :** Embronated egg
- **Morphology**

Enterobius vermicularis Egg	
Parameter	Description
Size	48-60 um long , 20-35 um wide
Shape	Oval , one side flattened
Embryo	Stage of development varies ; my be unemdryonated , embryonated ,mature
Shell	Double-layered ,thick ,colorless

Enterobius vermicularis Adult		
Parameter	**Adult Female**	**Adult Male**
Size	7-14 mm	2-4mm
Width	Up to 0.5mm	≤o.3mm
Color	Yellowish -White	Yellowish -White
Tail	Pointed resemble pinhead	Strongly curved and the lateral view of the worm forms an inverted question mark

Laboratory Diagnosis:

1) The eggs are recovered from perianal skin by using cellophane tape technique and examined microscopically.

2) The technique preferably done at night or in the early morning before bathing.

Adult Male

Adult Female

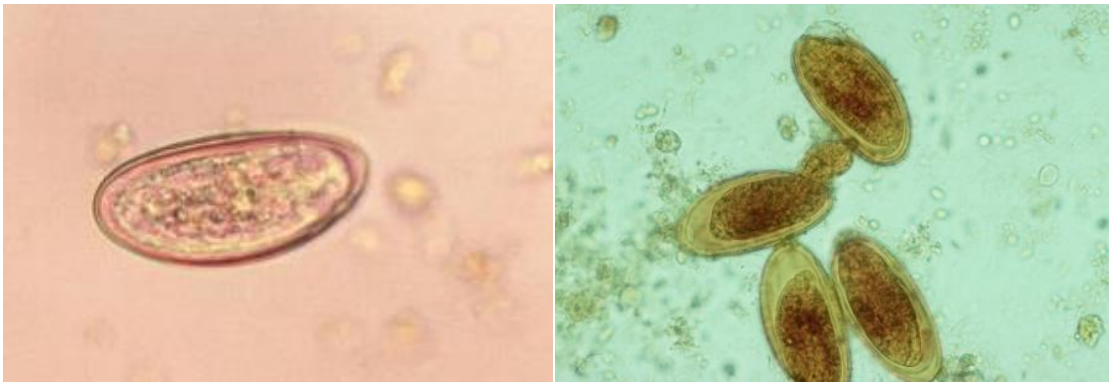

Egg

C- *Trichuris trichiura* (The Whipworm)

- **General Properties :**
  - **Common name :** Whipworm .
  - **Diseases :** Trichuriasis , Whipworm infection .
  - **Habitat :** small intestine
  - **Stages :** Adult worm , Egg , Larva .
  - **Infective stage :** Embronated egg .
  - **Diagnostic stages :** Embronated egg
- **Morphology**

Trichuris trichiura Egg	
Parameter	**Description**
Size	50-55 by 25 um
Shape	Barrel ,football ,hyaline polar plug at each end
Embryo	Unicellular ; undeveloped
Shell	Smooth ; yellow –brown color because of bile contact

Trichuris trichiura Adult		
Parameter	**Adult Female**	**Adult Male**
Size	2.5 cm long	Males usually smaller than females
Anterior end	Colorless ; resembles whip handle; contains a slender esophagus	Colorless ; resembles whip handle; contains a slender esophagus
Posterior end	Pinkish –gray ; resembles whip itself ; contains digestive and reproductive systems ,club shape end	Possess prominent curled tail

Laboratory Diagnosis:

1. General stool examination to see the characteristic eggs .
2. Diarrheal or dysenteric stools contain eosinophils and charcot –leyden crystals.
3. Adult or immature worm my be seen attached to the prolapsed rectum or at sigmoidoscopy .



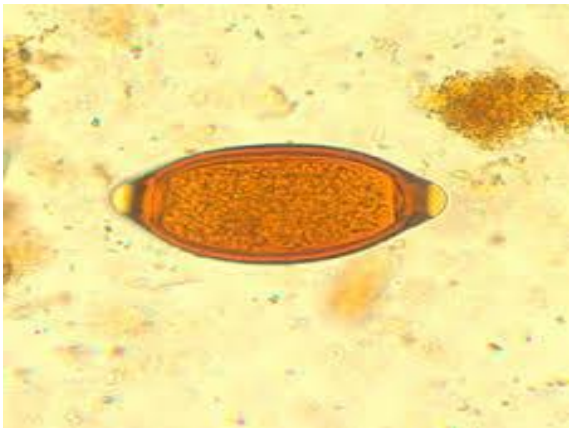

D- *Ancylomstoma duodenale*

General Properties :

- **Common name :** large intestinal roundworm ,round worm of man .
- **Diseases :** , hook worm infection , *Ancylostomiasis ,necatoriasis*.
- **Habitat :** small intestine
- **Stages :** Adult worm , Egg , Larva (rhabditiform larva ,filariform larva).
- **Infective stage :** filariform larva .
- **Diagnostic stages :** Embronated egg.

- **Morphology:**

Ancylostoma duodenale Egg	
Parameter	**Description**
Size	Length 55-60 um Width 35-40 um
Embryo	Two –four or eight –cell stage
Shell	Smooth ,coloeless

Ancylostoma duodenale Adult		
Parameter	**Adult Female**	**Adult Male**
Size	9-12mm long 0.25 -0.5mm wide	5-10mm long 0.2-0.4 mm wide
Posterior end	Tapered at the posterior end	Prominent posterior copula tory bursa
mouth	Contains actual teeth	

Ancylostoma duodenale larva		
Parameter	**Rhabditiform larva**	**Filariform larva**
Size	Newly hatched 270 by 15 um 5day old , 540-700 um long	Short ,more slender
Other feature	Long buccal cavity ; small genetal primordium	It has closed mouth ,elongated esophagus and pointed tail

- **Laboratory Diagnosis :**

General stool examination for eggs demonstration, larvae may mature and hatch from the eggs

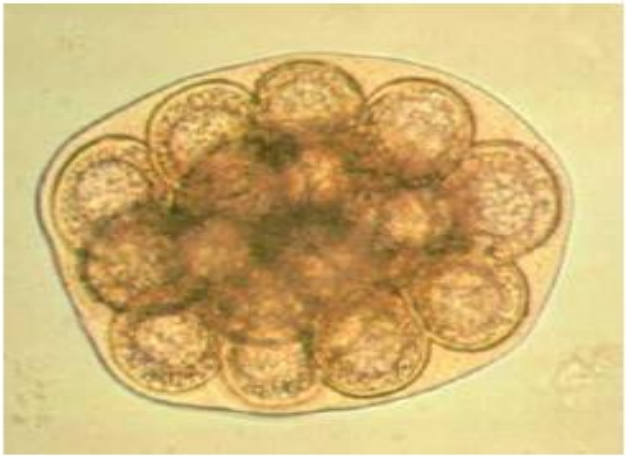

Medical Parasitology

2nd stage

Medical laboratory technique department

PhD/Parasitology

Dr. Thuraya Khaled

Lecture :- 1

Parasitology

Parasite :- smaller organism live on or in large organism called (host).

Host:- **host** is an organism that harbors a parasite.

The **Parasitology** is the study of parasites, their hosts, and the relationship between them.

Relationship between host and parasite including

Symbiosis :- Symbiotic relationships include those associations in which one organism lives on another (ectosymbiosis, such as mistletoe), or where one partner lives inside the other (endosymbiosis, such as lactobacilli and other bacteria in humans.

1- **Mutualism:-** is the way two organisms of different species exist in a relationship in which each individual benefits from the activity of the other.(like bacteria in intestine)
2- **Commensalism:-** is a class of relationships between two organisms where one organism benefits without affecting the other. It can be compared with mutualism, in which both organisms benefit, .
3- **Parasitism:-** is a non-mutual symbiotic relationship between species, where one species, the **parasite**, benefits at the expense of the other, the host may be harm .

a **life cycle** is a series of changes in form that an organism undergoes, returning to the starting state. Those that must infect more than one host species to complete their life cycles are said to have **complex or indirect life cycles**, while those that infect a single species have **direct life cycles**.

Parasites are classified based on their interactions with their hosts and on their life cycles.

An **obligate parasite** is totally dependent on the host to complete its life cycle, while a **facultative parasite** is not.

Parasites that live on the surface of the host are called **ectoparasites** (e.g. some mites). Those that live inside the host are called **endoparasites** (including all parasitic worms).

Permanent parasite :- all life in host

Temporary parasite :- some part of life in the host.

Accidental parasite :-wich exist in an usually host

Vector :- an organism, often an invertebrate arthropod, that transmits a pathogen from host to host.

In terms of Epidemiology a vector is an organism which transmits diseases to healthy organisms.

A **biological vector** develops an infected organism in its body and passes it along to its host. e.g

mosquito while a **mechanical vector** carry an infected organism to its host through its legs and other body parts. e.g flies.

the hosts can be divided in to several classes as well. These are:

- **Definitive host** (DH).
  A definitive host is an organism that hosts the adult (sexual) form of the parasite
- **Intermediate host** (IH).
  An intermediate host is an organism that hosts the asexual form of the parasite (only when there is an obligatory passage through the host).

A **primary host** or **definitive host** is a host in which the parasite reaches maturity and, if possible, reproduces sexually.

A **reservoir host** can harbour a pathogen indefinitely with no ill effects. A single reservoir host may be reinfected several times.

A **secondary host** or **intermediate host** is a host that harbors the parasite only for a short transition period, during which (usually) some developmental stage is completed..

A **paratenic host** is similar to an intermediate host, only that it is not needed for the parasite's development cycle to progress..

A **dead-end host** or incidental host is an intermediate host that does generally not allow transmission to the definitive host, thereby preventing the parasite from completing its development. For example, humans are dead-end hosts for *Echinococcus canine* tapeworms.

Antiparasitic Drugs: Types and Mechanisms

Parasites, such as protozoans and worms, or helminths,.so the **antiparasitic drugs causes the buildup of a toxic molecule called heme inside the parasite, and it is also thought to block the parasite's DNA synthesis**.There are a few drugs that are commonly used to treat these kinds of protozoan diseases. The first one,**Metronidazole**, **fights protozoans by damaging their DNA and inhibiting DNA synthesis.** It is selectively toxic because it's a pro-drug, meaning that it starts off as a harmless molecule that must be converted into an active drug. Lucky for us, this conversion doesn't happen in our own cells, only inside of protozoans and also anaerobic bacteria.

Nitazoxanide is another antiprotozoan drug that disrupts the anaerobic metabolism that these parasites use to make energy, so treatment with this drug is like turning off the parasite's electricity source.

Antihelminthic Drugs

Next, we'll talk about the drugs that are used to treat helminthes infections, that is, parasitic worms.**Niclosamide** is a drug that pulls the plug on worms' energy source by stopping production of ATP, a major energy carrier in all cells. **Mebendazole** also cuts off worms' energy, this time by preventing them from absorbing nutrients from their environment.

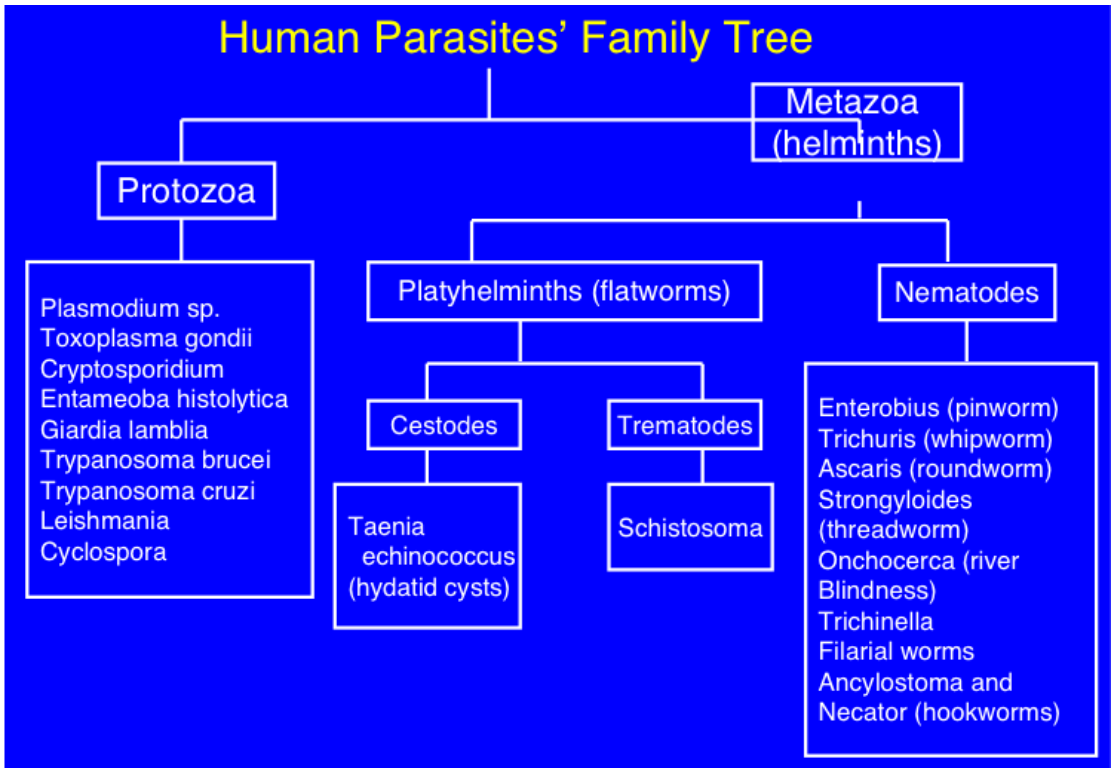

Lecture :- 2

Introduction

Protozoology is the study of protozoan, Protozoa are unicellular, heterotrophic eukaryotes that have been studied for more than 300 years, at first as microscopic curiosities, later as organisms causing disease and more recently as important components of ecosystems **protozoology,** the study of protozoans. The science had its beginnings in the latter half of the 17th century when Antonie van Leeuwenhoek of the Netherlands first observed protozoans by means of his invention, the microscope. Protozoans are common, and they are of particular interest to man **because they cause such diseases as malaria, amoebic dysentery, and African trypanosomiasis (sleeping sickness). Certain protozoans known as foraminifera, which have an extensive fossil record, are useful to geologists in locating petroleum deposits**. Deciphering the Greek roots results in defining protozoa as 'first' (proto) 'animals' (zoa). such a definition does not provide much descriptive information. they are **unicellular eukaryotic micro-organisms** morphologically or functionally different from those found in other eukaryotes. **Shapes range from the amorphous and ever-changing forms of ameba**.

Characteristics

Protozoa commonly range in length between 10 to 52 micrometers, but can grow as large as 1 mm. They are easily seen with a microscope. The largest protozoa are known as **deep-sea dwelling xenophyophores**, which can grow up to 20 cm in diameter.

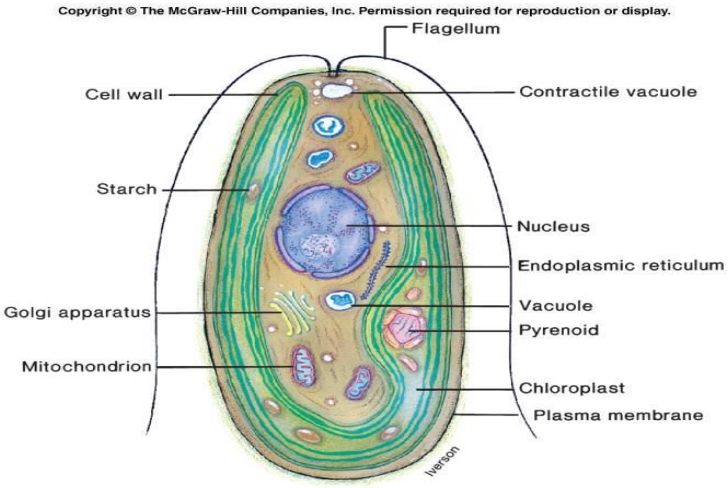

Motility and digestion

Tulodens are 2 of the slow-moving form of protozoa[citation needed]. They move around with whip-like tails called **flagella** (5-10 µm long), hair-like structures called **cilia** (20-30 µm long), or foot-like structures called **pseudopodia** (2 µm thick by 20 µm). Others do not move at all. Protozoa may absorb food via their cell membranes, some, e.g., amoebas, surround food and engulf it, and yet others have openings or "mouth pores" into which they sweep food ,and that engulfing of food is said to be phagocytosis . All protozoa digest their food in stomach-like compartments called vacuoles.

Modes of Motility	
Mechanism	**Subgroup**
ameboid movement	Amebas
Flagella	Flagellates
Cilia	Ciliates
gliding motility	Sporozoa

Many protozoa simply absorb solutes (i.e., osmotrophy) from their media, while some are scavengers that ingest solid material (i.e., phagotrophy). Some protozoa are photosynthetic and can capture the energy of the sun and convert it to usable chemical energy (i.e., autotrophic or phototrophic)

Life cycle and reproduction

Some protozoa have life stages alternating between proliferative stages (e.g**., trophozoites**) and dormant **cysts.** As cysts, protozoa can survive harsh conditions, such as exposure to extreme temperatures or harmful chemicals, or long periods without access to nutrients, water, or oxygen for a period of time. Being a cyst enables parasitic species to survive outside of a host, and allows their transmission from one host to another. When protozoa are in the form of trophozoites they actively feed. The conversion of a trophozoite to cyst form is known as **encystations** Cysts of parasitic protozoa serve three primary functions:

- (1) as protection against unfavorable external environmental conditions,
- (2) as the site of morphogenesis and nuclear division, and
- (3) as means of transmission from one host to another.

, while the process of transforming back into a trophozoite is known as **excystation**. Parasitic protozoa most commonly reproduce by means of an asexual process called fission, a form of mitosis whereby each parent forms two progeny. The plane of division is random among amoebae, usually longitudinal in flagellates, and transverse in ciliates. The sequence of division in a typical protozoan is as follows:**Organelles, Nucleus, and finally, Cytoplasm**

. In apicomplexans , **multiple fission or schizogony** occurs. This type of asexual reproduction is characterized by rapid organelle and nuclear divisions, followed by multiple cytokinesis. The multinucleated cell is called the **schizont or segmenter**. After cytoplasmic division, each nucleus, with its attendant cytoplasm, forms a separate organism, a merozoite, which usually breaks away from the aggregate to infect a new host cell. Once a merozoite enters a new host cell, it may either enter anoter schizogonic cycle or become a macro or microgametocyte. Syngamy, the union of gametes derived from the gametocytEs, initiatEs the sexual cycle. The resulting zygote undergoes sporogony, which results in the production of sporozoites. The organisms that produce malaria are apicomplexans capable of both schizognic (asexual) and sporogonic (sexual) reproduction. Conjugation, the specialized sexual mechanism in the ciliatEs, has already been discussed; it is distinguishable from syngamy in that conjugation involves nuclear exchange and union, whereas syngamy involves the union of entire cells (e.g., gametes).

Classification

- Flagellates (e.g., *Giardia lamblia*)
- Amoeboids (e.g., *Entamoeba histolytica*)

- Sporozoans (e.g., *Plasmodium knowlesi*)
  - Apicomplexa (now in Alveolata)
  - Microsporidia (now in Fungi)
  - Ascetosporea (now in Rhizaria)
  - Myxosporidia (now in Cnidaria)
- Ciliates (e.g., *Balantidium coli*).

Stool Samples Collection

1. Collect the stool in a dry and clean container, make sure no urine, water, soil or other material gets in the container.
2. Fresh stool should be examined, processed, or preserved immediately. An exception is specimens kept under refrigeration.

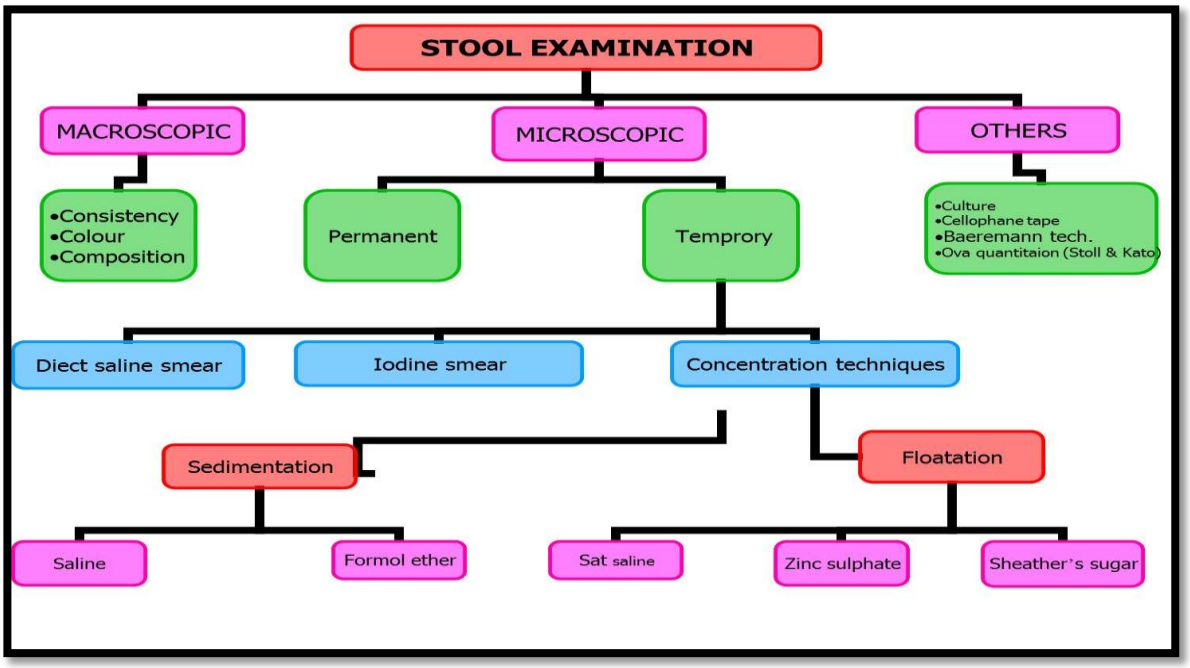

3. Specimen collection may need to be repeated if the first examination is negative, if possible, three specimens passed at intervals of 2-3 days should be examined.
4. Preserve the specimen as soon as possible.

Phylum	Common Name	Locomotion	Examples
Sarcodina	sarcodines	**pseudopodia**	**Amoeba** 
Ciliophora	ciliates	**cilia**	**Paramecium** 
Sarco-mastigophora (Zoomastigina)	zooflagellates	**flagella**	**Trypanosma**  Giardia
Apicomplexa (Sporozoa)	sporozoans	**none in adult form**	**Plasmodium** 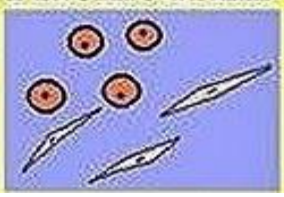

Sarcodine, any protozoan of the superclass (sometimes class or subphylum) Sarcodina. These organisms have streaming cytoplasm and use temporary cytoplasmic extensions called pseudopodia in locomotion (**called amoeboid movement**) and feeding. Sarcodines include the genus *Amoeba* (*see* amoeba) and pathogenic species, *e.g.*, dysentery-causing *Entamoeba histolytica*

Entamoeba histolytica.

An **amoeba** (also **ameba**, **amœba** or **amoeboid**) is a type of cell or organism which has the ability to alter its shape, primarily by extending and retracting pseudopods.

Scientific classification	
Domain:	Eukaryota
Phylum:	Amoebozoa
Class:	Archamoebae
Order:	Amoebida
Genus:	*Entamoeba*

Species: ***E. histolytica***

Transmission and life cycle :-

The active (trophozoite) stage exists only in the host and in fresh loose feces; cysts survive outside the host in water, in soils, and on foods, especially under moist conditions on the latter. The cysts are readily killed by heat and by freezing temperatures, and survive for only a few months outside of the host. **When cysts are swallowed** they cause infections by excysting (releasing the trophozoite stage) in the digestive tract.

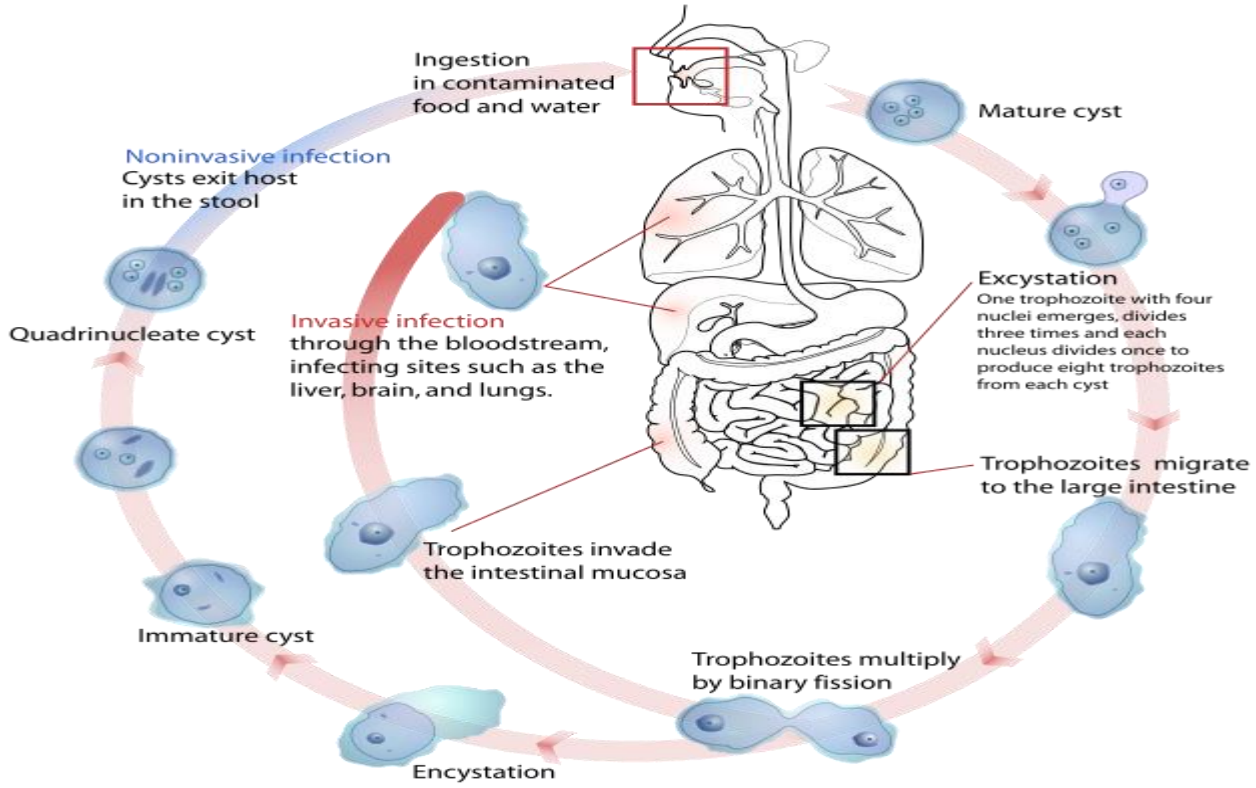

Pathogenesis and clinical sings :-

The pathogenic of *E. histolytica* ; infection can be **asymptomatic** or can lead to amoebic dysentery or amoebic liver abscess**. Symptoms can include fulminating dysentery, bloody diarrhea, weight loss, fatigue, abdominal pain, and amoeboma**.

Amoebic colitis

The *E. histolytica* parasite can cause inflammation of the lining of your gut (intestines). This condition is known as amoebic colitis. 'Colitis' is a general term used for inflammation of the lining of the large intestine (the colon). 'Amoebic' refers to the fact that the colitis is caused by the amoeba *E. histolytica*. The disease is often mild and can just lead to tummy (abdominal) pain and diarrhoea. However, more severe inflammation with ulceration of the intestinal lining can occur in some people and so-called 'amoebic dysentery' can develop. (Dysentery is any

infection of the intestines, causing severe diarrhoea with blood and mucus.) So, symptoms of amoebic dysentery include severe abdominal pain and diarrhoea which can contain blood and mucus. High temperature (fever) may be another symptom but this is not common. You may also experience loss of appetite and weight loss. Symptoms can last for several weeks. Some people with amoebic colitis may just develop bleeding from their back passage (rectal bleeding) with no diarrhoea. The amoeba can actually 'bore' into the intestinal wall, causing lesions and intestinal symptoms, and it may reach the blood stream.

Extraintestinal amoebiasis

Sometimes, the trophozoites may rupture the wall of capillaries, enter the blood stream and primarily reach the liver where they may cause abscesses (**some call it secondary amoebiasis**). Rarely, an amoebic **liver abscess** can burst (rupture) and lead to damage to your diaphragm - the thin muscle that separates your chest cavity from your abdominal cavity. This can allow spread of the abscess into your chest cavity, **affecting your lungs and your pleura - the membrane that covers your lungs**. Symptoms of such a complication include cough, difficulty breathing and pain in your chest when you breathe in. Also, very rarely, in someone with an amoebic liver abscess, infection can spread to their brain and central nervous system. This can be very serious and it needs quick treatment. Symptoms include headache, felling sick (nausea), being sick (vomiting) and confusion.

Diagnosis :-

1- Amoebiasis may be diagnosed when *E. histolytica* is seen in your stools (faeces) after a stool sample is sent to the laboratory and examined under a microscope.

2- Other methods to detect *E. histolytica* in your stools have also been developed, including stool antigen detection (looking for *E. histolytica* proteins in your stools). The infection may also be diagnosed using a blood test that looks for evidence of *E. histolytica* infection in your blood. (If you have infection, antibodies to *E. histolytica* are usually found in your blood. These are another type of protein that are made in response to *E. histolytica* antigen. enzyme immunoassay (EIA); indirect hemagglutination (IHA); Antigen detection – monoclonal antibody

3- Sometimes a colonoscopy is performed if you have bloody diarrhoea and other tests have been negative. A colonoscopy is a procedure which uses a thin, flexible telescope passed through your back passage (anus) into your colon to allow examination of your colon. A tissue sample (biopsy) taken at colonoscopy and examined under the microscope can show the parasites (living things that live in, or on, other living organisms) in your intestinal lining.

4- A liver ultrasound scan or a CT scan of your liver can show a liver abscess.

5- Other tests may also be carried out if you have amoebic colitis or an amoebic liver abscess; for example, blood tests to look at your liver function, blood tests to look for anaemia, Most common is direct fecal smear (DFS) and staining (but does not allow identification to species level)

6- **PCR** for species identification. Sometimes only the use of a fixative (formalin) is effective in detecting cysts.

7- **Culture**: From faecal samples **- Robinson's medium, Jones' medium**

Lecture :- 4

Entamoeba Hertmanni

Geographical Distribution: Cosmopolitan

Habitat: trophozoite and cyst live in the small intestine Known as "small race"

Morphology:-

Life cycle

Similar to the life cycle of *E.histolytica.*

Mode of Transmission

Through contaminated food or drink, or from hands contaminated with faeces.

Pathology:- Harmless commensal

Laboratory Diagnosis:

- Finding the characteristic trophozoite and cyst stages in stool specimen. Differential *characters*:
- Cyst of *E.hertmanni* is similar to that of *E.histolytica* / *E. dispar* but the former is smaller in size.
- Cyst of *E.hertmanni* is also similar to that of *E.nana* but the later has 4-hole like nucleus and don't have chromatoid body

Entamoeba coli

***Geographical Distribution*:** Cosmopolitan.

Habitat: Both trophozoite and cysts in the large intestine of man

Life cycle

Similar to the life cycle of *E.histolytica.*

Mode of transmission

Ingestion of contaminated food or drink by infective cyst.

Pathology:- Harmless commensal, may cause diarrhea in children.

Laboratory diagnosis:-

Finding the characteristic trophozoite and cyst stages in stool specimen. Can be differentiated from *E.histolytica by its larger size. The cyst of E.coli shows a greater variation in shape and size than those of E.histolytica.*

Entamoeba gingivalis

Geographical distribution: world wide distribution

Habitat: Oral cavity

Morphology:-Has trophozoite stage only, no cyst stage

Life cycle:-It is reproduced by binary fission and transmitted from one person to another **through kissing , droplets spray from the mouth,contaminated spoons or cups.**

Pathology: non pathogenic commensal amoebae

Laboratory Diagnosis:-Finding the characteristic trophozoite stage from swab of the oral cavity. It is the only species to ingest host's leukocytes and has numerous food vacuoles.It should be differentiated from *Trichomonas tenax which belong to flagellates and found in oral cavity.*

Endolimax nana

Geographical distribution: cosmopolitan.

Habitat: Trophozoite and cyst in the large intestine.

Life Cycle:-Trphozoite stage reproduces by binary fission and man acquires infection from contaminated food or drink with mature cyst stage.

Laboratory Diagnosis:-Finding of the cyst and trophozoite stages in fecal smear.

Iodamoeba butschili

Geographical distribution: Cosmopolitan.

Habitat: both trophozoite and cyst in the large intestine.

Pathology: It is non-pathogenic.

Laboratory diagnosis:-Finding the characteristic trophozoite and cyst stages in the direct fecal smear examination or using concentration technique.

Entamoeba polecki

Most commonly infects pigs and monkeys; but may cause mild diarrhea in human .

Lecture :- 5 & 6

Mastigophora: Flagellates

Flagellates infecting man are divided into two groups.

1. The oro-intestinal and urogenital flagellates and
2. The Hemo-somatic flagellates.

The Oro-intestinal and Urogenital Flagellates

General Characteristics

1. Uses flagellum as locomotory organell
2. Reproduce by simple binary fission
3. Complete their life cycles in a single host and a second host whom they infect is necessary for the continuation of the species
4. The infective stage may be either the trophozoite or the cyst stage
5. Except the species of *Trichomonas and Dienatamoeba fragilis*, all have both cyst and trophozoite stages.

Dientamoeba fragilis

Geographical Distribution: World wide

Habitat: In the large intestine.

Morphology: Has trophozoite stage only, No cyst stage.

Life cycle:- The mode of transmission is uncertain but most likely is feco-oral nature. It is postulated that the delicate trophozoite is transported from person to person inside the protective shell of helminth ova such as *Entrobius vermicularis*. It reproduces asexually by binary fission. It is considered to be harmless commensal

Laboratory Diagnosis:-The trophozoite stage is highly fragile and disintegrates explosively in water immediately. Hence it needs immediate examination of fresh stool specimen to find the trophozoite stage.

Chilomastix mesnili

Geographical Distribution: cosmopolitan but mostly prevalent in warm climates.

Habitat: Trophozoite and cyst live in the colon and caecum of the large intestine.

Life Cycle

Cyst⟶Excystation⟶Trophozoite⟶Binary fission⟶encystation⟶

Cyst in the faeces Trophozoite stage reproduces by binary fission. The infective stage is the cyst from contaminated food or drink. Excystation occurs in the large intestine and trophozoite multiplies by binary fission.

Pathology: It is commensal

Laboratory Diagnosis:-Finding the trophozoite and cyst stages in stool specimen. The trophozoite stage is very similar to *Giardia lamblia and Trichomonas hominis*; and needs careful identification.

Giardia lamblia

Also called *Giardia intestinalis* and *G.duodenale*

Geographical Distribution:- Cosmopolitan distribution in warm climate and is more prevalent in children than in adults. It is the most commonly diagnosed flagellate of the human intestinal tract. High prevalence occurs in young, malnourished children in large families, orphan asylums, and elementary schools.

Habitat: Upper parts of the small intestine mainly in the duodenum and jejunum.

Life Cycle

Requires a single host to complete its cycle and reproduces by a simple longitudinal binary fission

Cyst ingested⟶excystation⟶Trophozoite⟶binary fission⟶Encystation⟶cyst in faeces

Infection occurs by ingestion of mature tetranucleated cyst With contaminated food, drink, finger, etc. Following ingestion, the cyst excyst in the upper part of the small intestin to form flagellates. They become **attached to the intestinal wall by a sucking disc and absorb nourishment through their body surface**. They multiply by longitudinal binar fission and some of them are carried down the intestinal tract to undergo encystation. The trophozoites and infective cysts are excreted in the faeces.

Clinical Feature and Pathology:-Major symptoms includes duodenitis, excess secretion of mucus or malabsorption of fat (steatorrhoea), sugar

and vitamins, dehydration, diarrhoea, weight loss, poor appetite, vomiting, lethargy bile passage obstruction

Prevention and Control:

1. Improving personal, family and group sanitation and hygiene.
2. Avoid contamination of food, drink and hands with the faeces.
3. Safe water supply and latrine construction.
5. Treatment of infected individuals and health education.

***Laboratory Diagnosis*:-**Finding the trophozoite and cyst stages in stool specimen. The stool is usually offensive, bulky, pale, mucoid (fatty), diarrheic (watery) but there is no blood in the stool. Several specimens collected at different time need to be examined because trophozoites and cysts are excreted irregularly. Intestinal and non pathogenic flagellate that require differentiation from *G.lamblia* include : *C.mesnili* and *Pentatrichomonas hominis (*formerly *T.hominis).*Trophozoites of the above mentioned flagellates can be easily differentiated from *G.lamblia* by their shape and movement (in fresh sample) and bcause they have only one nucleus (and fewer flagella). The only other trophozote that has two nuclei is *D.fragilis* but this organism has no flagella or median bodies and look likes a small amoeba.

Cyst of intestinal flagellates can be easily differentiated from those of G.lamblia because they are smaller and do not have the same characterstic appearance of G. lamblia (do not contain remains of flagella). *C.mensili* cysts are lemon shape and *D. fagilis* does not has cyst stage

Lecture :- 7 & 8

Trichomonas hominis

Habitat: Large intestine.

Life Cycle:-The trophozoite stage reproduces by binary fission and requires direct host to host transmission through contaminated food and/or drink. It has high prevalence in children and more common in warm climates.

Pathology: It is non-pathogenic but may cause diarrhoea and infection can be prevented by personal hygiene and sanitation.

Laboratory Diagnosis: Finding the trophozoite stage in fresh stool specimen.

Trichomonas vaginalis

Geographical Distribution:-World wide distribution and mainly common in the temperate region.

Habitat:-In the genital tract of male and commonly in female, especially the vagina, cervix, urinary bladder, prostate and seminal vesicles.

***Morphology*:** Has trophozoite stage only.

Life Cycle:-The trophozoite stage reproduces by longitudinal binary fission and mode of transmission is usually via sexual intercourse but also by communal bathing, sharing of washclothes, toilet equipment seats and mother to daughter during birth.

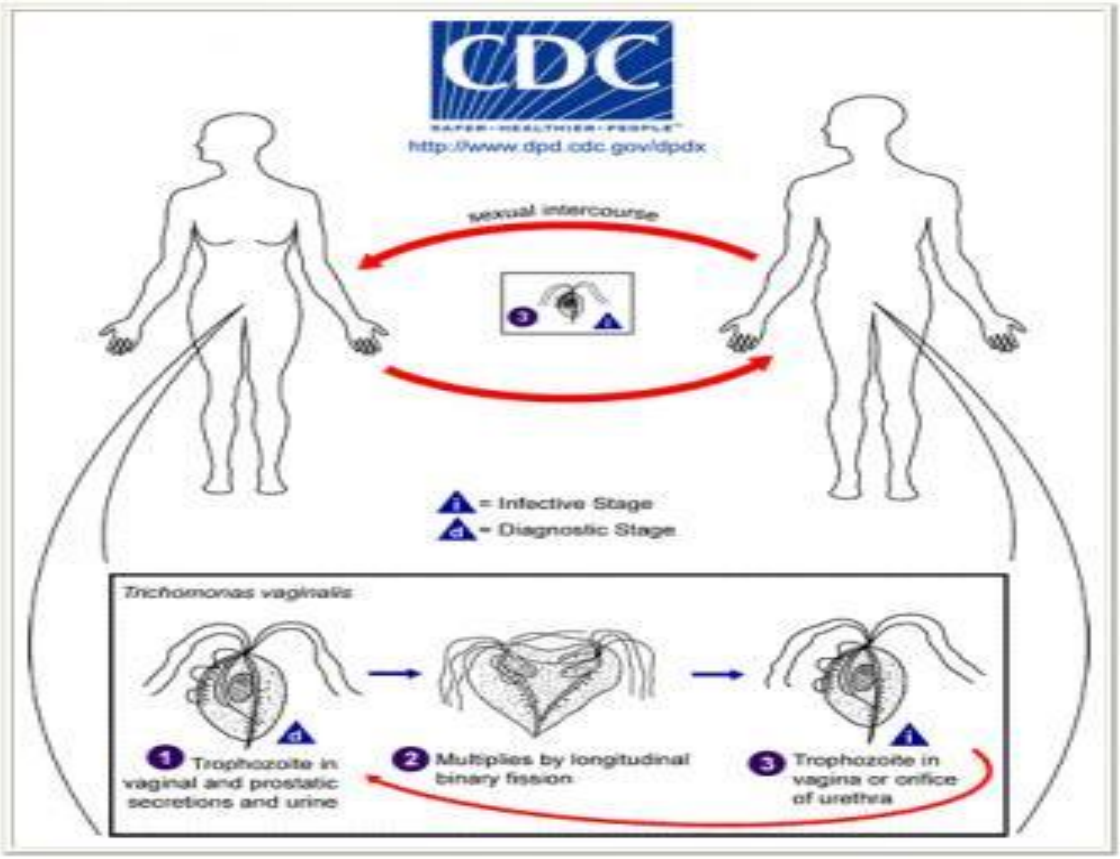

Pathology: Causes trichomoniasis. Major symptoms are Vaginitis, Urethritis ,prostatitis,chaffing of vulva,cervical erosion, burning sensation , yellowish prulent discharge, reversiable sterility in male.

Prevention and Control

1. Personal hygiene and sanitation
2. Simultaneous treatment of both partners.

Laboratory Diagnosis:-Finding the trophozoites in unstained or stained preparation of vaginal or urethral discharges, urine sediment, vaginal swab, prostate secretions

Trichomonas tenax

Geographical Distribution

World wide.distribution with high incidence in warm climates.

Habitat: oral cavity.

Morphology: Has trophozoite stage only.

Life Cycle:-The trophozoite stage reproduces by binary fission and transmission is direct from mouth to mouth through kissing or communal use of contaminated food and drinking utensils.

Pathology:-It is non-pathogenic

Laboratory Diagnosis:-Finding the trophozoites in unstained or stained smear in swab taken from the oral cavity.

Blood and Tissue Flagellates

The blood and tissue of humans may be infected by one of the several species of flagellate protozoa belonging to the family Trypomastidea. These are Genus *Leishmania* and genus *Trypanosoma*.

All of these organisms have developmental stages in blood sucking arthropodes (intermediate host) and in humans (definitive host), and may have a non human mammalian reservoir host.

General Characteristics

1. Reproduces by simple longitudinal binary fission
2. The infective stage is always the vegetative form.
3. Transmission occurs through biological insect vectors as intermediate hosts and man as definitive host
4. The species are morphologically indistinguishable, but they can be differentiated on the basis of on their clinical features primarily and also on their geographical distribution, serologic tests, cultural characteristics, vectors, reservoir hosts, biochemical tests,immunological tests, etc.
5. The different developmental forms are differentiated on the basis of
   a) Presence or absence of free flagellum

b) Presence or absence of undulating membrane

c) Position of the kinetoplast relative to the nucleus.

6. They have the following main body parts; Flagellum, Kinetoplast divided into blelopharoplast and parabasal body, axoneme, nucleus, undulating membrane,
7. Based on their development in the insect vector and their mode of transmission, Trypanosomes are grouped into two,

These are:-

I. ***Saliverian Group***.The parasites develop in the mid and fore gut of their vectors and transmitted to man by inoculation of the parasites.

II. ***Stercorarian Group.*** The parasites develop in the hind gut of their vectors and transmitted to man by the contamination bited area with the faces of their vectors.

Leishmania

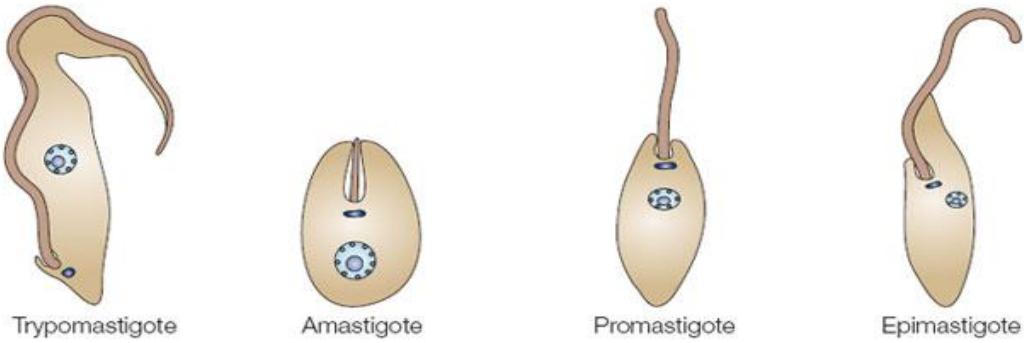

General life cycle of *Leishmania* species

Promastigotes inoculated into the skin when sandfly take a blood meal. The promastigotes are taken by macrophages and become amastigotes. Amastigotes multiply by binary fission.

Amastigotes are ingested by the insect vector when it takes a blood meal and becomes promastigote in the gut of the insect vector. The promastigotes multiply by binary fission and migrate to the head and mouth parts.

Type	Pathogen

Cutaneous leishmaniasis (localised and diffuse) infections appear as obvious skin reactions.	The most common is the *Oriental Sore* (caused by Old World species *L. major*, *L. tropica*, and *L. aethiopica*). In the New World, the most common culprits is *L. mexicana*.
Mucocutaneous leishmaniasis infections start off as a reaction at the bite, and can go by metastasis into the mucous membrane and become fatal.	*L. braziliensis*
Visceral leishmaniasis infections are often recognised by fever, swelling of the liver and spleen, and anemia. They are known by many local names, of which the most common is probably *kala azar*,[24][25]	Caused exclusively by species of the *L. donovani* complex (*L. donovani*, *L. infantum* syn. *L. chagasi*).[1]

Leishmania tropica minor

Habitat: -Amastigotes: In the endothelial cells of cutaneous tissues, lymph nodes, ulcers.

Promastigotes: In the gut of sandfly

***Morphology*:-**It has Amastigote and promastigote Stages only.

Life Cycle:- Definitive host: Man

Intermediate host: Female sandfly

Reservoir host: Dog, cats, mice, etc.

It requires a female *Phlebotomous* sandfly as a biological vector and man as its main definitive hosts to complete its life cycle.

Mode of Transmission

1. Inoculation by infected sandfly
2. Direct contact with the ulcer
3. Autoinfection

Pathology-

Causes cuaneous leishmaniasis (dry, urban, chronic, old world oriental

sore). At the site of bite there is dry painless ulcer, 25-70mm in diameter, usually self-healing after 1-2 years often leaving disfiguring scar. Multiple unhealing lesion known as leishmaniasis recidivans may develop sometimes. The infection is usually heals and confers long lasting immunity to reinfection.

Leishmania tropicam major

Similar with *Leishmania tropica minor*

Geographical Distribution:-Wider distribution than *Leishmania tropica minor* and found in rural areas of sub-Saharan Africa from Senegal to central Sudan, Middle East, India, Pakistan, central Asia, North Africa. Infections are zoonotic.

Life cycle:-Same as *Leishmania tropica minor* but man acquires infection upon invading enzootic areas because sand rat and the gerbils are also the main reservoir hosts

Clinical Feature and Pathology*:-*Causes moist (wet), rural, acute, Old world cutaneous Leishmaniasis or oriental sore. Forms a papule that develops to a large uneven ulcer or multiple lesions and is self-healing within 3-6 months. This infection protect against reinfection and against infection with *L.t.minor*. There is sporadic human infection.

***Leishmania aethiopica*:-**

Similar with the above leishmania .

Geographical distribution

Southern Yemen, and the highlands of Ethiopia and Kenya

Life Cycle:-Man acquires infection by the bite of the infected female *phlebotomus* sandflies. Infections are zoonotics with rocky hyraxes (*Procavia habessinica*) a nd tree hyraxes (*Heterohyrax brucei*) serving as reservoir hosts.

Pathology: Causes old world coetaneous and diffuse cutaneous leishmaniasis.

Prevention and Control *Leishmania* Species:

1. Avoid insect bites,
2. Control of insect vectors,
3. Protection of lesion from insect bites,
4. Avoid auto-infection /self-infection,
5. Treatment and health education.

Laboratory Diagnosis of Leishmania species:-

1. Amastigotes in stained smears taken from ulcers, lesions, nodules
2. Promastigotes in culture media.
3. Montenegroimmunologic/ leishmanin test.

Leishmania Mexican complex

Geographical Distribution:-Central and southern America mainly in the rain forest of Mexico, Brazil, Guatemala, Venezuela.

Habitat:

Amastigote: Reticulo endothelial cells of the skin promastigote: In the gut of *Lutzomyia* new world sand flies ***Morphology:*** Has amastigote and promastigote

Life Cycle:-Same as the life cycle of Leishmania tropica except that the vectors are new world sand flies

Pathology:-Causes new world coetaneous leishmaniasis.

Leishmania braziliensis complex

Geographical Distribution:-Tropical forests of South America and Central America. Reservoir hosts are rodents and some domestic animals

Habitat: Amastigote:- In the reticulo-endothelial cells of muco-cutaneous tissues of nose, mouth, lips, larynx.

Promastigote:- In the gut of *Lutzomyia* sandfeies

Morphology: Has amastigote and promastigote stages.

Life cycle:-*Lutzomyia* sandfeies are the main vectors and man acquires infection from enzootic area.

Pathology:-Mucocutaneous leishmaniasis (espundia). Chronic ulceration of mucus membrane of the mouth nose, throat, etc. with destruction of bone and cartilage. *Leishmani*

a Mexican complex and *Leishmania braziliensis complex* have similar prevention and control methods and laboratory diagnosis as presented below:

Prevention and Control

1. Avoid endemic areas
2. Avoid insect bites
3. Treatment of infected individuals
4. Health education

Laboratory Diagnosis

1. Amastigotes in stained smears taken from infected ulcers, lesions,

sores and nodules

2. Promastigotes from culture media.
3. Immunologic tests

Leishmania donovani

Geographical Distribution: India, Central Asia, China, Kenya, Sudan, Ethiopia, Somalia, Central and South America.

***Habitat :-Amastigotes*:** In the reticulo-endothelial cells of the visceral organs such as spleen , bone marrow , Lymph node , liver, kidney, lung, brain, CSF, whit blood cells , intestine, etc.

***Promastigotes*:** In the gut of *phlebotomus* in the old world and Lytzomyia in the new world

Morphology: Has both amastigote and promastigotes stages.

Life Cycle: Reservoir hosts are rodents, dogs, fox, jackals.

Promastigotes are inoculated in to the subcutaneous tissues and taken up by macrophages. They become amastigotes and multiply. Large mononuclear cell invaded and the parasites are carried through the blood circulation to the visceral organs. When the sandfly takes a blood meal, these amastigotes are ingested into the gut of the insect vector and becomes promastigotes then they multiply. The parasites can be also **transmitted through blood transfusion, sexual contact or congenitally**.

Pathology: Visceral leishmaniasis or kala -azar. Major symptoms are fever, chills, sweating, cough, diarrhoea, vomiting, bleeding gums, weight loss,splenomegally, hepatomegally, lemphadenopathy, hypopigmentation of skin.

Prevention and Control

1. Personal protection from sandfly bites by using repellants, avoiding endemic areas especially when sandflies are active,
2. Insecticide spraying of houses and farm buildings
3. Destruction of stray dogs in area where dogs are reservoir hosts.
4. Treating infected person and health education

Laboratory Diagnosis

1. Amastigotes in aspirates of spleen bone marrow, enlarged lymph nodes, and in peripheral blood monocytes.
2. Promastigotes in culture media
3. Testing serum for leishmanial antibodies
4. Formal get test; is a non-specific screening test for marked increases

in IgG.

Lecture :- 9

Trypanosoma

Geographical Distribution: West and western central Africa, extending from Senegal across to Sudan and down to Angola.

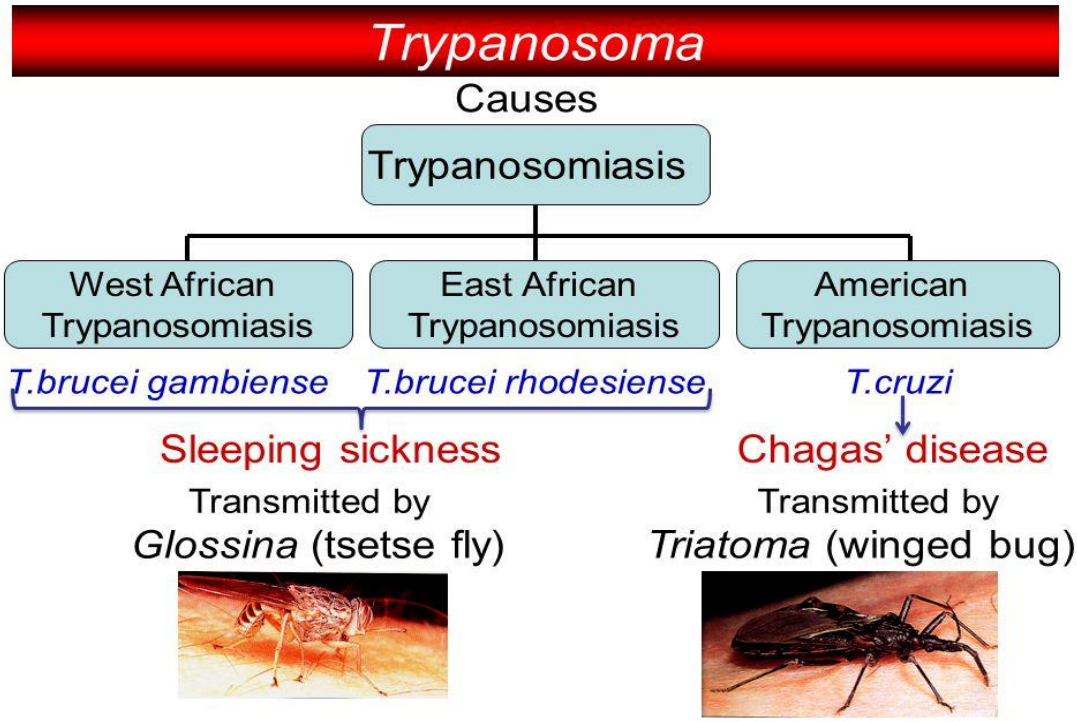

<u>Trypanosoma brucei complex (group)</u>

Trypanosoma brucei rhodesiense (causing acute trypanosomiasis) and *T.b. gambiense* (causing chronic trypanosomiasis) are morphologically indistinguishable.

Habitat:*Trypomastigotes*: In blood vessels and intercellular spaces of Lymph Nodes, spleen, liver, Brain, CSF etc.

Metacyclic trypomastigotes: In the mid and fore gut of the Glossina (tsetse flies)

Morphology: has trypomastigote and metacyclic trypomastigote stages

Life cycle*:* It requires two hosts to complete its life cycle, species of **Glossina as an intermediate host and man and other animals as a reservoir host**. It reproduces asexually by binary fission.

Trypanosoma gambiense is a saliverian trypanosome in which the trypomastigotes develop in the mid and the fore gut of the insect vector so that infection is acquired through inoculation of the metacyclic trypomastigotes into the subcutaneous tissues with the saliva. In the

blood vessels the metacyclic trypomastigots transforms into trypomastigots stage. There is multiplication of the parasites in the mammalian host and the insect vectors. **The parasites can also be transmitted through blood transfusion, and congenitally**.

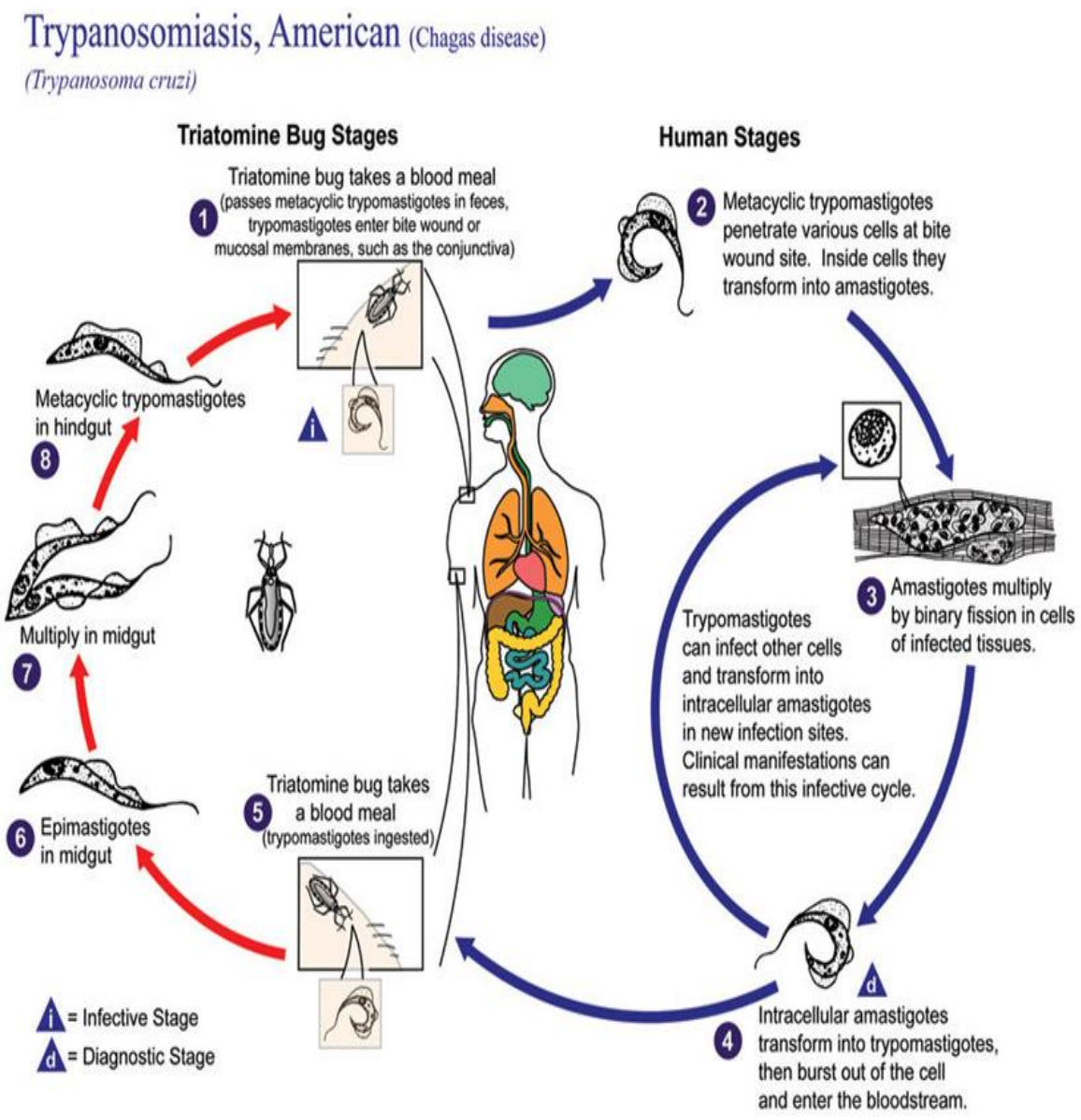

Clinical Features and Pathology: Gambian trypanosomiasis or chronic African sleeping sickness. Major symptoms are chancer, fever, haedache, sweating, post cervical enlargement of the lymph node(winter bottom's sign), splenomegally, hepatomegally, meningoencephalilis, inability to speak, progressive mental dullness, excessive sleeping, weight loss, coma and death if untreated.

Trypanosoma rhodesiense

Geographical Distribution: East Africa, Central Africa, and Southern Africa, extending from Ethiopia down to Botswana.

Habitat: *Trypomastigotes*: Mainly in the blood and CSF, also in lymphnodes, spleen, Brain etc. *Metacyclic Trypomastigote:* In the mid and fore gut of the insect vector.

Morphology: has trypomastigote and metacyclic trypomastigote stages that are morphological similar to trypomastigote and metacyclic trypomastigote stages of *T.gambiense* but posterior nucleated trypomastigote stages are common.

Life Cycle:-Similar to *T.gambiense* but the main reservoir hosts are game animals such as Antelops, Giraffe.

Pathology: Rhodesiense trypanosomiasis or acute African sleeping sickness. The major symptoms are similar to *T.gambiense* but has short incubation period and rapid loss of weight.It is a zoonosis and has low prevalence, sporadic form of infection, and more prevalent in male than in females.

Both *Trypanosoma gambiense and T.rhodesiense* have similar methods of prevention and laborarory diagnosis.

Prevention and Control

1. Vector control:
   -By spraying vehicles with insecticide as they enter and leave the tse-tse fly infested area,
   -By using and maintaining insecticide impregnated tse-tse fly traps,
   -By selectively clearing the bush and wood areas especially around game reserves, water holes, bridges, and along river blanks.
2. Detecting and treating human infections at early stage.
3. Restricting the movement of game animals to within fenced game reserves.
4. Health education.

Laboratory Diagnosis

1. Trypomastigotes in wet blood film -to observe motilit,
2. Thick or thin stained blood films or buffy coat from Micro-haematocrit or capillary tube centrifugal concentration technique.
3. Examination of aspirate from enlarged lymph gland, chancher fluid, CSF
4. Testing serum for anti-trypanosomal antibodies.

Trypanosoma cruzi

Geographical distribution: Central and South America

Habitat:

Amastigotes: Intracellular forms in the reticuloendothelial cells and tissues of brain, muscles, Lymph nodes, liver, Spleen, bone marrow, etc.

Promastigotes: Transitional stage

Epimastigotes: In the mid-gut of the insect vector (bug)

Trypomastige: In the mid-gut of the vector and; in the blood circulation and intercellular spaces of man.

Metacyclic Trypomastigote: In the mid gut and in the faeces of the insect vector

Morphology:

Has all the developmental stages of haemoflagellates

Amastigote stages are similar to amastigote stages of *Leishmania* species. The Trypomastigote are monomorphic forms about 2□m in size with "C" or "U" shape.

Mode of Transmission of T. cruzi

1. Contact with the faeces of an infected blood sucking triatoma bug.
2. Blood transfusion.
3. Less commonly trans-placental transmission occurs with a fetus being infected from an asymptomatic mothers.
5. It can occur also if viable parasites (even very few) penetrate the skin, conjuctiva, or mucous membrane.

Life Cycle

In most infections, metacyclic (infective) trypomastigote contained in the faeces of an infected bug (Triatoma) penetrate the skin through the bite wound or enter through the conjunctiva of the eye or the membrane of the mouth or nose. The feace are deposited as the bug feeds or soon after. The trypomastgotes invade the reticuloendothelial cells near the point of entry and multiply intracellularly as amastigotes. The amastigotes develop into Trypomastigotes which are released into the blood when the cell ruptures. The trypomastigote become amastigotes and multiply, forming masses known as Pseudocysts.

Within the pseudocyst, a proportion of amastigote become elongateed

and develop first into epimastigotes and then into trypomastigotes which ar released into the blood when the host cell ruptures. Some of these trypomastigites continue to circulate while the majority infect further tissue cells.By way of the blood and lymphatic system, the parasites reach tissue cells of the heart, nerve, skeletal muscle, smooth muscles of the gastrointestinal tract and else where. The life cycle is continued when a triatomine bug vector ingests circulating Trypomastigotes in a blood meal. In the vector, the Trypomastigotes transform in to epimastigotes which multiply by binary fission in the gut of the vector .Finally metacyclic trypomastigotes are formed in the hind gut of the bug.

Pathology*:* Causes chaga's disease.

Prevention and Control*:* Vector control, improvement of housing, treatment and health education.

Laboratory Diagnosis*:-*

1. Blood film -wet film for motility
   -thin and / or thick stained blood films
2. Xenodiagnosis (in chronic and subacute infections where their number in the blood is usually very few).
   Xenodiagnosis in this method uninfected, susceptible, laboratory reared triatomine bugs are starved for 2 weeks and then fed on the patients' blood. If trypanosomes are ingested they will multiply and develop into epimastigotes which can be found 25-30 days later in the faeces or rectum of the bug
3. Culture of blood on blood agar slopes in the later stages of infection when facilities for xenodiagnosis is not available.
4. Serological diagnosis to detect anti- *T.cruzi* antibodies

Lecture :- 10

Class Ciliatae (Ciliates)

Balantidium coil

Geographical Distribution: World wide being more commonly found amongst those who keep pigs, and uses pig faeces as fertilizer vespecially in warmer climates. In Ethiopia it was reported from Debre Brahne.

Habitat: Trophozoite and cyst in the large intestine of pig and rarely

man.

Life Cycle

As soon as the thick wall cysts are excreted in the feces, they infective. Man acquires infection from contaminated food or drink or from hands contaminated with faeces. Following ingestion, the cyst excyst in the intestine producing trophozoites; where each cyst producing a single trophozoite. The ciliate multiply in the colon by simple binnary division often following conjugation. Conjugation takes place by a process, when the two trophozoite are found to be in state of union and enclosed in a cyst, with the exchange of nuclear material.Pig is the main reservoir host.

Pathogenicity*:-*

It is the only ciliate that parasitize humans. Causes balantidial dysentery .Infection with B.coli can be without Symptoms unless the ciliates invade the intestinal wall . Invasion can cause infammation and ulceration, leading to dysentry with blood and mucus being passed with faeces.

Prevention and Control:-

1. Avoid contamination of food or drink.
2. Improving personal hygiene especially those who keep pigs.
3. Treatment and health education.

Laboratory Diagnosis:-Finding the tropozoites in dysenteric faecal specimens and the cysts in formed or semiformed faeces.

- In dysenteric specimens the ciliate usually contain ingested red cells.

Class Telosporidea

The members of the subphylum sporozoa do not possess any organells of the locomotion like flagella or cilia, but they show change of from by sluggish amoeboid movement. They reproduce asexually by a process of sporulation called schizogony, alternating with sexual reproduction by union or syngamy called sporogony.

Coccidiidea:-These are intestinal sprozoa. In these case, the maturation oocyst occurs outside the body in the passed faeces or in the soil and infection takes place in the susceptible host by contamination through the oral route. The coccidiidea has the family Eimeriidae which has two genera: *Eimearia* and *Isospora*.

Haemosporiidea are parasite of blood and blood forming organs. They have sexual and asexual union in this case takes place in an insect, the definitive host, and the infection takes place in man or other vertebrates by the bite of an insect vector, usually a mosquito. The suborder Haemosporiidea contains three families: Babasiidae, Haemoproteidae and Plasmociidae.

General Life Cycle

Sporozoites⟶Trophozoites⟶Schizontes⟶Merozoites⟶ Gametocytes⟶Gametes⟶Zygote⟶Ookinet⟶Oocyst (Sporoblasts⟶Sporocysts).

Intestinal and Tissue Coccidian Parasites

Isospora belli

Geographical Distribution*:* Widely distributed in the tropical and subtropical countries

Habitat*:* The epithelial cells/villi of the small intestine.

Life Cycle

I.belli complete its life cycle in a single host. The infective stage is the mature oocyst containing sporozoites and following ingestion, with contaminated food or drink the parasites excyst and the sporozoites enter epithelial cells of the small intestine where they develop and multiply by schizogony (merogony). Merozoite infect new cells . Some merozoite form male and female gametes. Fertilization⟶ Zygotes. Zygotes⟶Oocyst. Oocysts are excreted in the faeces. Feces containing oocyst contaminate water supply, food, etc. The oocysts are immature when passed with the faeces and maturation(sporogonic reproduction) is completed in the external environment. Sporozoites are produced in oocyst by sporogony.

Pathology*:* Infection *I. belli* in the immunocompetent is generally associated with no disease or self limiting gastroenteritis, but in some cases the symptoms may be protracted with diarrhea, loss of weight or low grade fever. But in immunocompromized such as AIDS patient it is responsible for *significant chronic diarrheal disease.

Prevention and Control:

Infection can be prevented by sanitation of food and drink, and Personal hygiene.

Laboratory Diagnosis:

Finding *I.belli* oocyst in the faeces

Usually only immature oocysts are found in the faeces but occasionally mature oocysts can be seen. In about 50% of infected patients Charcot Leyden crystalare are found in the faeces.

Cryptosporidium Parvum

Geographical Distribution: world wide

Habitat:- Just under the surface membrane/with in the brush-border/of the epithelial cells of the villi of the small intestine

Morphology:

Oocyst: size: 4-5□m

Shape: spherical Contents four elongated naked sporozoites, no sporocyst stage. It is infective when passed in feces.

Life Cycle:

Has similar life cycle to *I. belli* and man acquires infection From contaminated hand , food or drink Its life cycle is similar with the life cycle of *I.bell i*. It will also infects a wide range of domestic animals and wild life .

Pathology*:* It is an important cause of diarrheal disease in young children . In persons with abnormal immune respo+nse,fatal diarrheal disease cryptosporidiosis . Autoinfection can occur with infective oocyst sporulating in the intestine.

Prevention and Control:

1. Sanitation of food and drink
2. Personal hygiene
3. Latrine construction.
4. Treatment of infected individuals and reservoir hosts

Laboratory Diagnosis: Finding the oocysts in watery and non-offensive stool sample prepared:

1) With modified Ziehl-Neelsen or safranin-methylene blue staining technique following Sheather's flotation or formol-ether concentration.
2) With acridine orange staining if fluorescent microscopic is available
3) Serological technique using ELISA

Lecture :- 11

Toxoplasma gondii

Geographical Distribution: world wide

Habitat:-In the reticulo-endothelial cells of heart, lymph nodes, lung, spleen, bone marrow, mononuclear leukocytes, brain, CSF, spleen, etc of man, domestic and wild animals.

Morphology: -There are five main developmental forms in the life cycle but only trophozoite (toxoplasm) and cyst stages are found in man but all stages occur in the felines (cats).

Toxoplasm (trophozoite):-Two forms

I. **Tachyzoite/endozoite:-**occurs in the early acute stage of infection.
   Size: 3□m by 7 □m Shape: crescent or oval in shaped, one end is rounded and the other end is pointed content: In Giemsa stain, paranuclear body- stains red, nucleus stains dark red and cytoplasm stains blue.
   Quickly multiplying forms that form pseudocyst (aggregation of a parasites inside a macrophage)

II. **Bradyzoites/cryptozoites:-**Occurs in the chronic stage of infection, develops slowly and multiplies in the tissues to form a true cyst.

Cyst:-10-100□m and may contain about 3,000 trophozoites

Life Cycle:

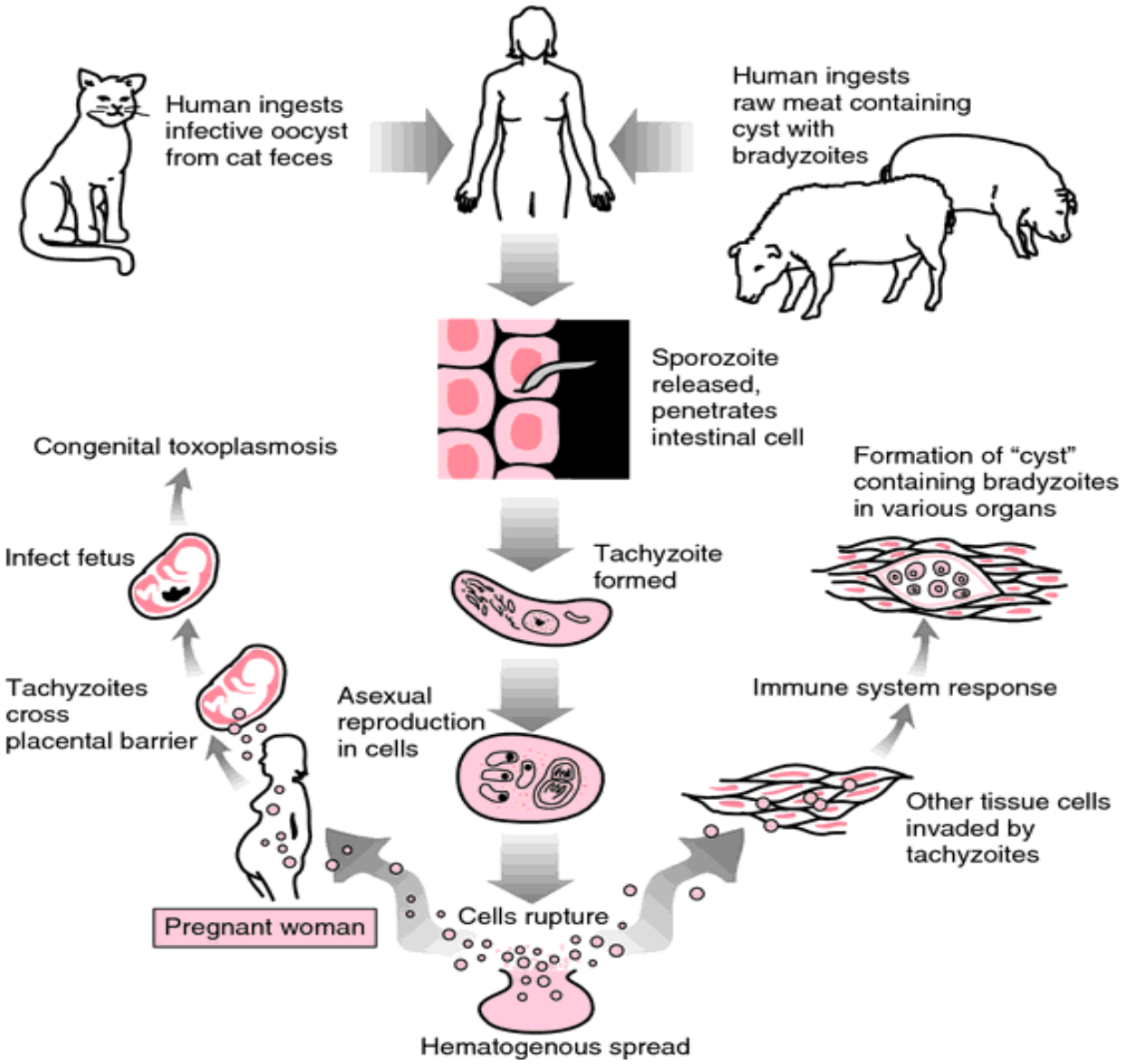

Definitive host: Cat and Lynx

Intermidiate host: Man and other animals

The life cycle can be either heteroxenous (requiring two hosts) or monoxenous (one host). Both sexual and asexual reproduction occurs in cat but only sexual reproduction occurs in man. Mode of multiplication can be endodyogony (repeated division in to two by internal budding), ectomerogony (division in to several organisms simultaneously by external budding), and endopolygony (division into several organisms simultaneously by internal budding.

Mode of Transmission

1. Ingestion of oocysts in food, drink, or hand contaminated with faeces of an infected cat.
2. Blood transfusion,
3. Transplacental/congenital

4. Ingestion of cysts in raw or under cooked meat
5. Organ transplantation

Pathology*:* Causes toxoplasmosis

Major symptoms: fever, headache, splenomegally, lymphadenopathy, hydrocephales abortion, still birth. CNS toxoplasmosis is quite common in HIV/AIDS patient with clinical presentation of hemiparesis and/ or loss of consciousness.

Prevention and Control:

1. Avoid contamination of hand, food and water with the faeces of cat
2. Not eating raw or under cooked meat such as pork, mutton, beef
3. Screening of blood and organ of individuals for the parasites
4. Treatment and health education

Laboratory Diagnosis

1. Identifying toxplasms in Giemsa stained histological sections, aspirates of lymphnode, bone-marrow, CSF, pleural fluid, peritoneal fluids and sputum.
2. Serologic tests such as Sabin-feldman dye test, ELISA, IFAT, CFT.

There has to be differenital diagnosis of toxoplasms from amastigote stages of *Leishmania species* and *T.cruzi.*

Lecture :- 12 & 13

Haemosporidia (The Malaria Parasites)

Malaria is the most important of all protozoan disease; it annually infects over 250 million individuals and is a leading cause of illness and death in the developing world. In many endemic areas it is becoming increasingly difficult to control because of *Anopheline* mosquito vector and the parasite to develope resistance to various eradication and treatment options.

General Characteristics

1. Intracellular obligate parasites.
2. Man is intermediate host.
3. Female Anopheles mosquitoes are the definitive hosts.
4. Those species which infect human being are *P.vivax, P.falciparum, P.malariae* and *P.ovale*
5. Has no animal reservoir host except *P.malariae* in which monkeys

are the reservoir hosts

6. Infective stage to man from the insect vector is sporozoites and to the insect vector from man is gametocytes.

Geographical Distribution

Malaria is endemic in 91 countries with about 40% of the world population is at risk. *Plasmodium falciparum* is the most prevalent species in the hotter and more humid regions of the world. *P.vivax* is the most widely distributed in the temperate, subtropics and some parts of the tropics. Unlike the other species, it is more common and well adapted to the temperate region than in the tropics.

P.malariae has much lower prevalence than *P.vivax, P.falciparum* and *P.ovale*. It is confined mainly to tropical Africa. Also it is found in South America and South west Asia. Infection rates in Ethiopia are about 60%, 40%, 1% and less than 1% for *P.falciparum, P.vivax, P.malariae* and *P.ovale*, respectively.

Habitat:

The parasite enters the blood and carried to the parenchyma cells of liver, where they multiply enormously. This is called the pre-erythrocytic or tissue phase. By rupture of the infected cells they enter the RBCs, the erythrocytic phase (Schizogony) and reach all the organs of the blood via the circulating blood, producing parasitaemia.

General Life Cycle of Malaria parasites:

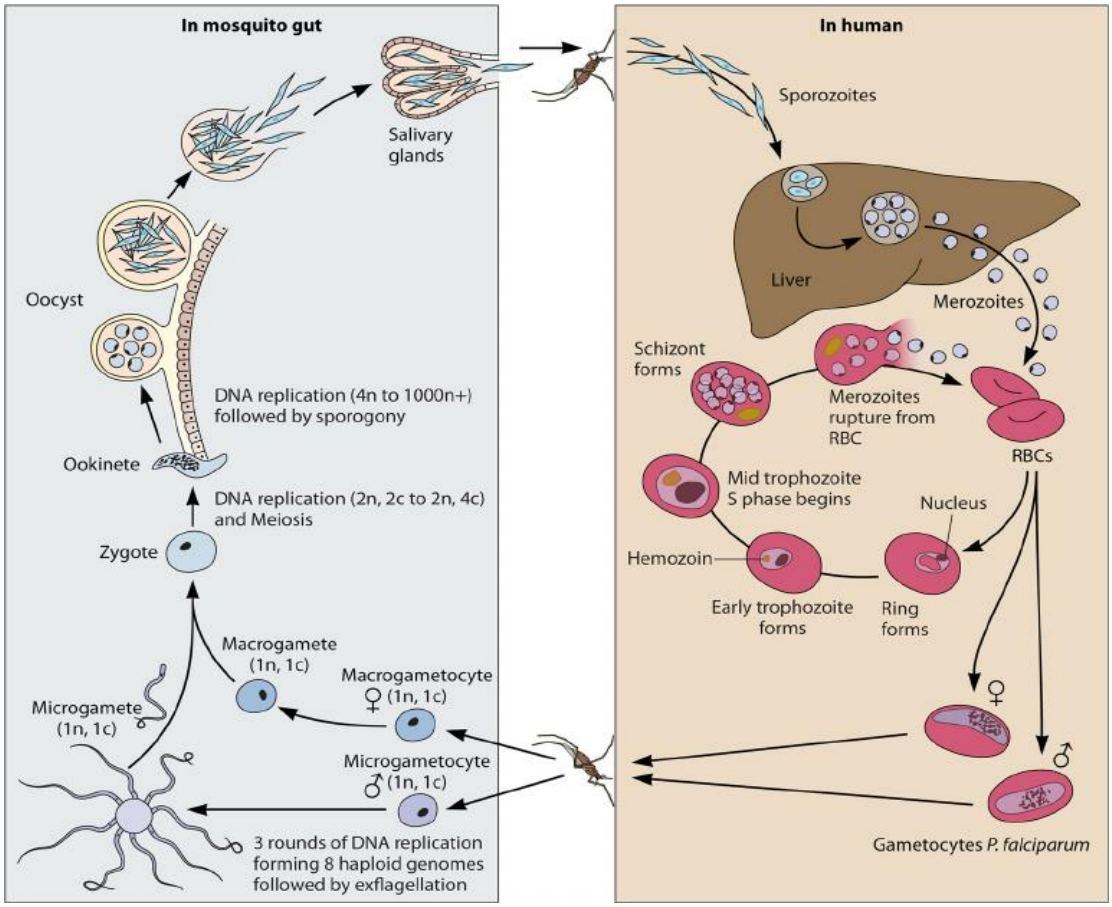

-Malaria parasites require two hosts to complete their life cycle. Female Anopheles mosquitoes as the definitive host, where sexual reproduction (sporogony) takes place and human being as the intermediate host, where the asexual reproduction (schizogony) takes place.

- Sporozoites from infected female Anopheles mosquito are injected with the saliva into the blood circulation of man when the vector takes a blood meal. After circulating in the blood stream for not more than one hour, the sporozoites enter into the liver cells.
- Two cycles occur in man, in the liver as exo-erythrocytic schizogonic reproduction and in the red blood cells as erythrocytic schizogolnic reproduction. In the liver the parasites multiply and develop into schizonts. When mature the schizont, the liver cell rupture releasing large number of merozoites. The merozoites enter the red blood cells and develop to trophozoite stage. The trophozoite feeds on haemoglobin and forms malaria pigment (haemozoin). The trophozoite stage develops into schizontes.

- In the schizont nuclear division takes place to produce large number of merozoites that are released from the schizont to invades new red blood cells. After several erythrocytic schizogonic reproductions, the merozoites develop into gametocytes.
- To continue the life cycle, the gametocytes are ingested by a female Anopheles mosquito while taking a blood meal. In the stomach of the mosquito, the male and female gametocytes under go fertilization and produces a zygote. the zygote develops into a motile ookinete which penetrates the stomach wall of the mosquito to form an oocyst. Inside the oocyst large numbers of sporozoites are formed. The oocyst ruptures releasing the sporozoites that also enter into the salivary gland to be transmitted to another individual when the insect takes a blood meal.
- Recrudescence (due to small number of erythrocytic parasites remaining in the blood after a previous attack) occurs in *Plasmodium falciparum* and P*lasmodium malariae* over a long period of malariae infection.
- Relapse due to hypnozoite (dormant forms which precede schizont development in the liver occur in vivax malaria and less commonly in Ovale malaria.

Modes of Transmissions

1) Bite of infected female Anopheles mosquitoes. The main vectors in Ethiopia are *A.gambiae, A.funestus, A.nili, A. arebiansis* and *A.pharonensis*
2) Blood transfusion causes only erytrocytic infection.
3) Contaminated syringes and needles
4) Congenital / transplacental

Clinical Feature

Malaria pathogenicity is mainly releated to P. vivax causes Benign Tertian malaria and now called vivax malaria.

P.malariae causes Quartan malaria and nopw called malariae malaria.

P.falciparum causes malignant Tertian or subtertian malaria.

P. ovale causes Benign Tertian malaria.

Major symptom is malaria fever usually that occurs in three stages:

1. Cold stage: Rigor, headache, coldness and shivering
2. Fever stage: rise in temperature, up to 40.6^0c, severe headache, back and joint pain, vomiting, diarrhea
3. Sweating stage: perspiration, temperature falls, headache and pain relived until the next rigor.

The malaria fever is due to the rupture of the infected red blood cells containing mature schizonte stage releasing malaria pigment, toxins, metabolic by products, debris of red blood cells and merozoites that can infect other red blood cells

Factors That Provide Protection against Malaria Infections are:

1) Glucose-6-phosphate dehydrogenase deficiency , Scickle cell anemia Ovalocytosis and Adenosine tri-phosphate deficiency in non-immune black males provides protection against *P.falciparum* infection
2) Thalassemia, Duffy blood group antigens (i.e., Fy^a and Fy^b) negative RBCs and Hemoglobin E provides protection against *P.vivax* infection.
3) Human fetal hemoglobin gives protection against all forms of malaria infection

Prevention and Control

Prevention and control of malaria become difficult as a result of resistance of the parasites to the drugs and failure of control measures. Besides this population movement, climatic changes and economic problems are also considered currently as factors that related with malaria spread. However, the following are some of the measures to be taken as prevention and control measures;

1) Avoid mosquito bites by
   - Selecting healthy sites for houses and screening windows and doors with mosquito net.
   - Using mosquito bed nets
   - Wearing protective clothes such as long trouthers
   - Using mosquito repellents
2) Destroy adult mosquitoes by
   - Indoor residual regular effective spraying

3) Preventing breeding of mosquitoes by
   - Altering the habitat to discourage breeding
   - Flooding or flushing of breeding places
   - Drainage to remove surface water, filling in ponds, pot holes, etc.
   - Spraying breeding places with effective chemicals particularly with larvicides
4) Using drugs to
   - Prompt diagnosis and treatment of malaria cases
   - Prevent infections using chemoprophilaxis, especially in non-immune persons visiting or going to malarious areas or in persons with reduced immunity such as pregnant women.
5) Health education.
6) Blood screening for malaria before providing for those who need blood.

Laboratory Diagnosis

1) Malaria parasites are detected in thin or thick blood films stained by wright's stain, Giemsa stain, leishman stain or Field stain. Take blood films when the patient feels febrile because the parasites are usually most numerous in the blood towards the end of an attack of fever. Always collect the blood before anti-malarial drugs are taken.

   Field stain is recommended for smears stained straight away and Giemsa stain for smears to be stained after a few days.
2) Using a rapid immunodiagnostic tests such as ParaSight F, ICT malaria Pf / Pv and, OptiMALr. These are recently discovered groupof techniques, which proved tobe valuable and highly sensitive

and specific tests. All of themdepend on the "dipstick" format and they are termed collectively as"rapid test for malaria.

- The principleof these test kits depends on detection of P.falciparum Histidine Richprotien-2 antigen (Pf HRP-2)which is only produced by P.falciparum or by detection of Plasmodial Lactate Dehydrogenase enzyme(LDH) isoenzymes produced by both *P.falciparum* and *P.vivax*.
- Detection of PfHRP-2 can not differentiate between dead and live parasites, this antigen canpersist in the serum for months after parasitological clearance of the disease. On the other hand, identification of specific LDH verifies live parasite only and inturn it appears more specific fordiagnosisof active infection.

3) ELISA

4) PCR

Lecture :- 14 & 15

Helminths (Worms)

Platyhelminths :- Class Cestoda (Tape worms)

General characteristics:

1. Dorso-venterally flattened (leaf or tape-like)
2. Bilaterally symmetrical.

3. Have nervous system. The digestive

system may be absent, or when present it is rudimentary and without anus

It obtains its nutrient by absorption through the cuticle.

4. Tape worms are hermaphrodites
5. Each unit of the Chain (segements) is known proglottides

. The entire Chain of proglottids is called strobila

6. The body is divided into three main body regions; this are

Head (scolex): attachment organ and may have grooves, suckers, and rostellum armed with hooks.

Neck: growth region, proglottids proliferates from this region.

Strobila: varies in number, shape, size, and maturity. It is divided into Three regions:

A/ immature: sex organs are immature.

b/ mature: sex organs are fully mature.

c/ gravid : reduced or atrophied primary genital organs, uterus is filled with eggs

7. Man is;
   a. The only or main definitive host for *T.saginata, T.solium, H. nana and D.latum*
   b. Intermediate host for *E.granulosus* and *E.multilcularis*
   c. Both as definitive and intermediate host for *H.nana* and *T.solium*

Egg: - Two type

1.Operculated, immature when voided to the external environment.

2. Non-operculated ,fully embryonated when voided to the external environment.

Larvae: -Generally two type

I. Solid : eg. Procercoid, Plerocercoid, cysticercoid

II. Cystic(true bladder): can be with:- Single scolex eg. Cysticercus; Many scolexes and/or with daughter cyst eg. hydatid cyst, coenurus cyst, etc.

Taenia saginata (Beef tape worm)

Geographical Distribution

World wide distribution where cattle are raised and beef is eaten raw or under cooked. More common parasite of man unlike *Taenia solium.*

Habitat (موقع التطفل)

Adult: In small intestine of man

Larvae: In muscular tissues of cattle

Eggs: In faeces of man or in gravid segments.

Life cycle (دورة الحياة)

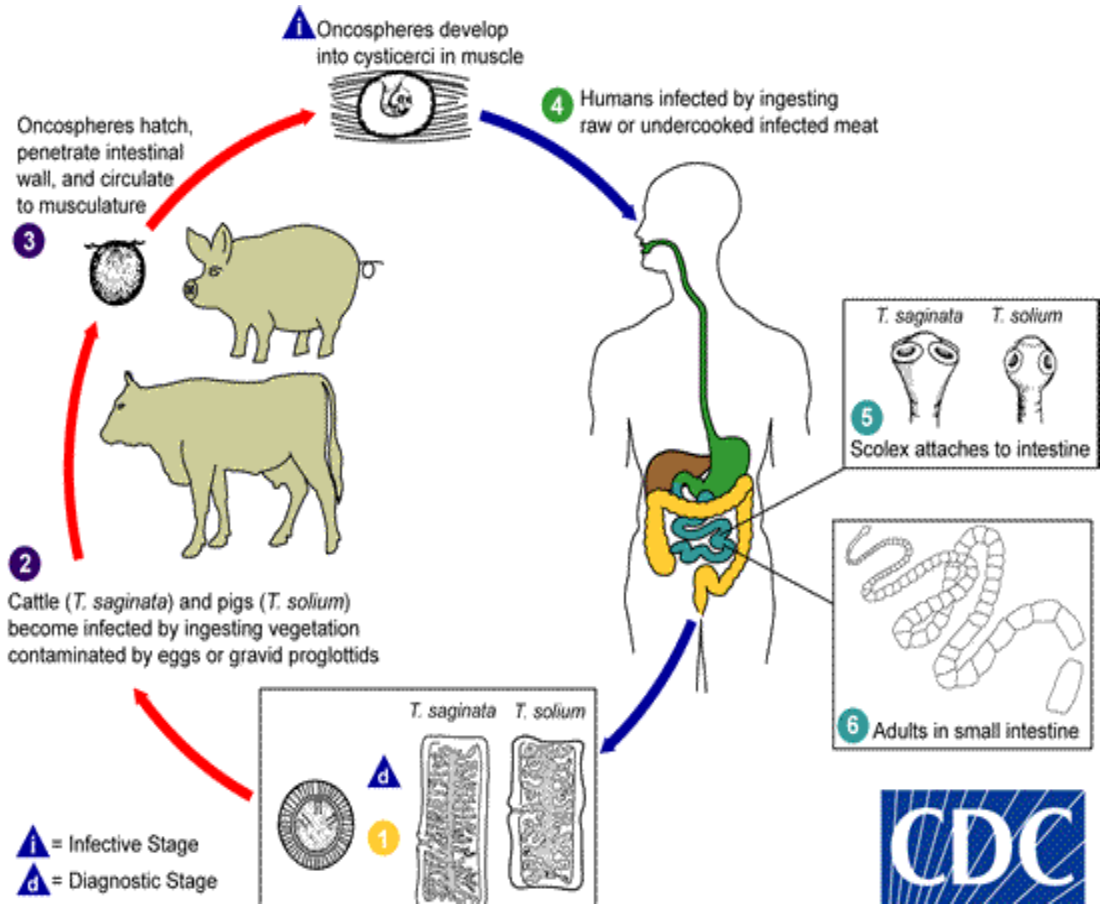

Requires two hosts to complete its life cycle. **Man as a definitive host** and **cattle as intermediate host**.

Egg(hexacanth embryo⟶larva(**Cysticercus bovis**) ⟶Adult

Man acquires infection from raw or under cooked infected meat. Following ingestion, the larvae become attached to the wall of the small intestine with its suckers. Proglottides are formed from the neck region and the larvae grow into a long adult tapeworm. When fully developed the gravid segments become detached and the eggs are discharged only after the gravid segments have been separated from the worm. Gravid segments containing eggs and eggs from ruptured segments are passed in the faeces. Cattle ingest the eggs with contaminated grass while grazing. The embryos escape from the eggs and pass through the intestinal wall into a blood vessel.Through the blood circulation they are carried to muscles and develop into infective cystic larvae called

cysticercus bovis.

Pathogenicity*:* - Causes taeniasis

Major symptoms are loss of appetite, weight loss, hunger, acute intestinal obstruction, eosinophilia, and discomfort by the crawling of segments through the anus. Proglottides of *T.saginata* have a strong tendency to crawl from the anus during the day when its host is active unlike *Entrobius vermicularis.*

Prevention and Control (السيطرة على المرض وعدم الانتقال)

1. Avoid eating raw or insufficiently cooked meat which may contain infective larvae.
2. Inspecting meat for larvae
3. Protection of cattle from grazing on faeces or sewage polluted grass.
4. Treating infected person and providing health education

Laboratory Diagnosis (التشخيص المختبري)

1. Detecting eggs in faeces. Morphologically eggs of *T.saginata* and *T. solium* are indistinguishable .
2. Identifying gravid segments and scolex recovered from clothing or passed in faeces

Taenia solium(Pork tape worm)

Geographical Distribution:-Widely distributed where human faeces reach pigs and pork is eaten raw or insufficiently cooked.

Habitat:

Adult: In the small intestine of man

Larva: In muscular tissues of pig

Egg: In the faeces of man and in gravid segment.

Life Cycle: The life cycle of *T.solium* is similar to that of *T. saginata* except **pig serving as an intermediate host** for the development of larvae known as ***Cysticercus cellulosae***.

Egg(hexacanth embryo) ⟶larva(**Cysticercus cellulosae**) ⟶Adult

Man acquires infection from eating raw or under cooked pork that develops into adult in the intestine or from contaminated food or drink

with faeces containing the eggs and develops into larval stage in visceral organs.

Mode of Transmission can be (طريقة الانتقال)

- Eating raw or under cooked pork meat
- Eggs in food or drink
- Internal auto infections

Pathology: Taeniasis and cysticercosis

Major symptoms are as a result of the adult worm. These include abdominal pain, loss of appetite, and infection with larvae cause cystic nodules in subcutaneous and muscles. If it is in the brain it causes epilepsy and other CNS disorders.

Prevention and Control:

1. Avoid eating raw or insufficiently cooked pork meat
2. Ensuring pigs do not have access to human faeces.
3. Inspecting meat for larvae
4. Treating infected person, providing health education and adequate sanitary facilities

Laboratory Diagnosis

1. Detecting eggs in the faeces which is morphologically Indistinguishable from the egg of *Taenia saginata*.
2. Identifying gravid segments and scolex in the faeces .
3. Finding calcified larvae in histological or X-rays examination .

Lecture :- 16 & 17

Echinococcus granulosus (Hydatid worm)

Geographical Distribution:-Common in sheep and cattle raising

Habitat

Adult*:* mucus membrane of small intestine of carnivores such as dog, fox,

Hydatid cyst/larvae: in the different body parts (liver, lung, brain, etc)of man and herbivorous animals.

***Egg**:* in the faece s of dog, fox, and jackals

Life Cycle:-

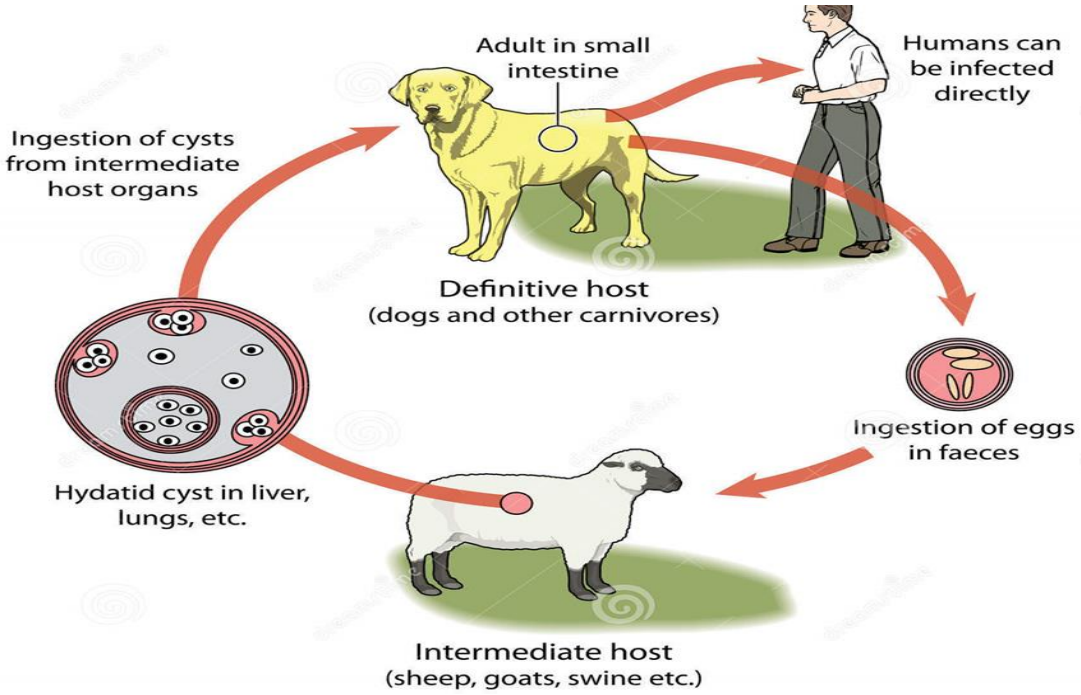

Requires two hosts to complete its life cycle. Carnivores such as dog, fox, jackles are the definitive hosts, man and herbivorous animals is intermedaitede host .

Egg (hexacanth embryo) ⟶Hydatid cyst(larvae) ⟶ Adult

Man acquires infection from ingesting eggs in contaminated food, drink and fingers. The eggs hatche in the intestine and penetrate the intestinal wall and disseminated through out the body through the blood stream and become hydatid cyst. There is no development of the parasite as adult forms in man

Mode of Transmission:

- Contaminated food, drink or finger with infected faeces of dog, fox,Jackals.
- Handling infected dogs.

Pathology:

Causes hydatid disease.Major symptoms are obstruction and pressure on vital organs,anaphylactic shock due to rupture of the cyst, Jacksonian epilepsy, jaundice, erosion and fracture of bones.

Prevention and Control:

1. Personal hygiene, washing of hands before eating
2. Avoid handling dogs
3. Avoiding eating uncooked food
4. Protection of food, and drink from contamination with faeces
5. Treatment and health education.

Laboratory Diagnosis

1. Histological examination to find larvae
2. X-ray examination to find larvae
3. Examination of cystic fluid for brood capsules and protoscoleces
4. Casoni's skin test

Hymenolepis nana (Dwarf Tape Worm)

Geographical Distribution:-

H.nana is widely distributed in countries with warm climates than in cold climates . Children are more commonly infected than adults.

Habitat:

Adult: small intestine of man, rat and mice

Cysticercoid larvae: in the intestinal villi of man, rat and mice.

Eggs: In the faeces of man, rat and mice

Life Cycle:

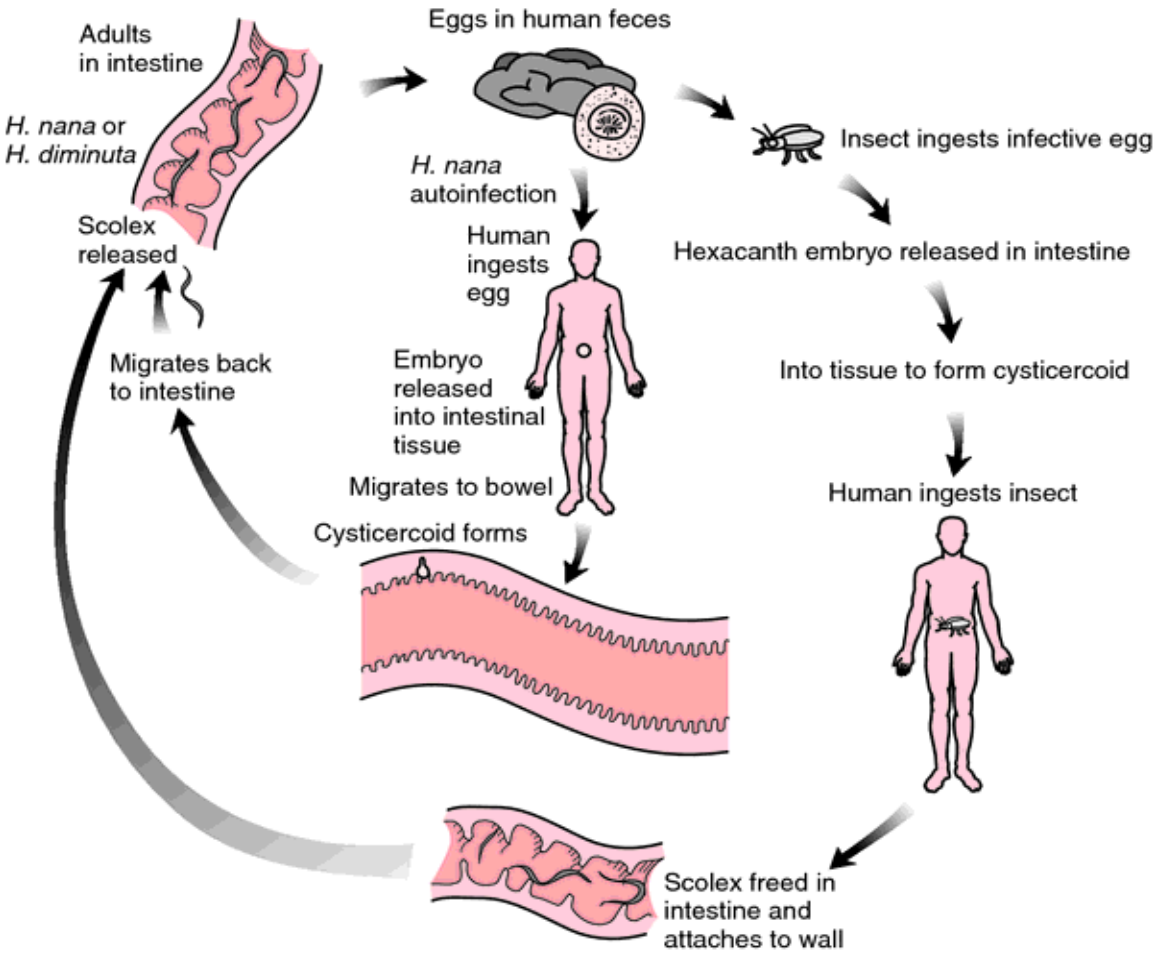

H. nana has a direct life cycle with a human host serving as both definitive and intermediate host.

Egg(hexacanth embryo) ⟶Cysticercoide larvae⟶ Adult

Eggs are the infective stages which are ingested contaminated hands,food and drink. Following the ingestion of eggs, the embryos are freed in the small intestine. They penetrate villi and develop into infective cysticercoid larvae. When fully mature, the larvae rupture out of the villi into the lumen of the intestine. They attach to the intestinal wall by their scolex and grow rapidly into mature tapeworms. Gravid segments detached and eggs are released in the intestine. Some of the eggs are passed in the faeces while others remain in the intestine to cause internal autoinfection. The eggs are infective when passed in the faeces.

Mode of Transmisssion: -

1. Ingestion of egg with contaminated food, drink of finger.

2. Autoinfection.

Pathology: Although many *H.nana* tapeworms can be found in the same host due to internal autoinfection, the life span of the adult worm is only a few month. Symptoms of infection are rarely detected except in children when many tapeworms may cause abdominal pain, diarrhoea, anorexia and lassitude. Toxins released from the worms can cause allergic reactions.

Prevention and Control:

1. Personal hygiene, washing of hands before eating and after defecation
2. Sanitary disposal of faeces into latrines
3. Avoiding eating uncooked food
4. Protection of food, and drink from contamination with faeces
5. Treatment and health educations.

Laboratory Diagnosis

1. Usually eggs of the parasite in the faeces.
2. Some times adult worms in the faeces

Hymenolepis diminuta (Rat tape worm)

Geographical Distribution: Cosmopolitan with sporadic human infection in the world.

Habitat:

Adult: Ileum of rat, mice and rarely man

Larva: body cavity of insects (fleas and cockroaches)

Egg: In the faeces of rat, mice and man

Life Cycle:

Requires two hosts to complete its life cycle. Intermediate hosts are fleas, beetles, cockroaches. Definitive hosts are rat, mice and man.

Egg(hexacanth embryo) ⟶Cysticercoide larvae⟶Adult

Eggs in the faeces of the definitive hosts are ingested by the insect

vectors and hatches releasing the oncosphere. The oncosphere migrate into the body cavity and develop into cysticercoid larva. Man acquires infection by accidentally ingesting the infected insect vector.

Pathology: Causes hymenolopiasis and major symptoms are abdominal pain, diarrhoea, restlessness.

Prevention and Control

1. Avoid insect vectors
2. Avoid their reservoir hosts
3. Protection of food and drink from insect vectors
4. Health education

Laboratory Diagnosis

1. Eggs in the faeces

Lecture :- 18 & 19

Dipylidium caninum (Dog Tapeworm)

Habitat:Adult: mucus membrane of small intestine of carnivores :dog, Cat, Man

Cysticercoid larvae: In the body cavity of insects Egg: in the faces of dog, cat, man

Life Cycle: -

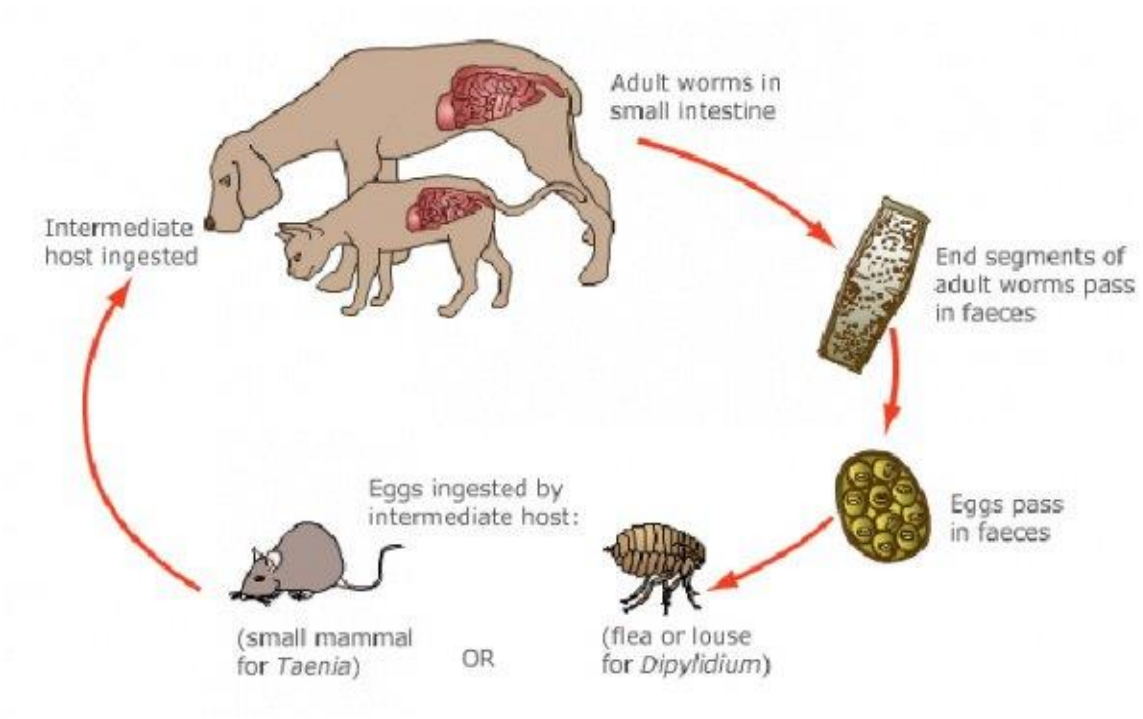

Requires two hosts to complete its life cycle. Carnivores such as dog, fox, and occasionally man are the definitive hosts, and fleas and other insects are intermediate host.

Pathology: Causes dipylidiasis

Laboratory Diagnosis:-Finding gravid segments and eggs in the feces

Diphyllobothrium latum (Fish tapeworm)

Habitat *Adult:* small intestine of man, cat, dogs, pig

Eggs: passed in the feces of man

Larval forms: Coracidium: free in water

Procercoid: body cavity of copepod / Cyclopes

Plerocercoid (sparganum) larvae: in the flesh of fresh water

Fish such as pike, perch, salmon, eel, barbel, ruff, trout

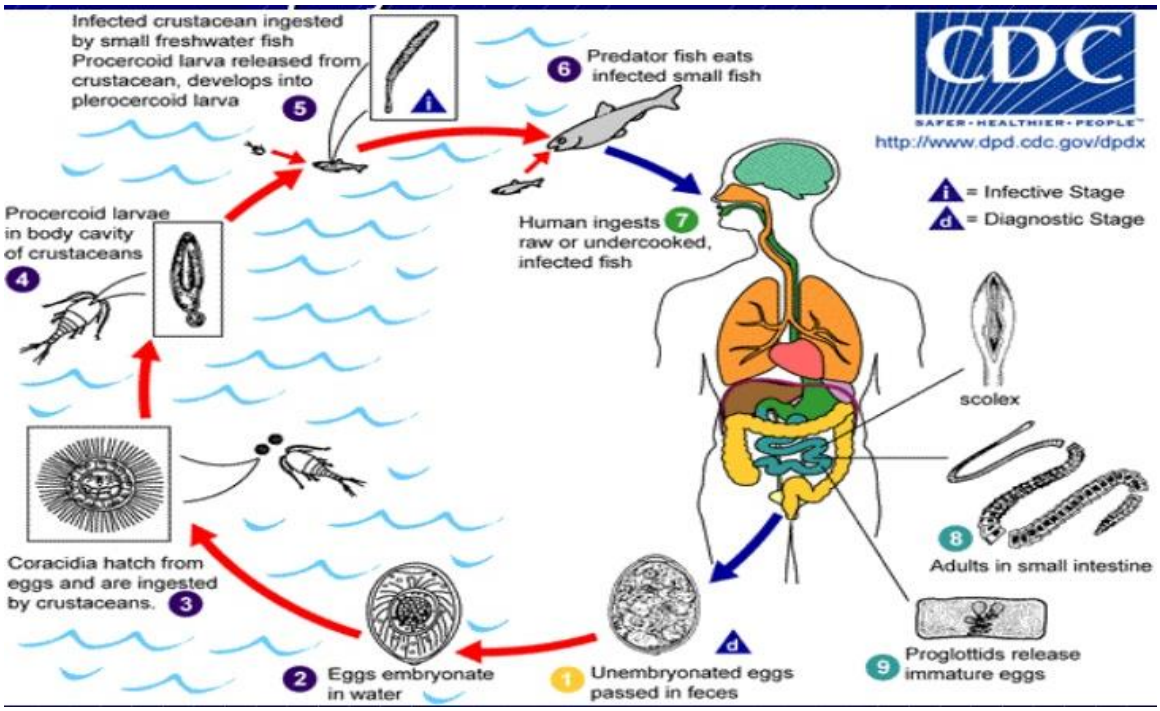

Life Cycle: - *D.latum* requires three hosts to complete its life cycle.

Definitive hosts: man dog, pig

Intermediate hosts: - Primary Intermediate hosts: Crustacean

- Secondary Intermediate hosts: Fresh water fish

Man acquires infection by eating raw or inadequately cooked fresh water fish.

Pathology: Competes for vitamin b 12 and cause megaloblastic anemia.

Major symptoms are abdominal pain, diarrhea, constipation, loss of weight, intestinal obstruction, pernicious anemia and eosinophilia.

Prevention and Control:

1. Avoid eating raw or undercooked fish
2. Proper disposal of feces
3. Fish inspection for larvae
4. Treatment of infected individuals and health education.

Laboratory Diagnosis

1. Eggs in the feces
2. Scolex in the feces
3. Adult worms in the feces

Class Trematoda (Flukes)

General Characteristics

1. Attached to their host by of suckers.
2. The digestive system consists of a mouth and an esophagus which divides to form two intestinal caeca.
3. For the development, eggs must reach water.
4. Adult flukes live in the bile duct (liver flukes) intestinal tract (intestinal flukes), portal veins (blood flukes) and lung (lung flukes) according to species.
5. Reproductive structure is similar to the tapeworm's .Sexes are separate in

Schistosoma

Blood Flukes (*Schistosomes*)

Schistosoma mansoni *(Manson's blood fluke)*

Habitat *Adult:* In the mesenteric venous (haemorroidal) plexuses draining the large intestine (colon and rectum)

Larvae: In fresh water snails.

Egg: In the faeces, and rarely in the urine of man.

Cercariae:- In fresh water, Infective to man

Life Cycle: Requires two hosts to complete if life cycle, man as a definitive host and species of fresh water snails known as Biomphilaria as an intermediate hosts.

Embryonated egg⟶Miracidium⟶Sporocyst⟶cercariae⟶ schistosomulum⟶ Adult

Pathology ***Causes*** Intestinal schistosomiasis / bilharziasis/.

They may be irritation and a skin rash at the site of cercarial penetration (swimmer's itch). The majority of *S.mansoni* eggs penetrate the intestinal wall and are excreted in the faeces sometimes with blood and mucus. Host reaction to eggs lodged in the intestinal mucosa leads to the formation of granulomata, ulceration, thickening of the bowel wall.

A portion of the eggs reach the liver through the portal vein. In the liver , reaction to the eggs may eventually cause thickening of the portal vessels known as claypipe-stem fibrolysis.

Prevention and Control (General for all Schistosome species)

1. Avoid contact with water known to contain cercariae.
2. Safe water supply
3. Construction of bridges on streams and rivers
4. Providing safe recreational bathing and swimming sites
5. Avoid contamina tion of water with the faeces of man
6. Latrine construction and sanitary disposal of faeces and urine
7. Destroying snail hosts and their breeding sites
9. Treatment of infected individuals and giving health education.

Laboratory Diagnosis

1. Finding the eggs in faeces by direct examination or more commonly by using concentration; occasionally eggs may also be found in urine often following faecal contamination. Mucus and blood are often present in the faecal specimen
2. Examining a rectal biopsy for eggs when they cannot be found in faeces.
3. Immunodiagnosis using ELISA, RIA, Latex `agglutination are helpful particularly in prepatent period, and in chronic and ectopic cases in which eggs are difficult to be demonstrated in the faeces. These assays detect circulating antibodies in the serum.

Schistosoma japonicum (Oriental blood fluke)

Geographical Distribution: China, Philippines , Indonesia, Japan, Thailand, Philippine.

Habitat:

Adult: superior mesenteric portal veins of the small intestine of man

Eggs: In the faeces

Larvae: In amphibious snail hosts.

Cercariae: free swimming in fresh water; Infective stage

Life Cycle

Embryonated egg→Miracidium→Sporocyst→cercariae→ schistosomulum→ Adult

It is similar to the life cycle of other schistosomes with the exception of that after mating they migrate to the superior mesenteric veins in the wall of the small intestine and the intermediate hosts are species of Oncomelania.

The clinical feature and pathology It is known as Katayama reaction of S.japonicum infection are similar to,
but more often more severe, than those of S.mansoni infection. As the eggs are smaller than both S.mansoni and S.haematobium, they are readily conveyed in the portal system to the liver; in which in many cases becomes cirrhotic causing portal hypertension and enlargement of the spleen.

Prevention and control: Similar to the prevention and control methods of other Schistosomes

Laboratory Diagnosis

1. Eggs in the faeces, the feaces is usually mucoid and bloody
2. Eggs from rectal biopsy.

Schistosoma haematobium (Urinary schistosomiasis)

Common Name - Vesical blood fluke or Urinary schistosomiasis

Adult: In the vesical pelvic venous plexuses surrounding the urinary bladder, prostate, seminal vesicle and lower thirds of uterus.

Eggs: In the urine, rarely in faeces

Larval stages: Fresh water snails

Cercariae: Free swimming in fresh water, Infective stage.

Life cycle: Embryonated egg⟶Miracidium⟶Sporocyst⟶cercariae⟶ schistosomulum⟶ Adult

The life cycle of *S. haematobium* is similar to the life cycle of *S.mansoni* with a few exceptions following mating; the paired flukes migrate via the inferior mesenteric veins into the vesical venous surrounding the bladder. The fresh water snail hosts are species of *Bulinus*. The main intermediate hosts are *B.truncatus, B.africanus and B.abyssinicus.* The

latter is known to transmit in Ethiopia.

Clinical Features and Pathology

Causes Vesical or urinary schistosomiasis /bilharziasis.

1. Cercarial dermatitis (Swimmers itch) within 24hrs of infection an intense irritation & skin rash, may occur at the site of cercarial penetration.
2. Migration-assage of cercaria in the lungs leads to minute hemorrhages & pneumonia
3. Ovipositor & tissue reaction
   - Some eggs trapped in the tissue bladder results hematuria

About 20% of the egg remain inside the tissue of the bladder & this egg finally die & calcified giving rise to the so called sandy patch, appearance

4. In heavy infections eggs can be carried to other parts of the body
5. Following prolonged untreated infection
   - The ureter may become obstructed
   - The bladder wall thickened
   - Eventually, Obstructive renal disease kidney damage

Laboratory Diagnosis:

1. Finding eggs or occasionally the hatched miracidia in urine.
   Urine contains blood and appears red or red-brown and cloudy. Eggs may not be present in the urine all the time; it is neccessary to examine urine collected over several days.
2. Less frequently detecting eggs in faeces, rectal biopsy or bladder mucosal biopsy when an infection is light.
3. Immunodiagnosis: a variety of serodiagnostic methods are currently available. These include: RIA, ELISA IHA. These methods are especially useful in diagnosis of ectopic schistosomiasis where no eggs can be detected in the urine or faeces, and cases with symptoms during the late prepatent period.

Lecture :- 20 & 21

Liver Flukes *Fasciola hepatica* (sheep liver fluke)

Laboratory Diagnosis:

1. Eggs in the faces in chronic infection
2. Eggs in aspirates & in bile if eggs are absent in stool.
3. Serological diagnosis by testing serum for antibodies is particularly valuable in the early stages of infection when the immature flukes are migrating through the liver and causing serious symptoms but not yet producing eggs.

Note: If eggs are found in human faces it must be confirmed that they are present due to a *Fasciola* infection & not from eating animal liver containing fascioliasis eggs (false fascioliasis)

False Fascioliasis - due to ingestion of animal liver containing Fasciola egg, with the passage of eggs in stool, is at time mistaken for actual infection

Rules out keep the patient on liver free diet for three days. If egg is found in repeated exam the infection is true.

Clonorchis sinesis (The Chinese Liver fluke)

Habitat: *Adult:* bile duct of man and fish eating animals including cat, dog, pig, etc.

Eggs: In the faeces

Metacercariae: under the scale of fresh water fish

Life cycle: Egg⟶miracidium⟶ sporocyst⟶Redia⟶ercariae⟶ metacercariae⟶Adult

Definitive host: man

Intermediate hosts: Primary intermediate host is *Bulimus* snail.

Secondary intermediate host is fresh water fish.

Pathology: Causes clonorchiasis

Major symptoms are diarrhea, jaundice, cirrhosis, biliary obstruction, hepatomegally

Prevention and Control

1. Avoid eating raw fish
2. Sanitary disposal of faeces and not using faeces as a night soil
3. Destroy the snails
4. Inspection of fish
5. Treating infected person and giving health education

Laboratory Diagnosis

Finding:1. Eggs in the faeces 2. Eggs in aspirates of duodenal fluids

Intestinal Flukes

Fasciolopsis buski (The giant intestinal fluke)

Habitat: *Adults:* small intestine of man , pig, dog,

Eggs: In the faeces of man Pig, dog,

Larval forms: Fresh water snails

Metacercariae: encysted on certain aquatic vegetation.

Life Cycle: - Egg⟶miracidium⟶ sporocyst⟶Redia⟶ercariae⟶ metacercariae⟶Adult

- Definitive host: Man
- Intermidate host: Segmentina species which are fresh water snails
- Man gets infection by feeding on infected water vegetation Containing metacercariae.

Pathology: Diarrhae, Ulceration and inflammation of the intestine, malabsorption, eosinophilia.

Prevention and Control

1. Avoid eating uncooked water plants which may be infected
2. Construction of latrine
3. Avoid use of human faces as a fertilizer
4. Destroy snails and their habitat
5. Treating infected individuals and giving health education

Laboratory Diagnosis

Finnding 1. Eggs in the faeces, and 2. Adult worms in the faeces occasionally.

Heterophyes heterophyes

Habitat:-Adult: In small intestine of man, cat, dog, fox

Egg : In the faeces Larval forms: In fresh water snails

Metacercariae: fresh water fish

Life Cycle: Egg⟶miracidium⟶ sporocyst⟶Redia⟶ercariae⟶ metacercariae⟶Adult

Requires three hosts to complete its life cycle.

Definitive host: Man

Intermediate host: First intermediate host: Fresh water snail such as Pirenella

Second intermediate host: Brackish water fish such as Tilapia, mullet. Man acquires infection from eating infected raw fish containing metacercariae.

Prevention and Control

1. Avoid eating raw or undercooked fish
2. Proper waste disposal of faeces in latrine
3. Avoid use of human faces as a fertilizer
4. Destroy snails and their habitat
5. Inspection of fish for metacercariae
6. Treating infected individuals and giving health education

Laboratory Diagnosis

Finding the characteristics eggs in the faeces

Lung Fluke *Paragonimus westermani* (Oriental lung fluke)

Habitat: Adults: In the lung of man

Eggs: In the sputum of man

Metacercariae: Fresh water crabs and crayfish

Life Cycle :- Require three hosts to completely its life cycle

Definitive host: Man

Intermediate host ;Primary Intermediate hosts are *Semisulcospira (Melania)* species of snails

Secondary intermediate hosts are fresh water crabs and crayfish

Egg⟶miracidium⟶ sporocyst⟶Redia⟶ercariae⟶metacercariae⟶Adult

Man gets infection by eating raw or undercooked crabs and crayfish containing metacercariae,

Pathology: Causes paragonimiasis , pulmonary distomiasis or endemic haemoptisis

Major symptoms are fever, chronic coughing, haemoptysis, diarrhea and enlargement of liver

Prevention and Control

1. Avoid eating raw or uncooked crabs and crayfish
2. Avoid contamination of water with sputum or faeces
3. Destroy snails and thweir habitat
4. Inspecting crabs and crayfish for metacercariae
5. Treating infected individuals and giving health education

Laboratory Diagnosis

1. Eggs in the sputum. The sputum is usually bloody, mucoid and rusty brown
2. Eggs in aspirates of pleural fluid and occasionally in faeces

Lecture :- 22 & 23

Class Nematoda

General Characteristics

1. Non segmented cylindrical or round worms
2. Possess a shiny cuticle which may be smooth, spined, or ridged
3. Mouth is surrounded by lips or papillae
4. Sexes are separate with the male worms being smaller than the female
5. In the male there is a testis at the distal end of a long tube which terminates in copulatory organs consisting of one or two projections called spicules

6. Copulatory bursa, caudal alae or genital papillae
7. Females are either viviparous (produce larvae) or oviparous (lay eggs)
8. Nematodes which infect humans live in the tissues or intestinal tract.
9. Tissue nematodes are transmitted mainly by insect vectors and most intestinal nematodes are feco-oral route and soil transmitted.

Intestinal Round Worms (Nematodes)

General Characteristics

1. Adult worms live in the intestinal tract
2. Female worms are oviparous (lay eggs)
3. Humans are the only or the most significant hosts
4. Most species are soil transmitted
5. Before becoming adults in their human host, the larvae of *A. lumbricoides, S. stercoralis* , and hookworms have heart lung migration.

o

Ascaris Iumbricoides (Round worm)

Habitat: Adult: In the small intestine Egg: In the faeces

Life cycle:

Egg⟶Larve⟶Adult

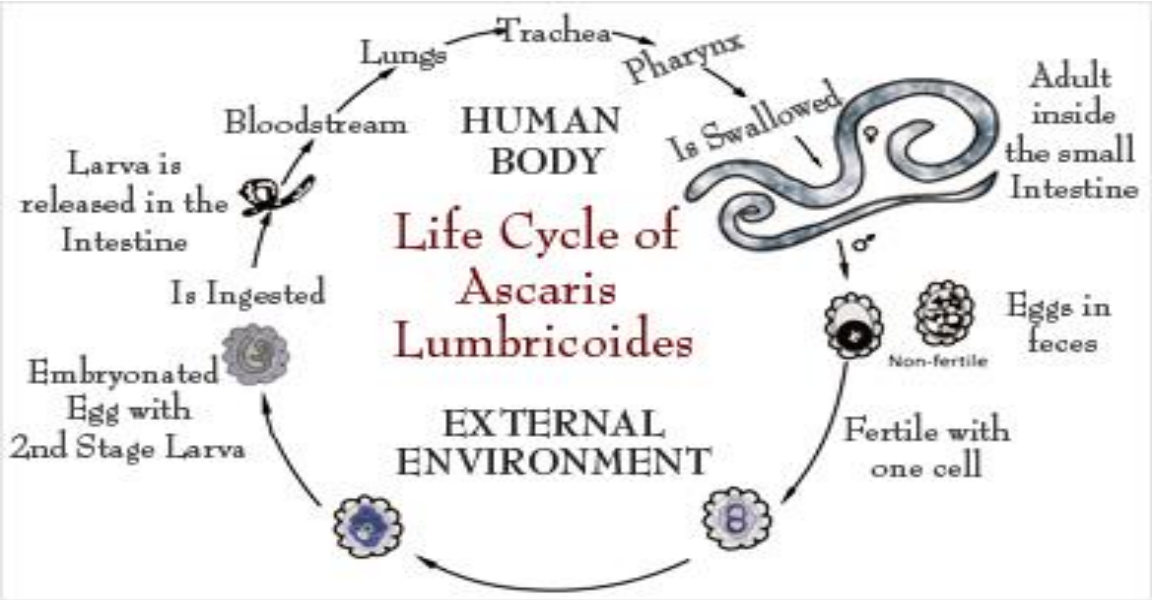

The infective stage is the egg containing second stage rhabditiform larva. Infection occurs by ingestion of the infective egg in contaminated food or drink, from contaminated hand. Following ingestion the larvae hatch in the small intestine and penetrate blood vessels in the small intestinal wall. The larvae follow a heart lung migrate from and develop. After migrating up the trachea, the larvae are swallowed. In the small intestine, they grow into mature worms.

After mating the female produces large number of eggs (200,000 eggs/day/ female) which are passed in the feces. In shaded soil. the egg develop and contain infective larva. The larva does not hatch until the egg is swallowed.

***Pathology*:** During their migration, Ascaris larva can cause inflammatory and hypersensitive reactions including pneumonia like symptoms, attacks of coughing, and bronchial asthma.

-Developing and mature worms in the intestine frequently cause pain, nausea, diarrhea and vomiting.

-Its infection in children is known to affect gastrointestinal function. Infected children are often Vitamin A deficient and have low serum albumin levels .Frequent exposure to infection may result in impairment

of physical and intellectual development.

Prevention and Control:

1. Prevent soil contamination by sanitary disposal of faeces in latrines and avoid the use of night soil as a fertilizer and washing hands before eating
2. Around eating uncooked foods such as vegetables, green salads and fruits
3. Treatment and health education.

Laboratory Diagnosis

1. Finding the eggs in faeces
2. Identifying adult worms expelled through the anus or mouth.

Entrobius vermicularis (Pin Worm***)***

Habitat:

Adult: small intestine (terminal ileum)

Gravid female: Caecum and rectum

Eggs : In faeces or deposited on perianal skin

Life Cycle

Egg⟶Larve⟶Adult

Man gets infection with egg containing infective larva from contaminated hand food or drink. Following ingestion of infective eggs, the larvae hatch in the intestine and develop into adult worms in the large intestine. After mating , the female worms migrate to the rectum. the gravid females pass out of the anus and lay their eggs on the perianal skin, with in about six hours each egg contains infective larva . Man also acquires infection from clothing , bedding, air borne eggs autoinfection or retroinfection.

***Pathology*:** Its infection rarely causes serious symptoms. There is usually intense irritation around the anus. Worms in the appendix can cause appendicitis.

Prevention and Control:

1. Treating all members of a family in witch infection has occurred.
2. Washing of the anal skin each morning soon after waking.
3. Washing of clothing worn at night.

Laboratory Diagnosis

1. Finding eggs from perianal skin using cellulose adhesive tape
2. Finding eggs in the faeces
3. Finding adult worms in the faeces.

Trichuris trichiura (The Whipworm)

Habitat

Adult: large intestine (caecum) and vermiform appendix

Eggs : In the faeces, not infective when passed

Morphology ***Adults:*** whip-like shape, anterior 3/5th of the warm resembles a whip & hence the name the posterior 2/5th are thick.

Male : Size 30-45 mm , coiled tail with a single spicule

Female*:* 35-50mm, straight thick tail.

Egg: Size: 50-54□m

Shape: barrel-shaped with a colorless protruding mucoid plug at each end Shell: fairly thick and smooth, with two layers; & bile stained

Color: yellow brown

Content: a central granular mass which is unsegmented ovum

Life Cycle

Egg⟶Larvae⟶Adult

A person becomes infected by ingesting eggs containing infective larvae from contaminated hands, food or drink. The infective eggs are ingested and the larva hatch and penetrate the villa of the small intestine. The larvae migrate to the large intestine and develop into adult worm. After mating the female worms lay eggs which are passed in the faeces. In a damp warm soil the larvae develop and each egg contains an infective larva.

Clinical features and Pathology : Light infection produces few symptoms. In young children , severe infection can cause chronic diarrhea, intestinal ulceration with blood and mucus being passed in the feces, iron deficiency anemia, failure to develop at the normal rate, weight loss and prolapse of the rectum.

Prevention and Control

1. Sanitary disposal of faeces in latrine
2. Avoid the use of night soil as a fertilizer
3. Treatment of infected individuals and health education.

Laboratory Diagnosis:-Finding the characteristic eggs in the faeces.

Lecture :- 24 & 25

Ancylomstoma duodenale **and** ***Necator americanus***

(old world hookworm) (New world hookworm)

Habitat: Adult: Jejunum and less often in the duodenum of man

Eggs: In the faeces; not infective to man

Infective larvae: free in soil and water

Life Cycle

Egg⟶Larve⟶Adult

The worms requires one host to complete their life cycle and the definitive host is man. Infection may occur in two ways: (1) through penetration of the skin and (2) ingesting filariform larvae. The larvae penetrate the skin and enter small blood vessels and following a heart-lung migration. After migrating up the trachea, the larvae are swallowed. In the small intestine they develop and mate.The worm attach to the wall of the small intestine by sucking part of the mucus and blood from the host. Female worms lay eggs which are passed in the faeces. In the external environment the egg develop and hatch the rhabditiform larvae. It feeds and moult twice to become infective larvae.

Pathology: causes hookworm infection. Major symptoms are severe

itching at the site of skin penetration known as "ground itch", mild pneumonia with cough, sore throat, bloody sputum, headache, weakness, bloody diarrhea and anemia.

Adult hookworm cause chronic blood loss. It has been estimated that a single *A.duodenale* worm ingests about 0.15ml of blood/day and a *N.americanus* worm about 0.03ml.

Prevention and control:-

1. Sanitary disposal of faeces
2. Avoid the use of night as fertilizer
3. Wearing adequate protective foot ware
4. Treatment and health education.

Laboratory Diagnosis:-Finding eggs in faeces.

Tissue Nematodes

General Features

1. Female worms are viviparous, produce live larvae but does not lay egg
2. Long tread like worms
3. The immature first stage larva of filarial worms is called a microfilariae
4. In order to complete its life cycle the larva requires an intermediate host to develop to infective form, and there is no reproduction in the insect vector
5. Diagnosis of filariasis is based of finding the microfilaria with specific morphologic features such as Size

Wuchereria bancrofti

Habitat Adults: Coiled in lymphatic glands, or lying in lymphatic vessels, superficial abscesses, or wondering in retroperitoneal tissues. Found usually in lymphatic of the lower limb.

Microfilariae: In lymphatic vessels, and in the peripheral blood normally

at night but during day in lung and other internal organs.

Infective larvae: In the gut and muscles including mouth parts of certain species of mosquitoes

Life Cycle:

Infective filariform larvae⟶Adult worm⟶microfilariae

It requires two hosts to complete its life cycle :

1) Definitive host: man
2) Intermediate hosts: species of female culex, Anopheles and Aedes mosquitoes

The infective filariform larvas are deposited on human skin when an infected female mosquito vector takes a blood meal. The larvae penetrate the skin through the bite and enter into the blood vessels and lymph nodes. Development takes place in the lymphatics and the adult worm mate to produce many microfilariae that enter the blood stream. The microfilariae are taken up by a mosquito vector when it takes a blood meal. In the stomach of the insect vector, the microfilariae lose their sheath and migrate from the mid-gut to the thorax of the vector where they develop into infective larvae and develop into infective form. The larvae are ready to be transmitted when the insect next takes a blood meal.

Pathology: Causes lymphatic filariasis or elephantiasis of usually the upper limbs, genital organs and breasts.

Major symptoms are fever with painful inflamed lymphatics, thickening and blocking of lymphatic vessels, swelling, fibrosis, elephantiasis and hydrocoele of limbs, genital organs and breasts due to obstruction of the flow of lymph.

Prevention and Control:

1. Controlling mosquitoes vector
2. Avoid mosquitoes bite
3. Treating infected person
4. Giving health education.

Laboratory Diagnosis

2. Microfilariae in aspirates of hydrocele and lymph gland fluid.
3. Occasionally Microfilariae in chylous urine or hydrocoele fluid
   In chronic banchroftian filariasis, a condition called chyluria will occur, i.e., passing of chyle in urine. In such urine microfilaria can often b found.
4. Serological diagnosis

Loa loa (Eye worm)

Habitat:

Adults: In connective tissues under the skin, in the mesentery and the parietal peritoneum. They commonly migrate rapidly in the body and may be seen in the subconjunctival tissue of the eye or in thin skinned areas.

Microfilariae: In peripheral blood of man during day time.

Infective larvae: In the gut, mouth parts and muscles of tabanide flies of the genus Chrysops.

Life cycle

Natural Definitive hosts are- Man & Monkeys. Reservoir host are simian hosts. Similar to the life cycle of *W. bancrofti* but the habitat of the adult worms is in the subcutaneous tissues and they are freely moving in these tissues. The intermediate hosts are species of chrysops(horsefly).

Pathology: Characterized by the formation of swelling known as calabar swellings. The arms most frequently affected. Adult worms also migrate in sub-conjunctiva tissues. They can cause inflammation and irritation but not blindness.

Prevention and Control: Similar with the previous filaria worms.

Laboratory Diagnosis

1. Finding the characteristic microfilariae in stained blood films taken during the day time.

2. Occasionally the microfilariae can be found in joint fluid.